



Fatty Liver Disease

Diagnostic Challenges and Updates

Ryan M. Gill, M.D., Ph.D.

Department of Pathology

University of California, San Francisco

Obesity in Antiquity

Obesity Treatment

Brisk walking

Wrestling



Definitions

- **NAFLD** – Fat ($\geq 5\%$) in the liver (imaging or histology) in a patient without secondary fat accumulation.
- **NASH**-NAFLD with histologic evidence of liver injury in the form of ballooned hepatocytes and inflammation +/- fibrosis.
- **NAFL** – NAFLD without the above histologic findings associated with NASH.

Secondary Hepatic Fat

- Macrovesicular
 - Excess alcohol
 - HCV
 - Wilson Disease
 - Starvation/TPN
 - Medications (amiodarone, methotrexate, tamoxifen, corticosteroids)
- Microvesicular

Secondary Hepatic Fat

- Macrovesicular
- Microvesicular
 - Reye Syndrome
 - Acute Fatty Liver of pregnancy
 - Medications (e.g. antiretrovirals, valproate)

Natural History

- **NASH**- Can progress to cirrhosis and liver failure (and rarely hepatocellular carcinoma)
- **NAFL** – Risk of progression to cirrhosis and liver failure is considered *minimal (with increased risk associated with NAFL with inflammation)*


Practice Guidance from the AASLD

HEPATOLOGY



PRACTICE GUIDANCE | HEPATOLOGY, VOL. 00, NO. 00, 2017

The Diagnosis and Management of Nonalcoholic Fatty Liver Disease: Practice Guidance From the American Association for the Study of Liver Diseases

Naga Chalasani,¹ Zobair Younossi ,² Joel E. Lavine,³ Michael Charlton,⁴ Kenneth Cusi,⁵ Mary Rinella,⁶ Stephen A. Harrison,⁷
Elizabeth M. Brunt,⁸ and Arun J. Sanyal⁹

Naga Chalasani, Zobair Younossi, Joel E. Lavine, Michael Charlton, Kenneth Cusi, Mary Rinella, Stephen A. Harrison, Elizabeth M. Brunt, and Arun J. Sanyal. The Diagnosis and Management of Nonalcoholic Fatty Liver Disease: Practice Guidance From the American Association for the Study of Liver Diseases. *Hepatology* 67(1), 2018

TABLE 3. Risk Factors Associated With NAFLD

Common Conditions With Established Association	Other Conditions Associated With NAFLD
Obesity	Hypothyroidism
T2DM	Obstructive sleep apnea
Dyslipidemia	Hypopituitarism
MetS*	Hypogonadism
Polycystic ovary syndrome	Pancreatoduodenal resection
	Psoriasis

*The Adult Treatment Panel III clinical definition of MetS requires the presence of three or more of the following features: (1) waist circumference greater than 102 cm in men or greater than 88 cm in women; (2) TG level 150 mg/dL or greater; (3) HDL cholesterol level less than 40 mg/dL in men and less than 50 mg/dL in women; (4) systolic blood pressure 130 mm Hg or greater or diastolic pressure 85 mm Hg or greater; and (5) fasting plasma glucose level 110 mg/dL or greater.⁽²⁸⁷⁾

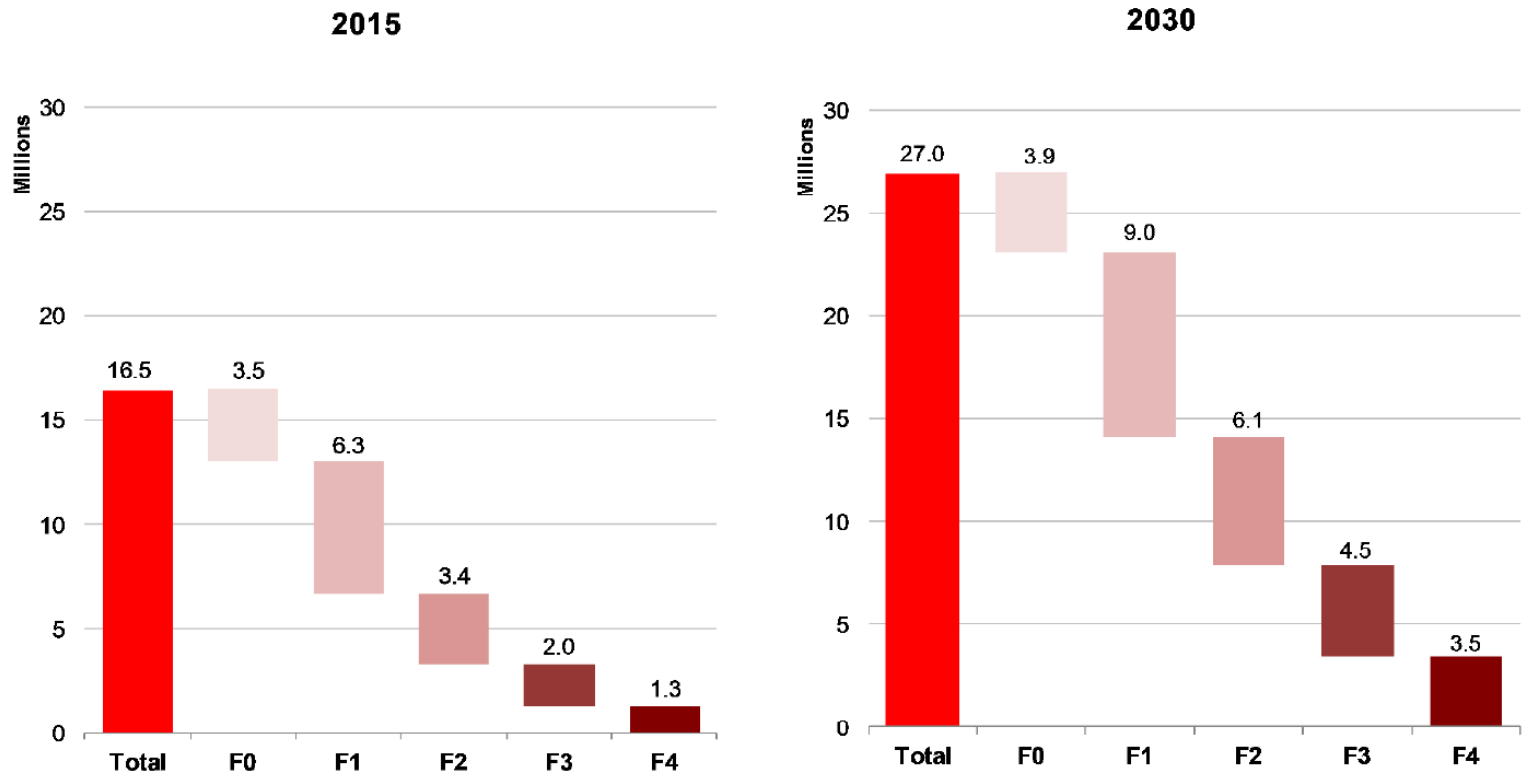
Genetic Factors

- *PNPLA3* – encodes adiponutrin. A SNP at position 148 is associated with hepatic steatosis, NASH, and increased fibrosis stage (as well as incidence of HCC)
- *TM6SF2* – a SNP at position 167 has similar associations as *PNPLA3* SNP

Scoring Systems

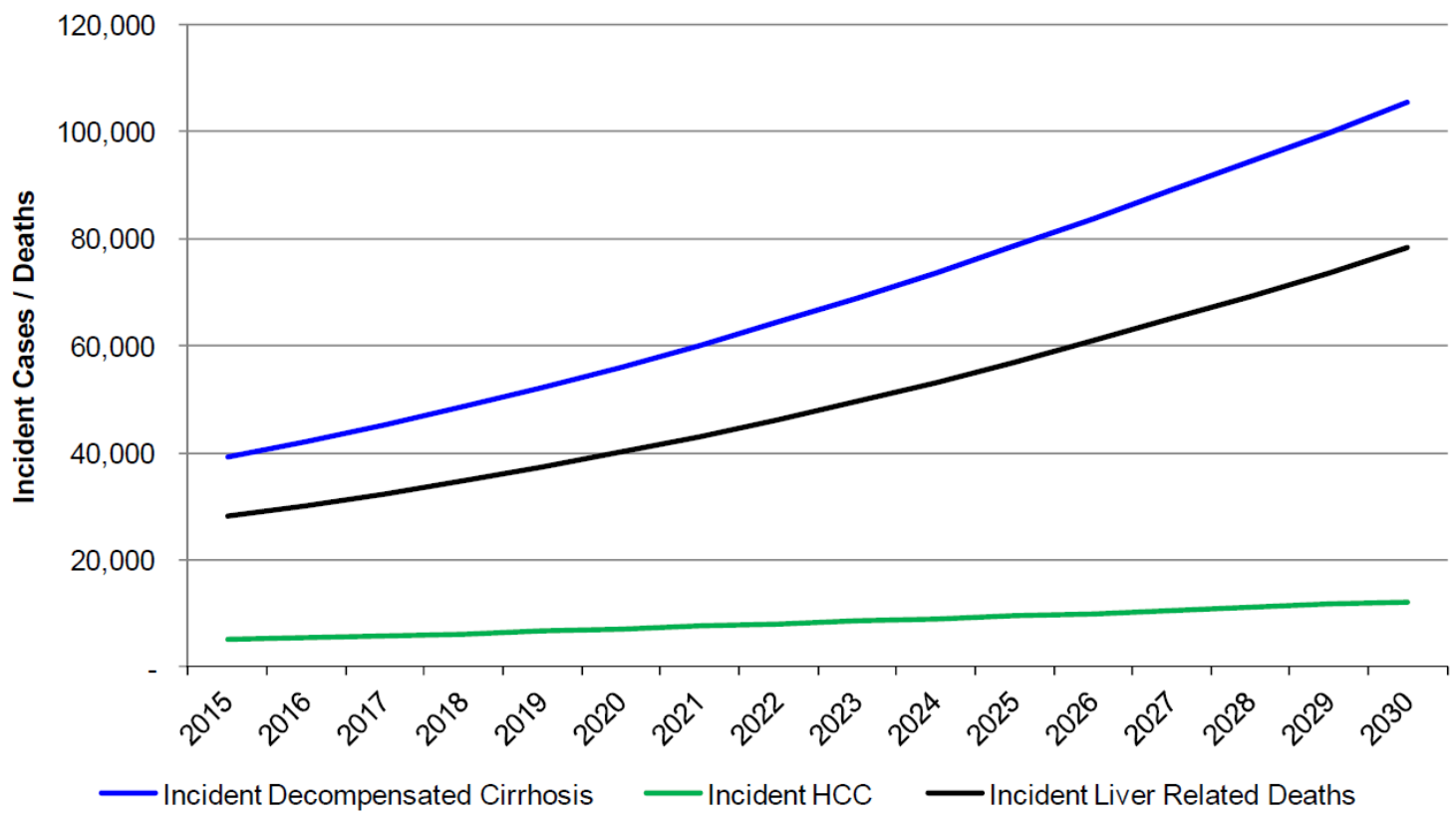
- **NAS**- Unweighted composite of steatosis, lobular inflammation, and ballooning scores. Useful to measure changes in biopsies in clinical trials. Fibrosis is scored separately
- **SAF score** – Semiquantitative score consisting of steatosis amount, activity (lobular inflammation and ballooning) and fibrosis

Figure 3b. Distribution of NASH Population by Fibrosis Stage – US, 2015 & 2030



Estes C., Razavi H., Loomba R., Younossi Z., Sanyal A.J. Modeling the epidemic of nonalcoholic fatty liver disease demonstrates an exponential increase in burden of disease. *Hepatology*, 2017 in press (10.1002/hep.29466)

Figure 5. Incident Decompensated Cirrhosis, HCC and Liver-Related Deaths among Prevalent NAFLD Population – US, 2015-2030



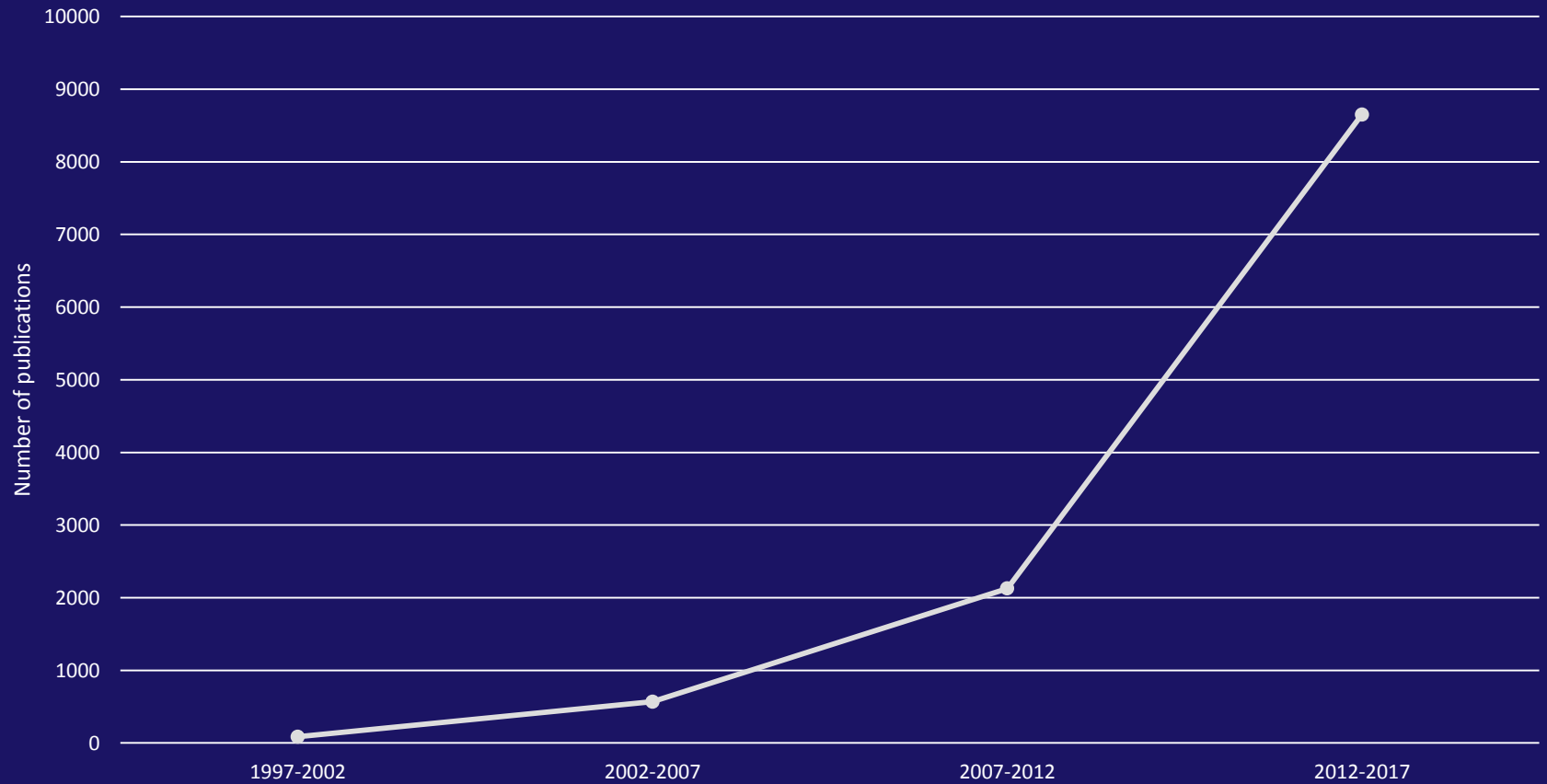
Estes C., Razavi H., Loomba R., Younossi Z., Sanyal A.J. Modeling the epidemic of nonalcoholic fatty liver disease demonstrates an exponential increase in burden of disease. *Hepatology*, 2017 in press (10.1002/hep.29466)

Conclusions

- With continued high rates of adult obesity and diabetes, in an aging population, **NAFLD related liver disease and mortality will increase in the US**
- Strategies to slow growth of NAFLD and **therapeutic options are necessary to mitigate disease burden**

Response to the Crisis

Number of Publications by Five Year Intervals, Keyword: "Non-alcoholic Steatohepatitis"



Outline

1. Essential histologic criteria for diagnosis of steatohepatitis
2. Centrizonal arteries
3. Aggressive NASH
4. Diagnostic pitfalls
5. Revisiting the NAS

Steatohepatitis: Essential Features

AASLD and NASH Clinical Research Network

- Steatosis ($\geq 5\%$)
- Inflammation (lobular)
- Hepatocellular injury

Ballooned hepatocytes

+/- Pericellular fibrosis

Steatohepatitis: Essential Features

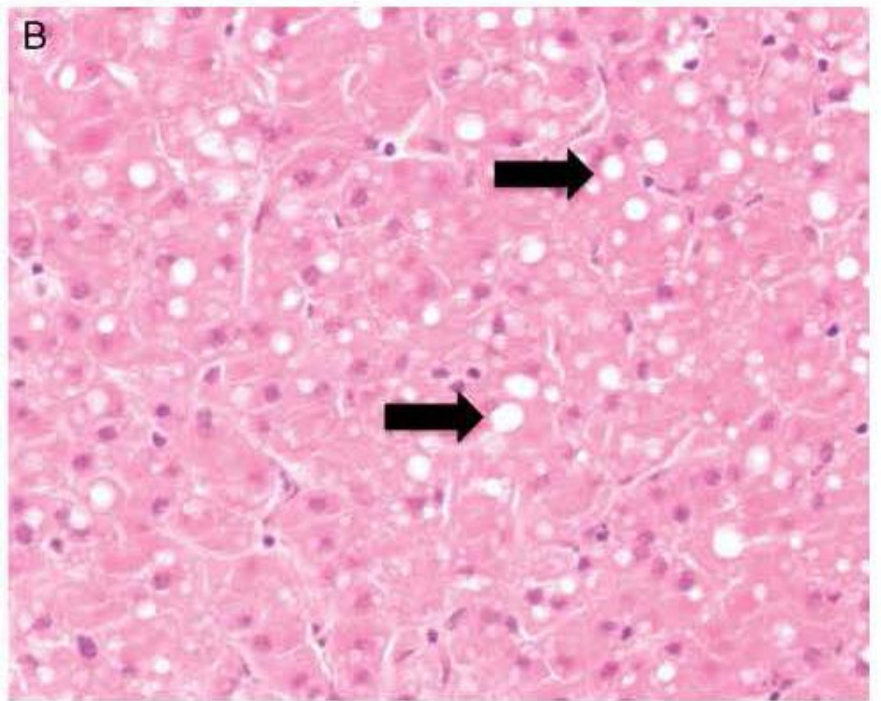
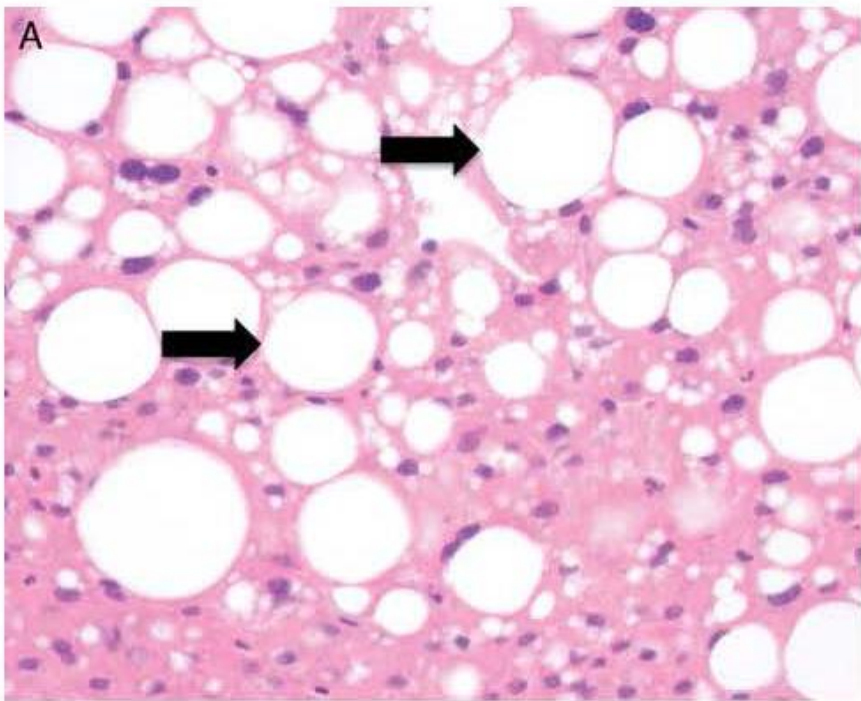
AASLD and NASH Clinical Research Network

- Steatosis ($\geq 5\%$)
- Inflammation (lobular)
- Hepatocellular injury

Ballooned hepatocytes

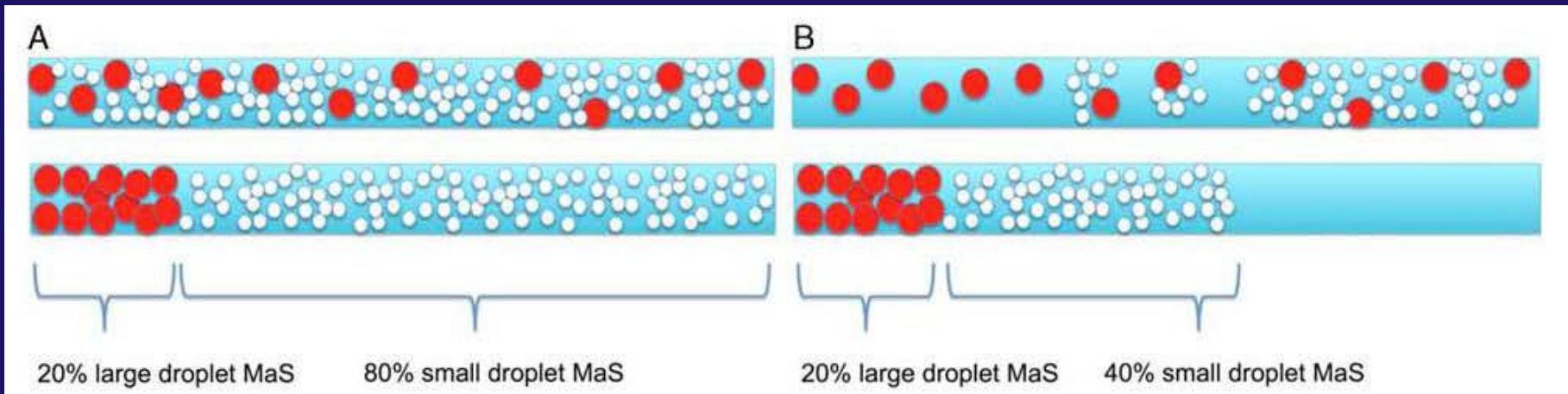
+/- Pericellular fibrosis

Large or Small Droplet Macrovesicular Steatosis



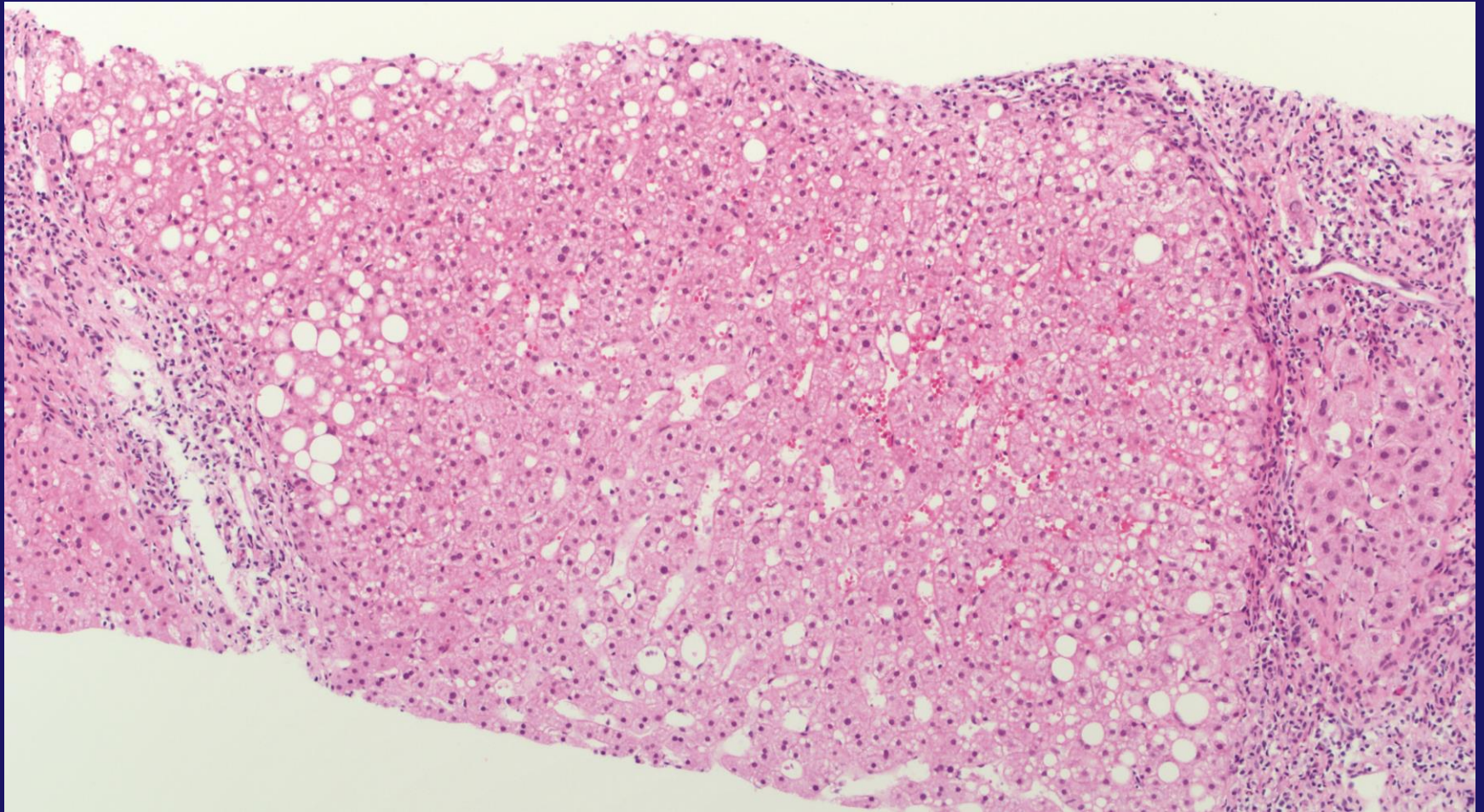
Choi WT, Jen KY, Wang D, Tavakol M, Roberts JP, Gill RM. Donor Liver Small Droplet Macrovesicular Steatosis Is Associated With Increased Risk for Recipient Allograft Rejection. *Am J Surg Pathol.* 2017 Mar;41(3):365-373. doi: 10.1097/PAS.0000000000000802. PubMed PMID: 28059835.

Estimation of Steatosis



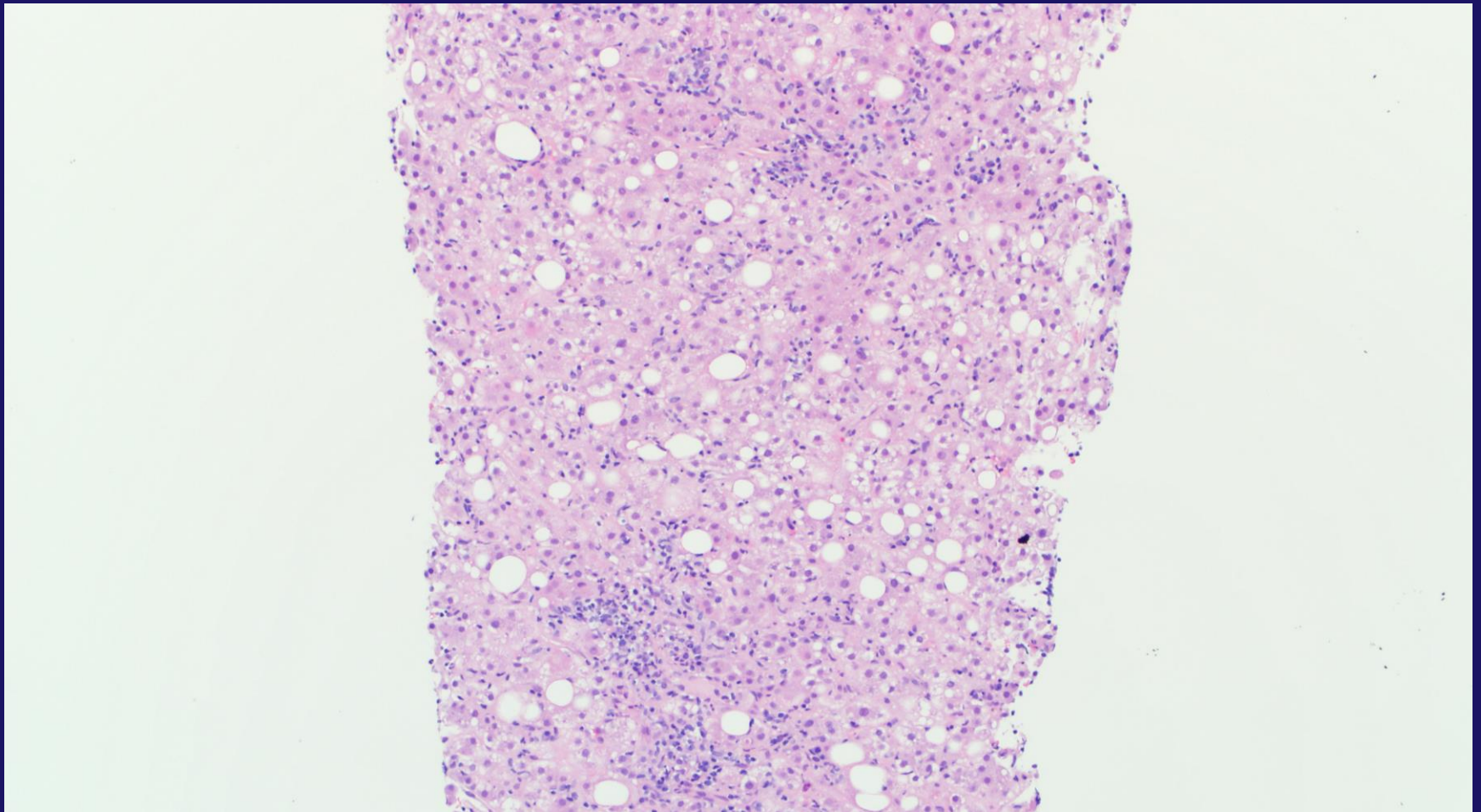
Choi WT, Jen KY, Wang D, Tavakol M, Roberts JP, Gill RM. Donor Liver Small Droplet Macrovesicular Steatosis Is Associated With Increased Risk for Recipient Allograft Rejection. *Am J Surg Pathol*. 2017 Mar;41(3):365-373. doi: 10.1097/PAS.0000000000000802. PubMed PMID: 28059835.

Mild Steatosis (Grade 1, scale 0-3)



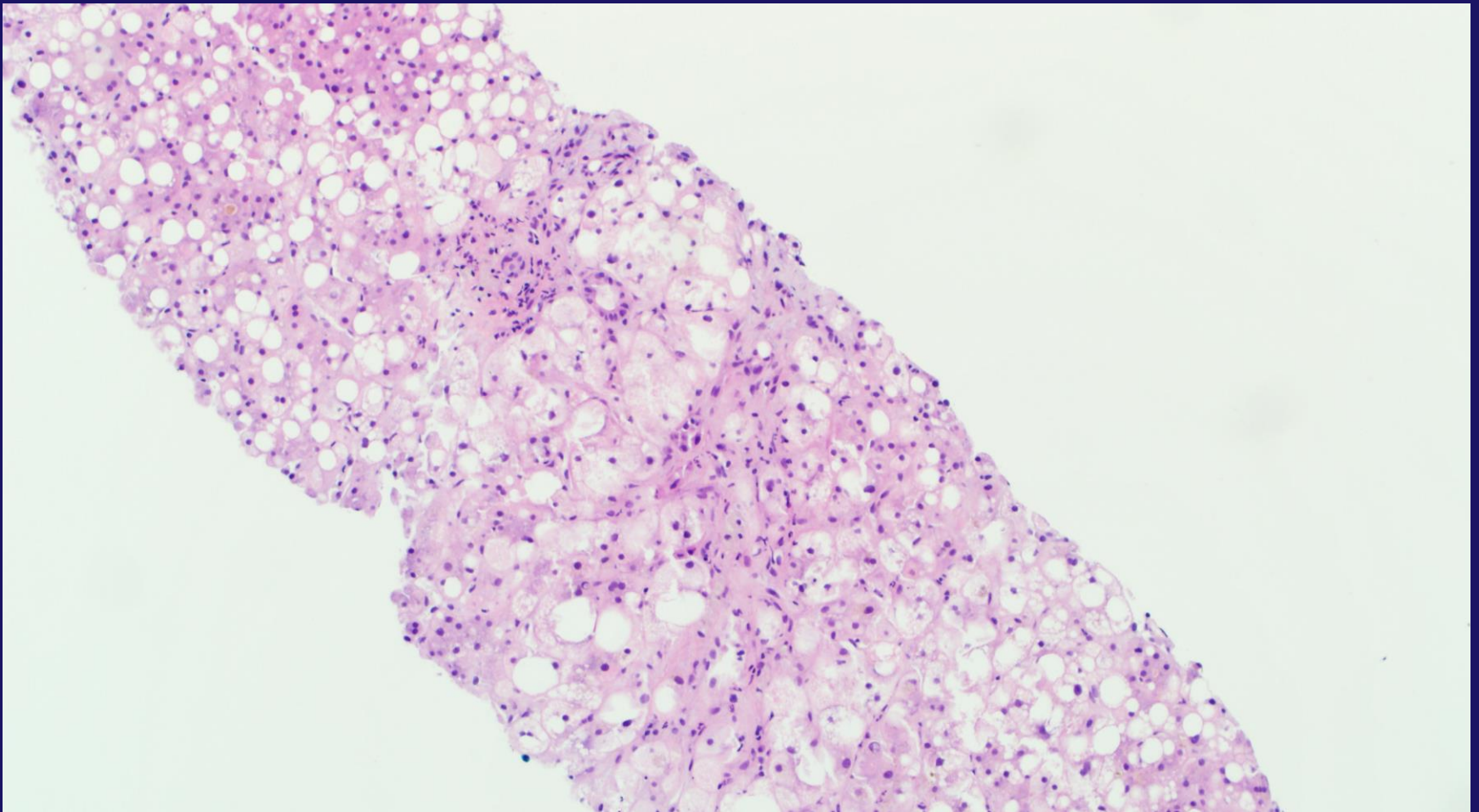
Gill R. M. and Kakar S. Non-alcoholic steatohepatitis, an update on diagnostic challenges, *Surgical Pathology Clinics*, Volume 6, Issue 2 , Pages 227-257, June 2013), adapted with permission from Elsevier.

Moderate Steatosis (Grade 2, scale 0-3)



Gill R. M. and Kakar S. Non-alcoholic steatohepatitis, an update on diagnostic challenges, *Surgical Pathology Clinics*, Volume 6, Issue 2 , Pages 227-257, June 2013), adapted with permission from Elsevier.

Severe Steatosis (Grade 3, scale 0-3)



Gill R. M. and Kakar S. Non-alcoholic steatohepatitis, an update on diagnostic challenges, *Surgical Pathology Clinics*, Volume 6, Issue 2 , Pages 227-257, June 2013), adapted with permission from Elsevier.

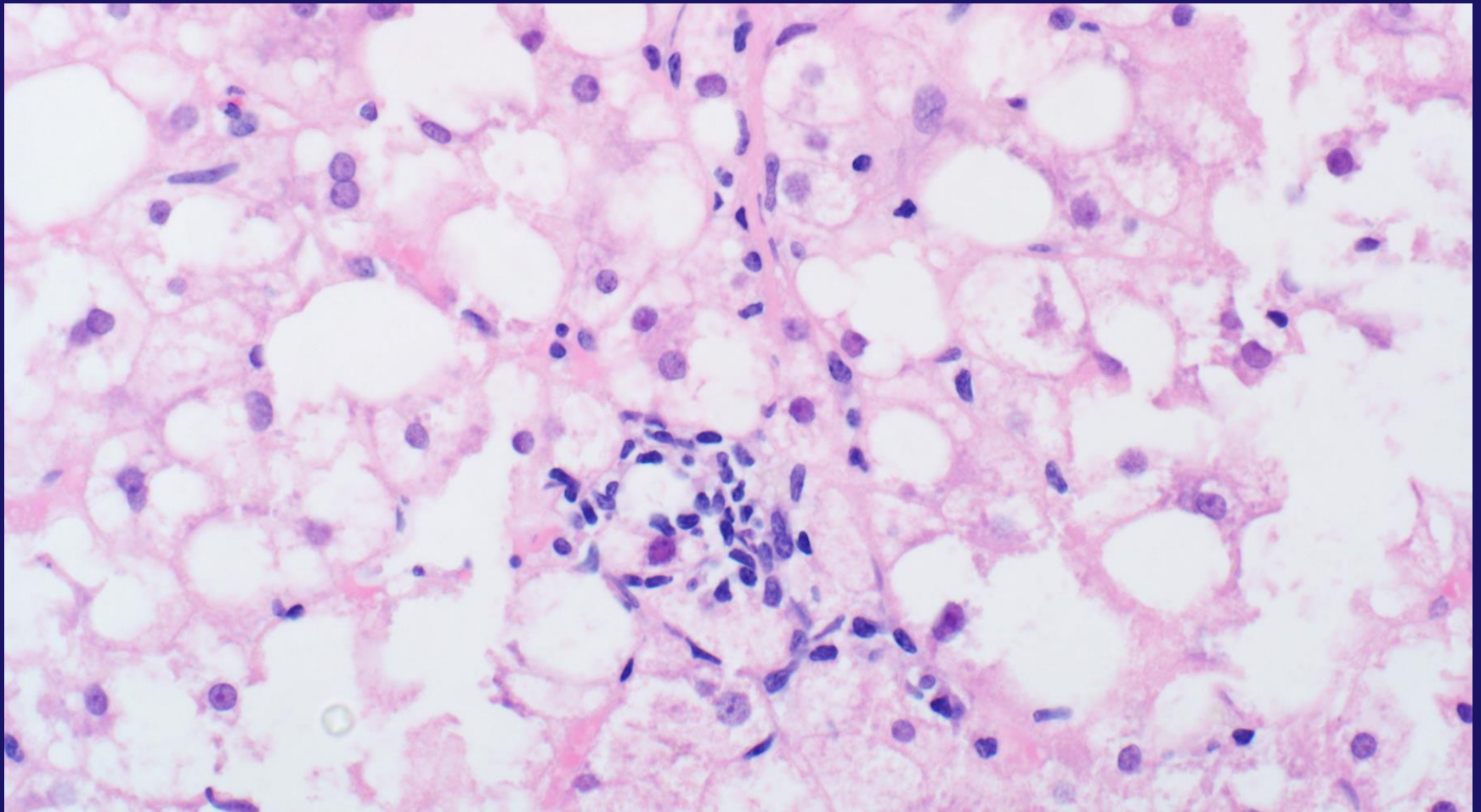
Steatohepatitis: Essential Features

AASLD and NASH Clinical Research Network

- Steatosis (>5%)
- **Inflammation (lobular)**
- Hepatocellular injury
 - Ballooned hepatocytes

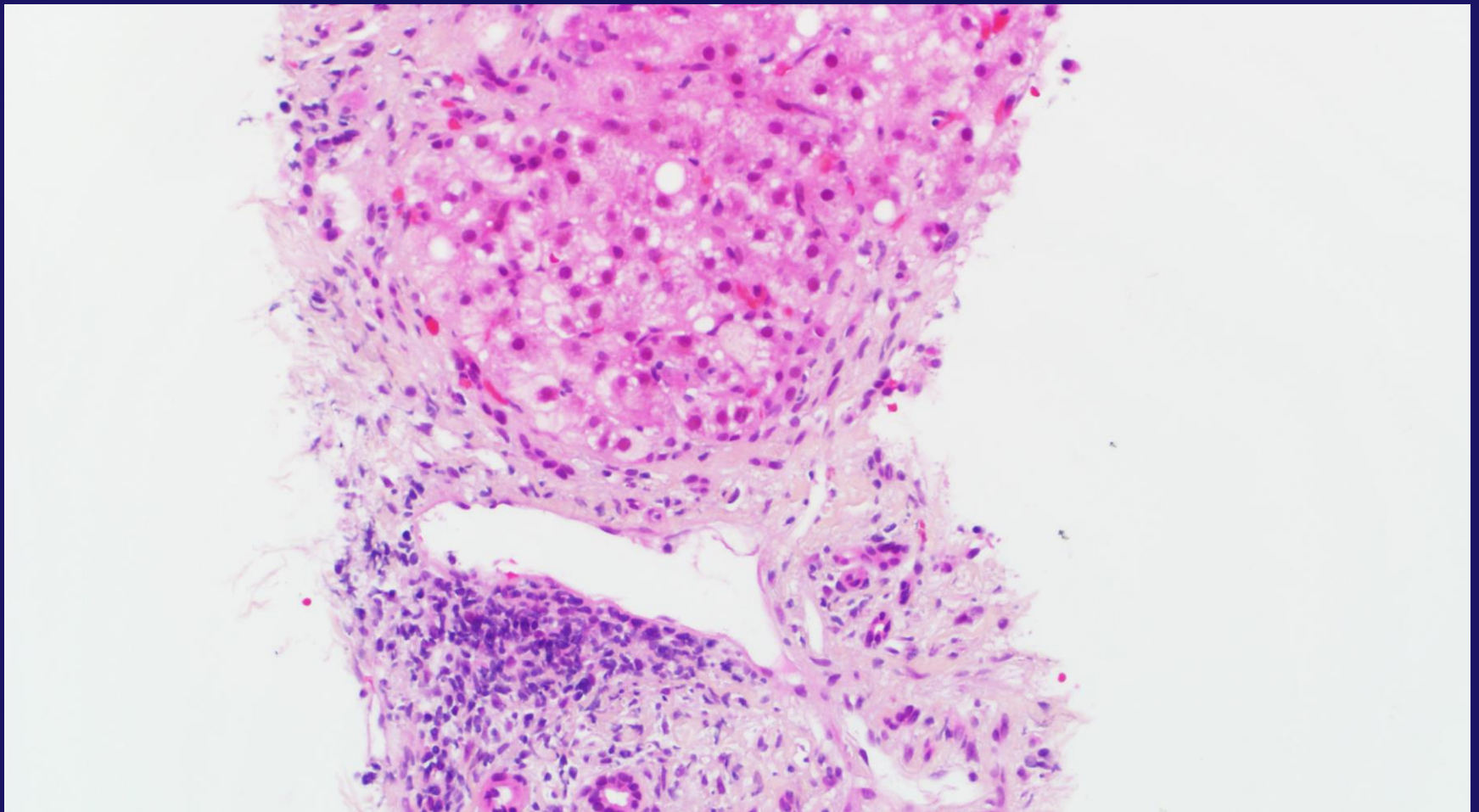
+/- Pericellular fibrosis

Lobular Inflammation in NASH



Gill R. M. and Kakar S. Non-alcoholic steatohepatitis, an update on diagnostic challenges, *Surgical Pathology Clinics*, Volume 6, Issue 2 , Pages 227-257, June 2013), adapted with permission from Elsevier.

Portal Inflammation in NASH



Gill R. M. and Kakar S. Non-alcoholic steatohepatitis, an update on diagnostic challenges, *Surgical Pathology Clinics*, Volume 6, Issue 2 , Pages 227-257, June 2013), adapted with permission from Elsevier.

Steatohepatitis: Essential Features

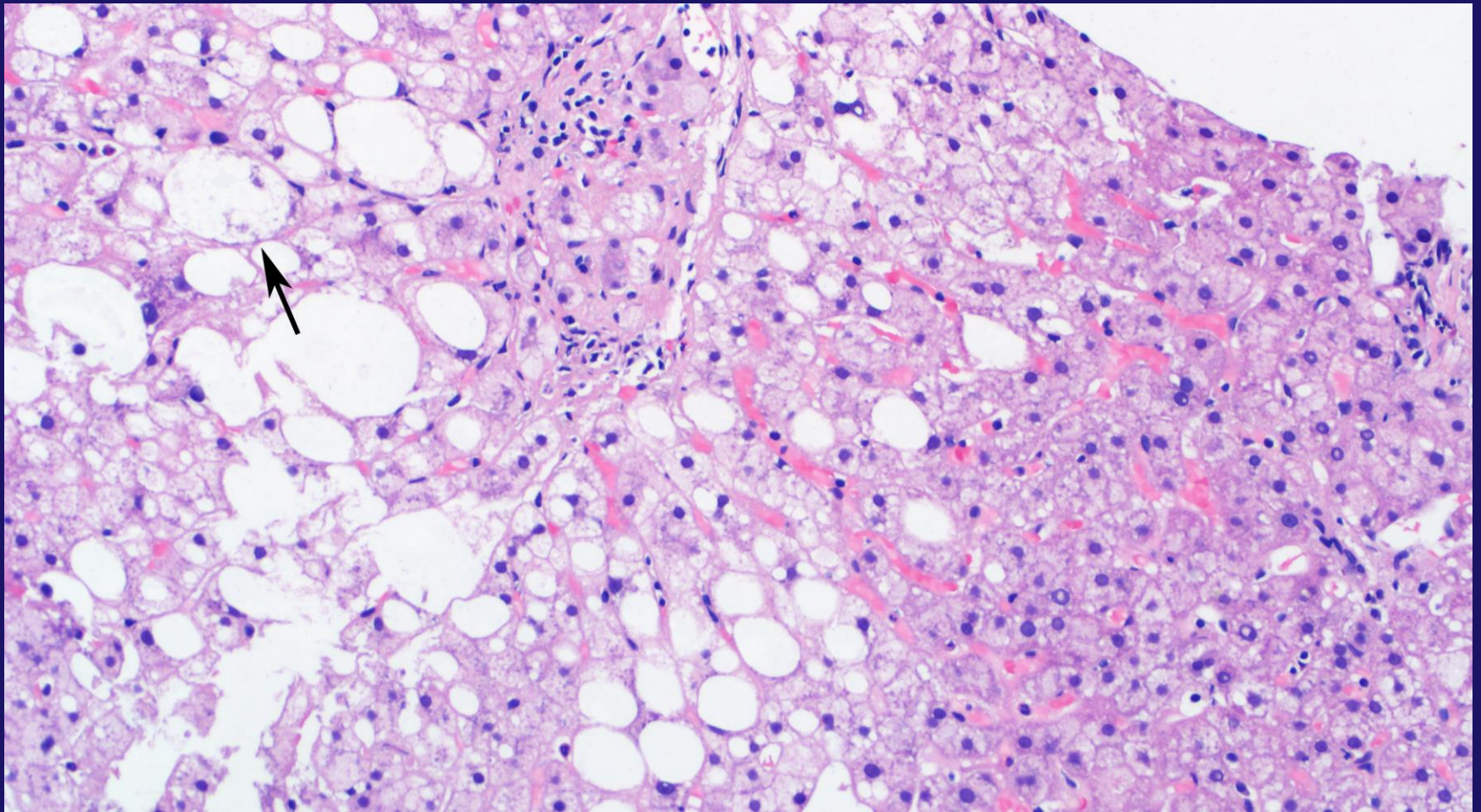
AASLD and NASH Clinical Research Network

- Steatosis (>5%)
- Inflammation (lobular)
- Hepatocellular injury

Ballooned hepatocytes

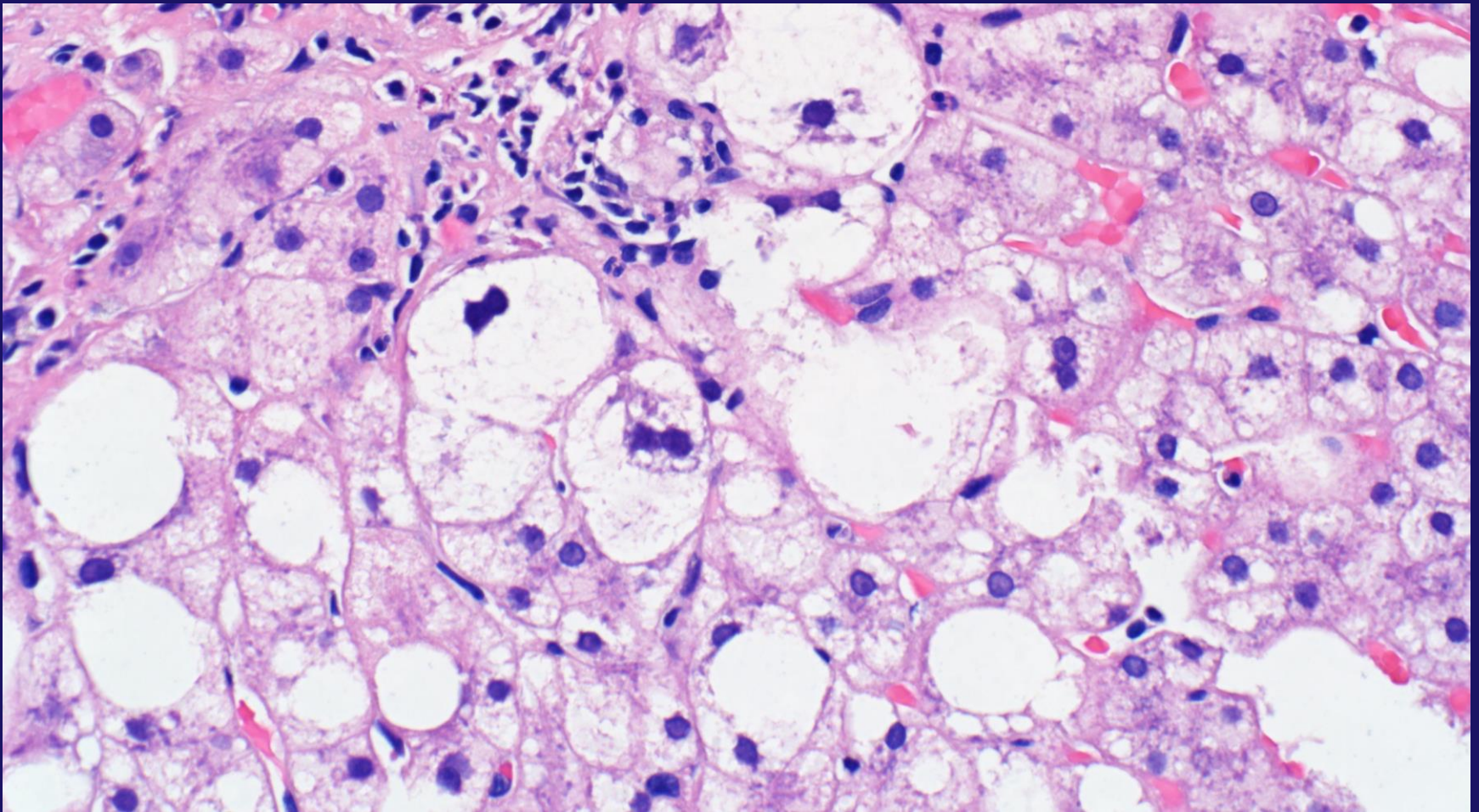
+/- Pericellular fibrosis

Ballooned Hepatocyte



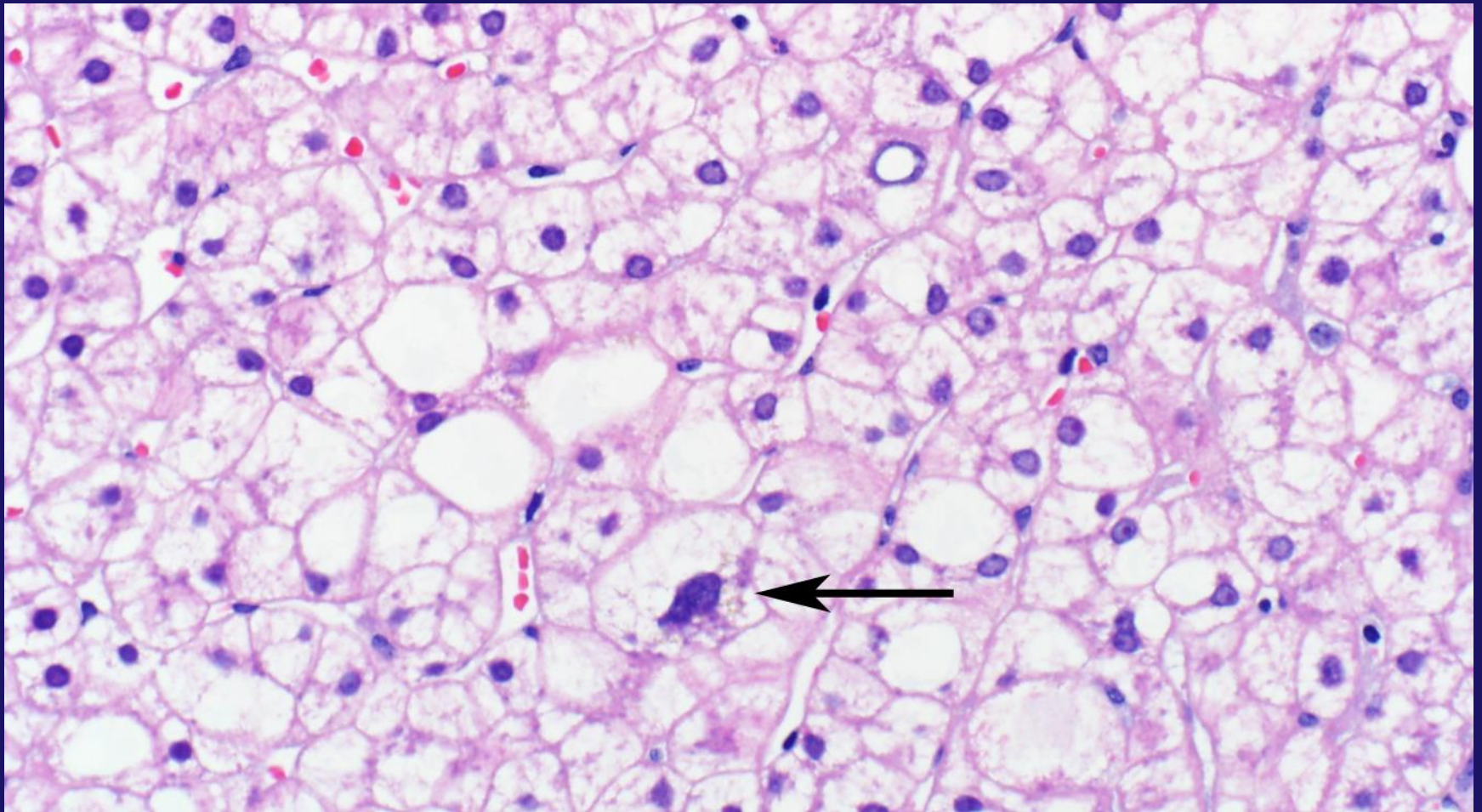
Gill R. M. and Kakar S. Non-alcoholic steatohepatitis, an update on diagnostic challenges, *Surgical Pathology Clinics*, Volume 6, Issue 2 , Pages 227-257, June 2013), adapted with permission from Elsevier.

Multiple Ballooned Hepatocytes



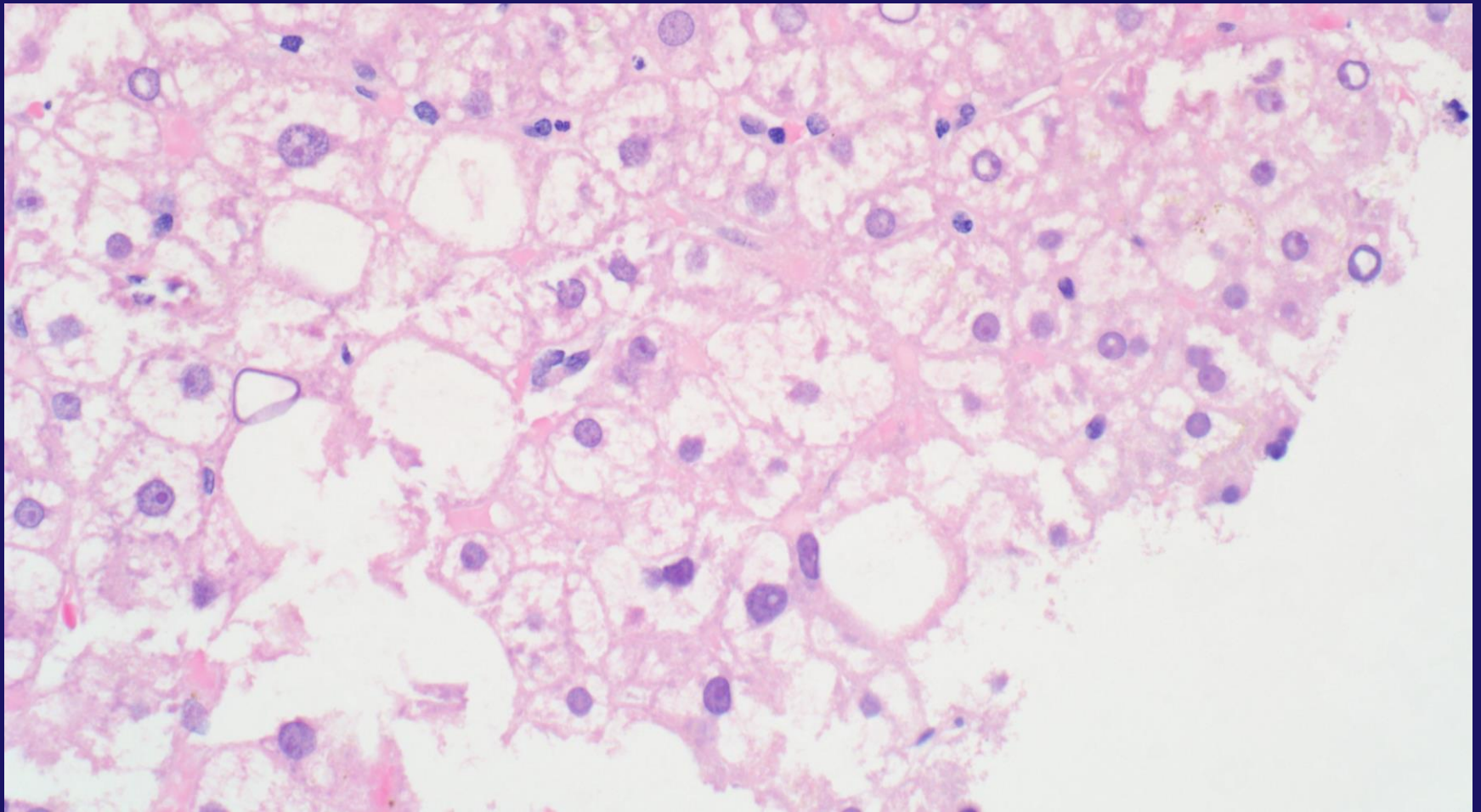
Gill R. M. and Kakar S. Non-alcoholic steatohepatitis, an update on diagnostic challenges, *Surgical Pathology Clinics*, Volume 6, Issue 2 , Pages 227-257, June 2013), adapted with permission from Elsevier.

BH Mimic – Small Droplet Fat



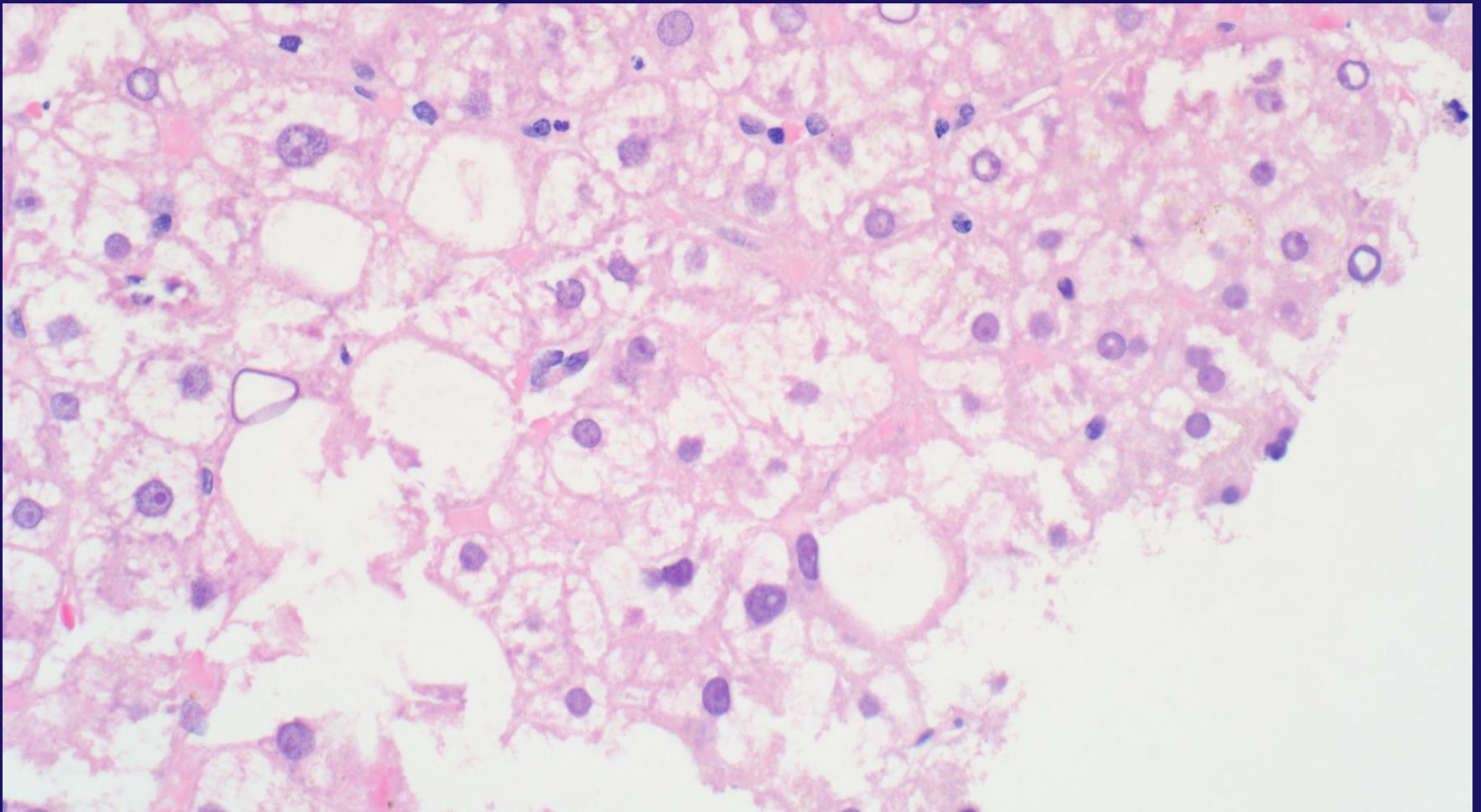
Gill R. M. and Kakar S. Non-alcoholic steatohepatitis, an update on diagnostic challenges, *Surgical Pathology Clinics*, Volume 6, Issue 2, Pages 227-257, June 2013), adapted with permission from Elsevier.

BH Mimic - Glycogenosis



Gill R. M. and Kakar S. Non-alcoholic steatohepatitis, an update on diagnostic challenges, *Surgical Pathology Clinics*, Volume 6, Issue 2 , Pages 227-257, June 2013), adapted with permission from Elsevier.

BH Mimic - Processing



Gill R. M. and Kakar S. Non-alcoholic steatohepatitis, an update on diagnostic challenges, *Surgical Pathology Clinics*, Volume 6, Issue 2 , Pages 227-257, June 2013), adapted with permission from Elsevier.

Steatohepatitis: Essential Features

AASLD and NASH Clinical Research Network

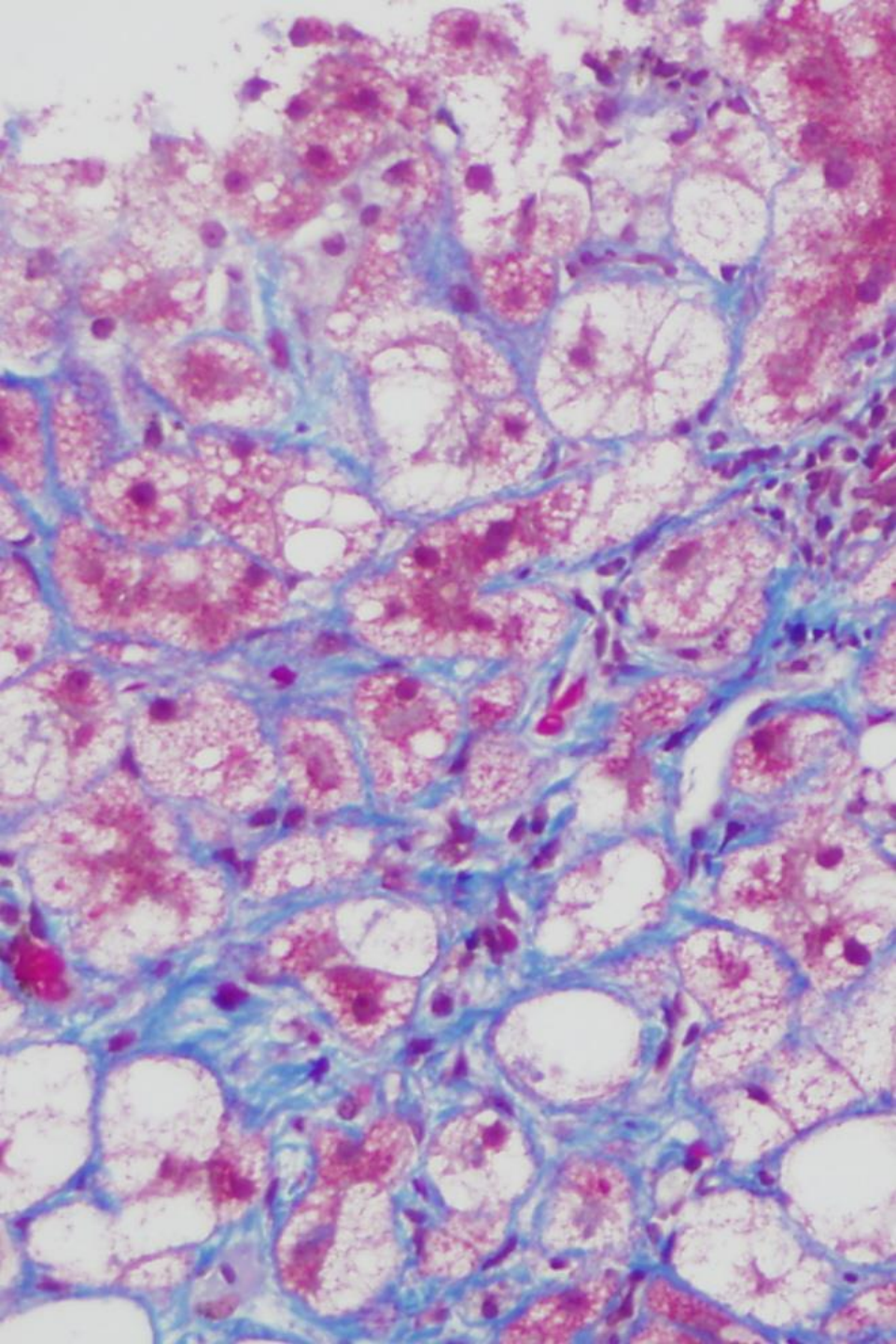
- Steatosis (>5%)
- Inflammation (lobular)
- Hepatocellular injury

Ballooned hepatocytes

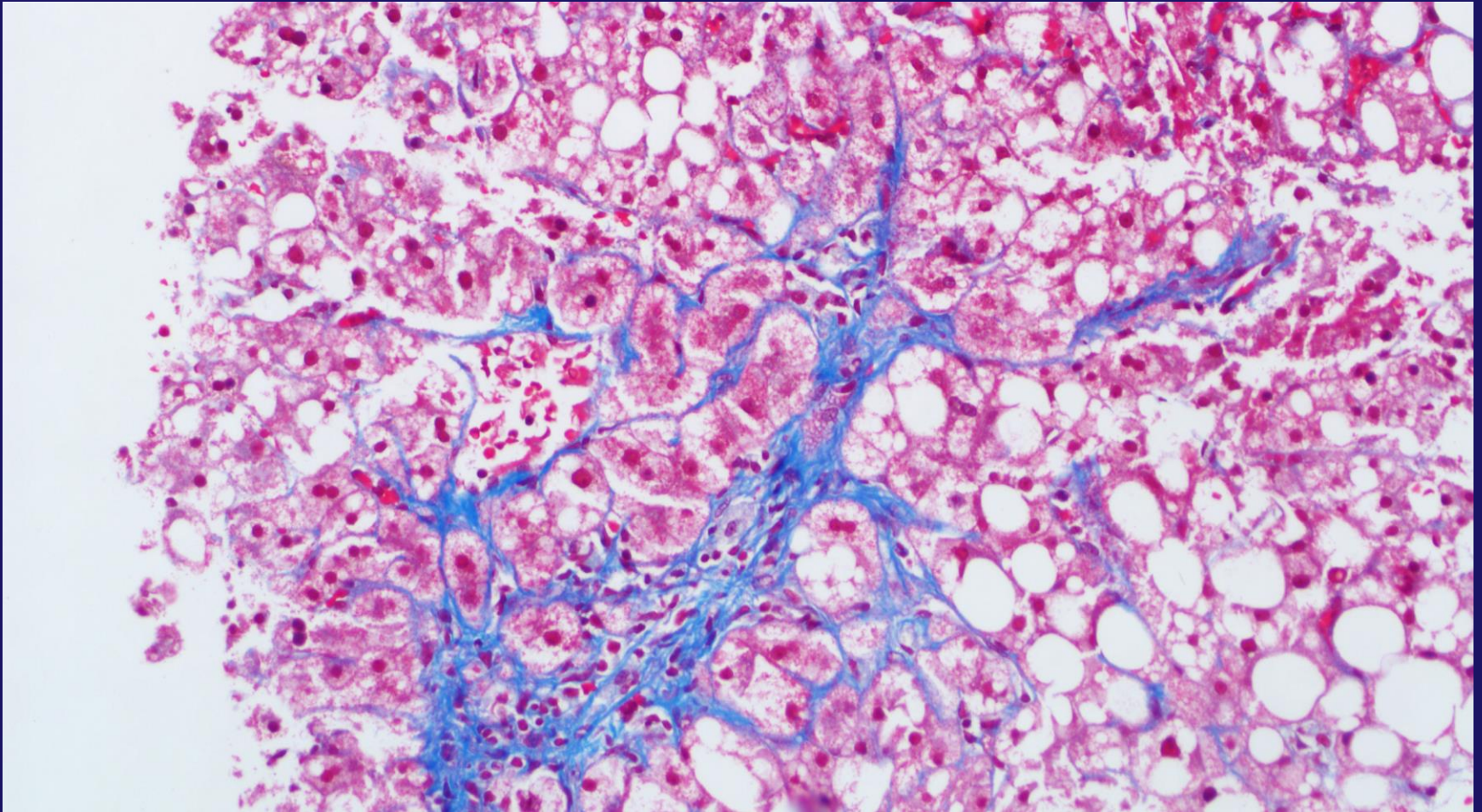
+/- **Pericellular fibrosis**

Staging - Modified Brunt Method

Stage 1A	Pericentral/sinusoidal Fibrosis – Delicate
Stage 1B	Pericentral/sinusoidal Fibrosis – Dense
Stage 1C	Periportal Fibrosis
Stage 2	Pericentral/sinusoidal and Periportal Fibrosis
Stage 3	Bridging Fibrosis
Stage 4	Cirrhosis

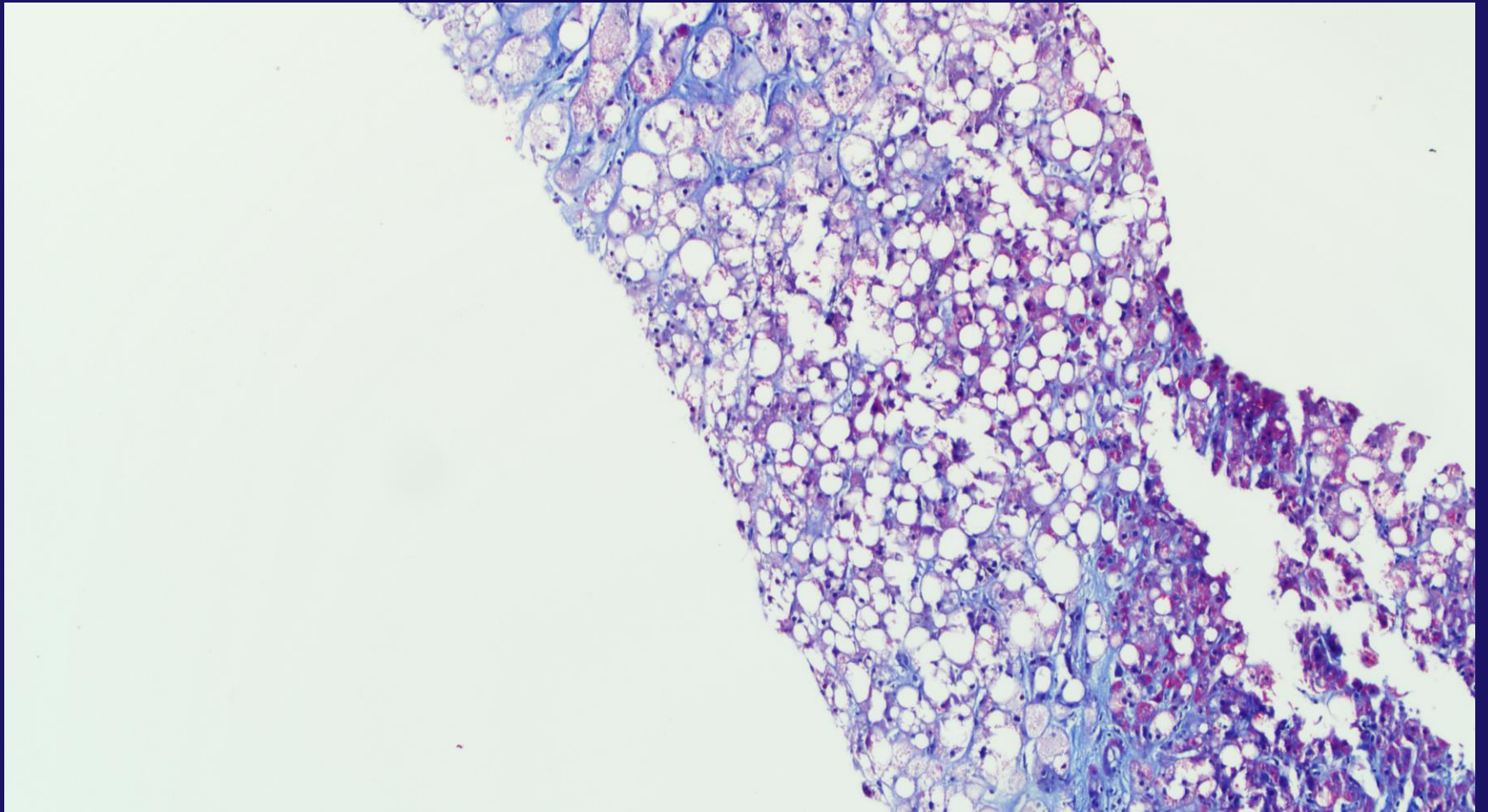


Stage 1



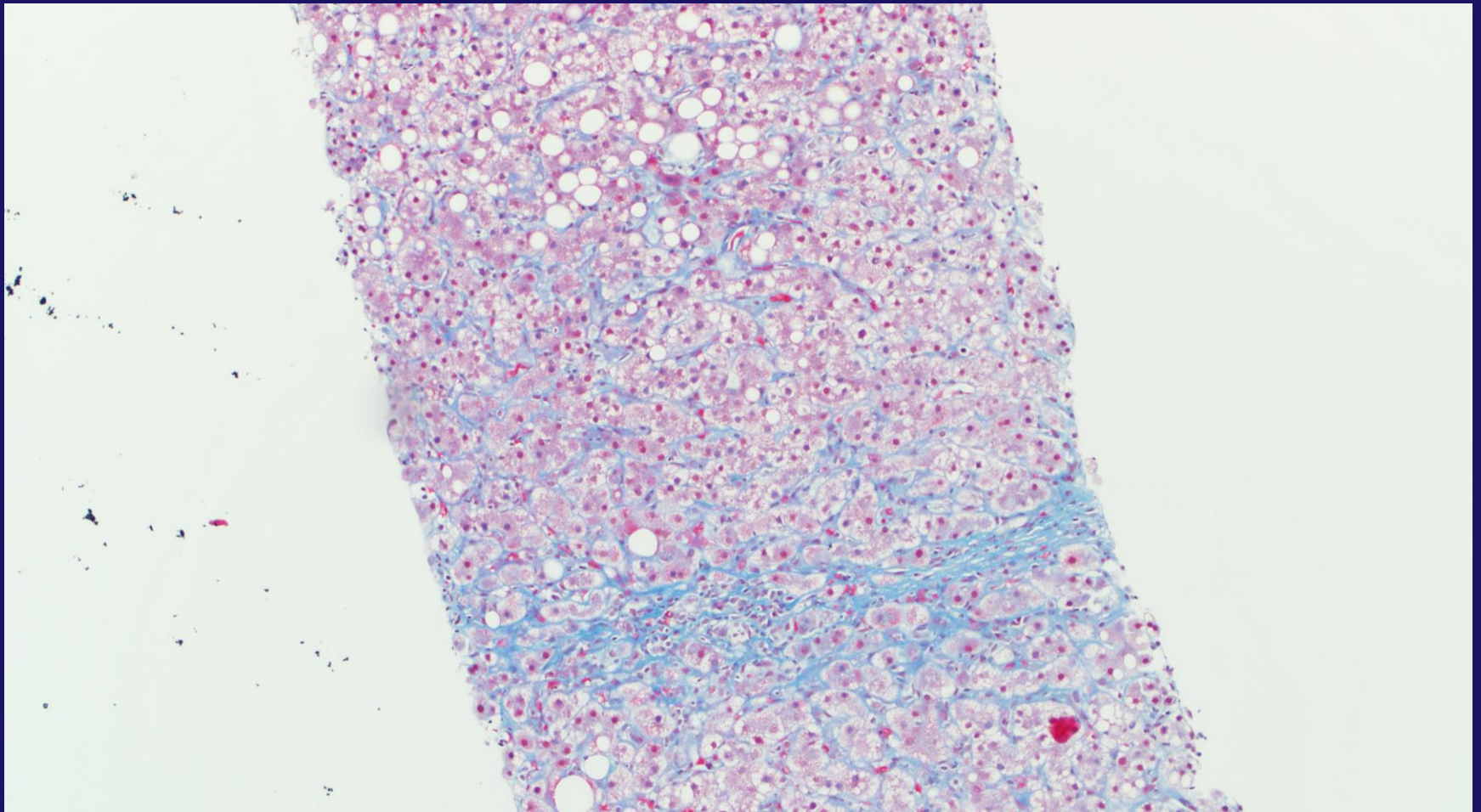
Gill R. M. and Kakar S. Non-alcoholic steatohepatitis, an update on diagnostic challenges, *Surgical Pathology Clinics*, Volume 6, Issue 2 , Pages 227-257, June 2013), adapted with permission from Elsevier.

Stage 2



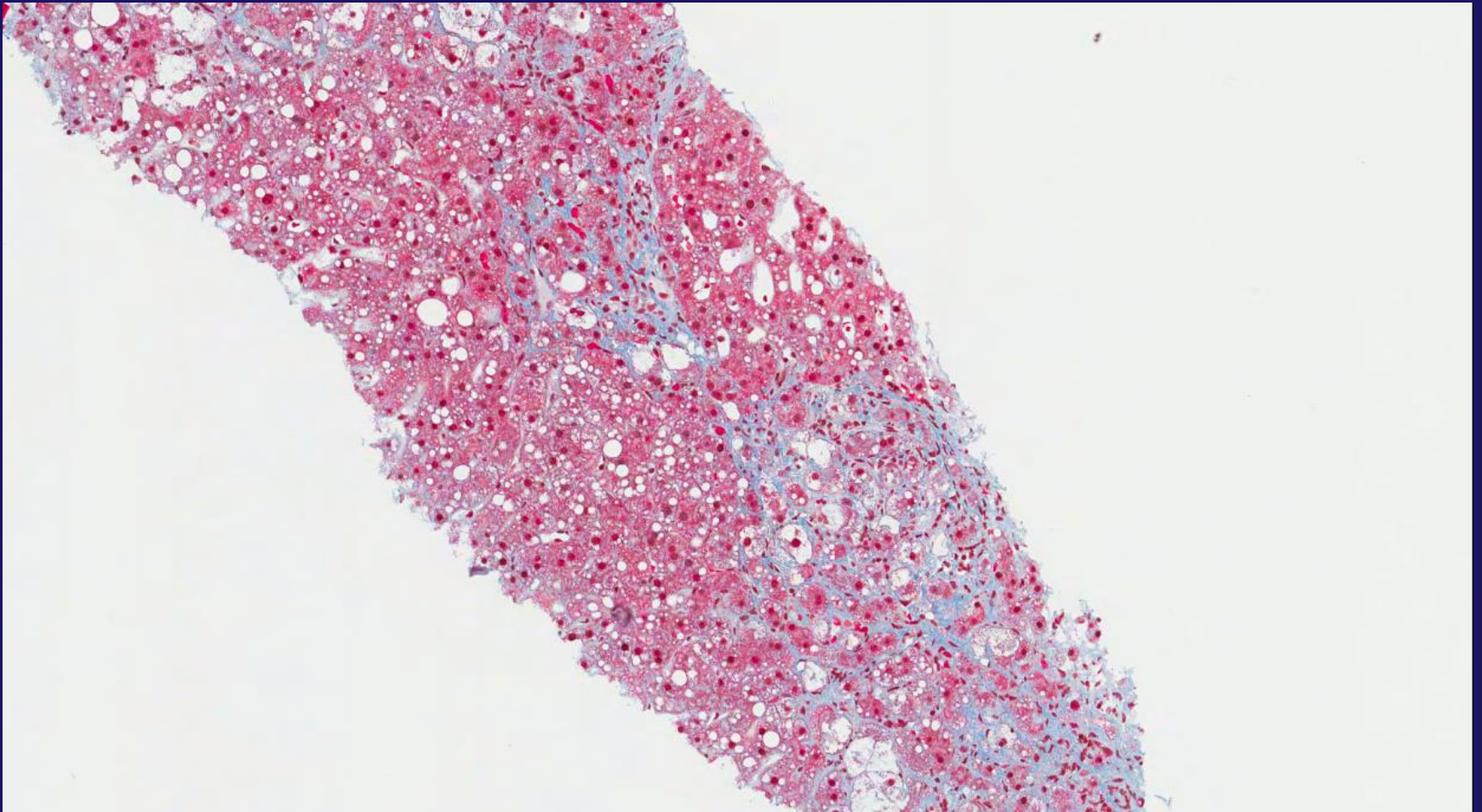
Gill R. M. and Kakar S. Non-alcoholic steatohepatitis, an update on diagnostic challenges, *Surgical Pathology Clinics*, Volume 6, Issue 2 , Pages 227-257, June 2013), adapted with permission from Elsevier.

Stage 3



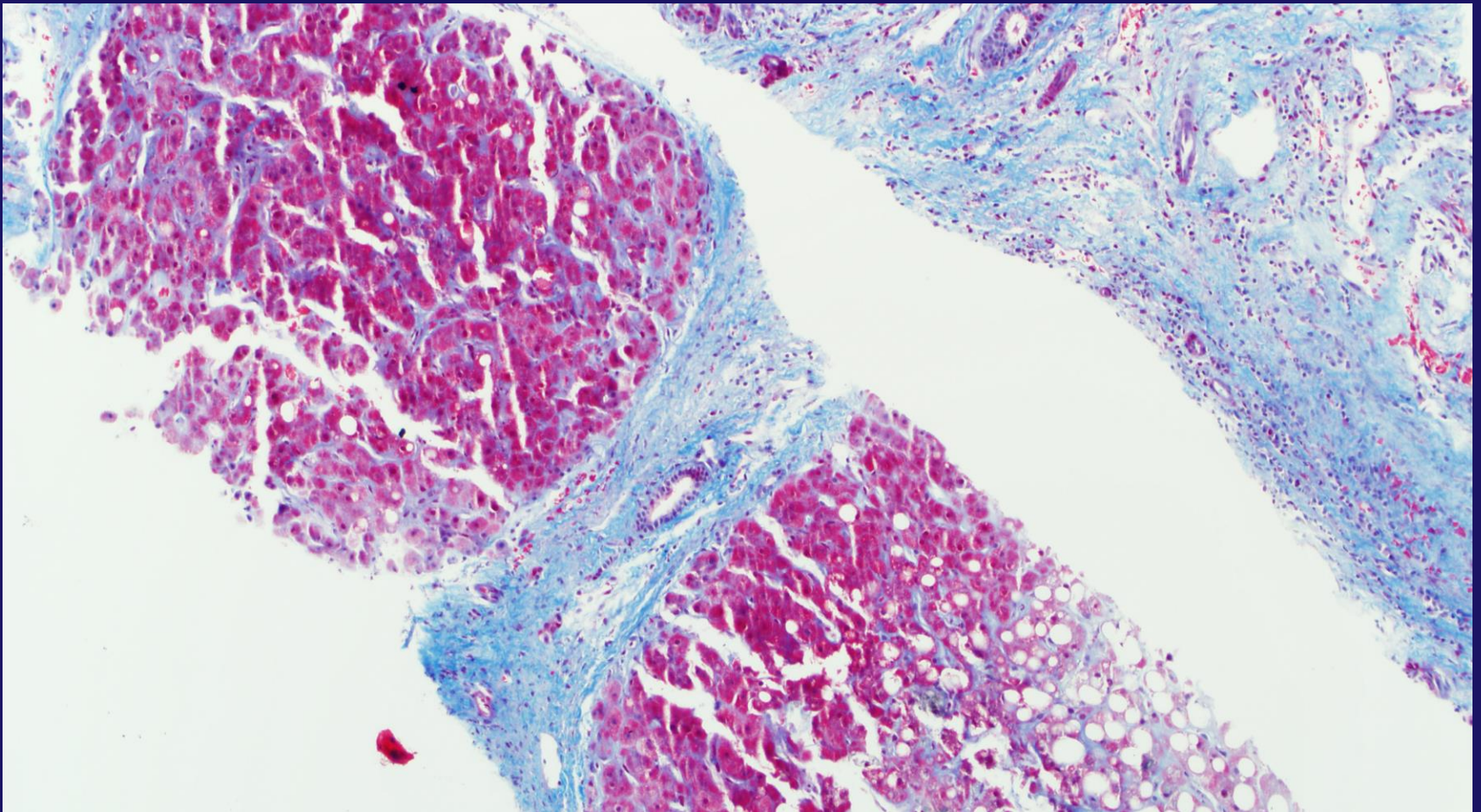
Gill R. M. and Kakar S. Non-alcoholic steatohepatitis, an update on diagnostic challenges, *Surgical Pathology Clinics*, Volume 6, Issue 2 , Pages 227-257, June 2013), adapted with permission from Elsevier.

Stage 3



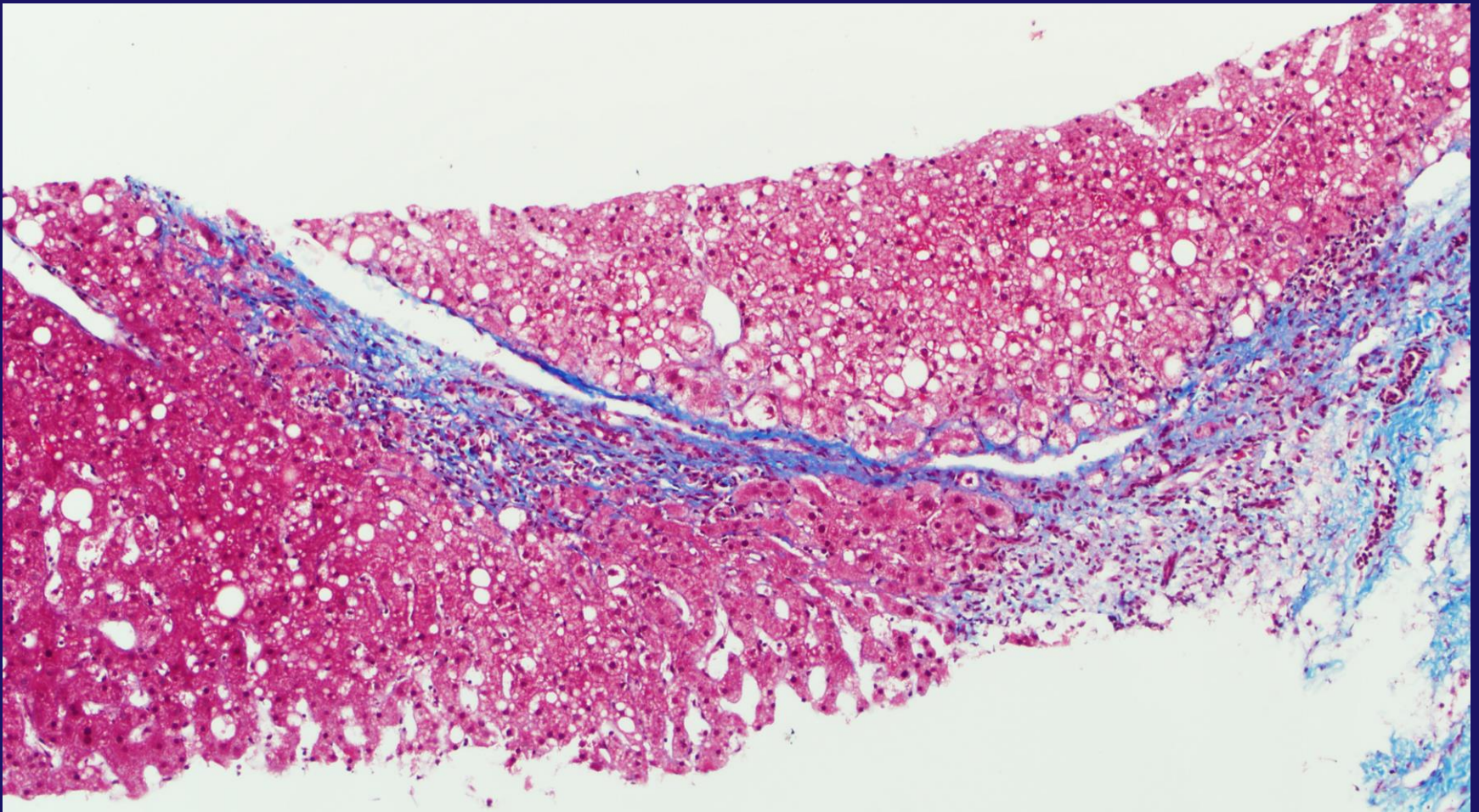
Gill R. M. and Kakar S. Non-alcoholic steatohepatitis, an update on diagnostic challenges, *Surgical Pathology Clinics*, Volume 6, Issue 2 , Pages 227-257, June 2013), adapted with permission from Elsevier.

Stage 4



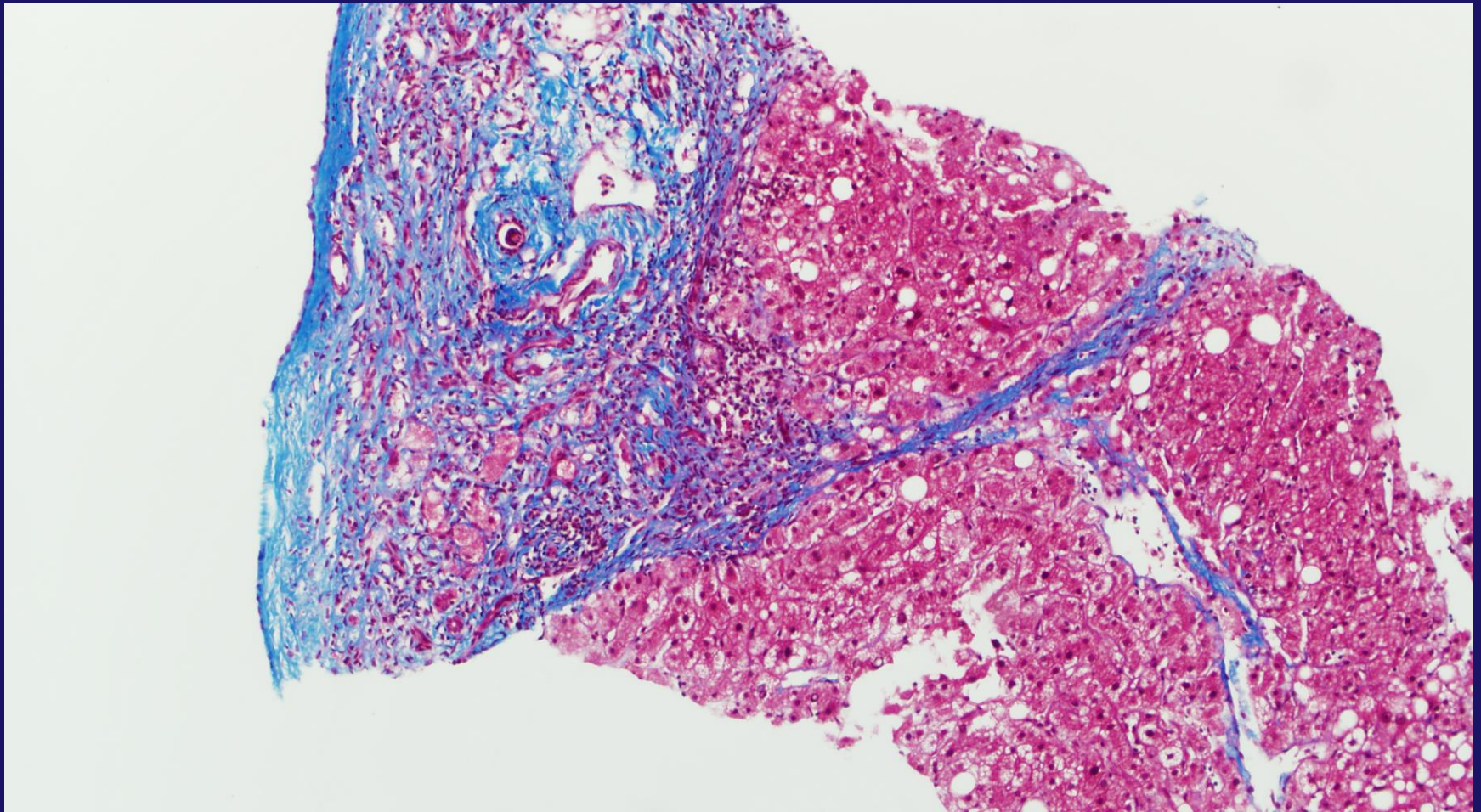
Gill R. M. and Kakar S. Non-alcoholic steatohepatitis, an update on diagnostic challenges, *Surgical Pathology Clinics*, Volume 6, Issue 2 , Pages 227-257, June 2013), adapted with permission from Elsevier.

Fibrosis Pitfall – Tangential



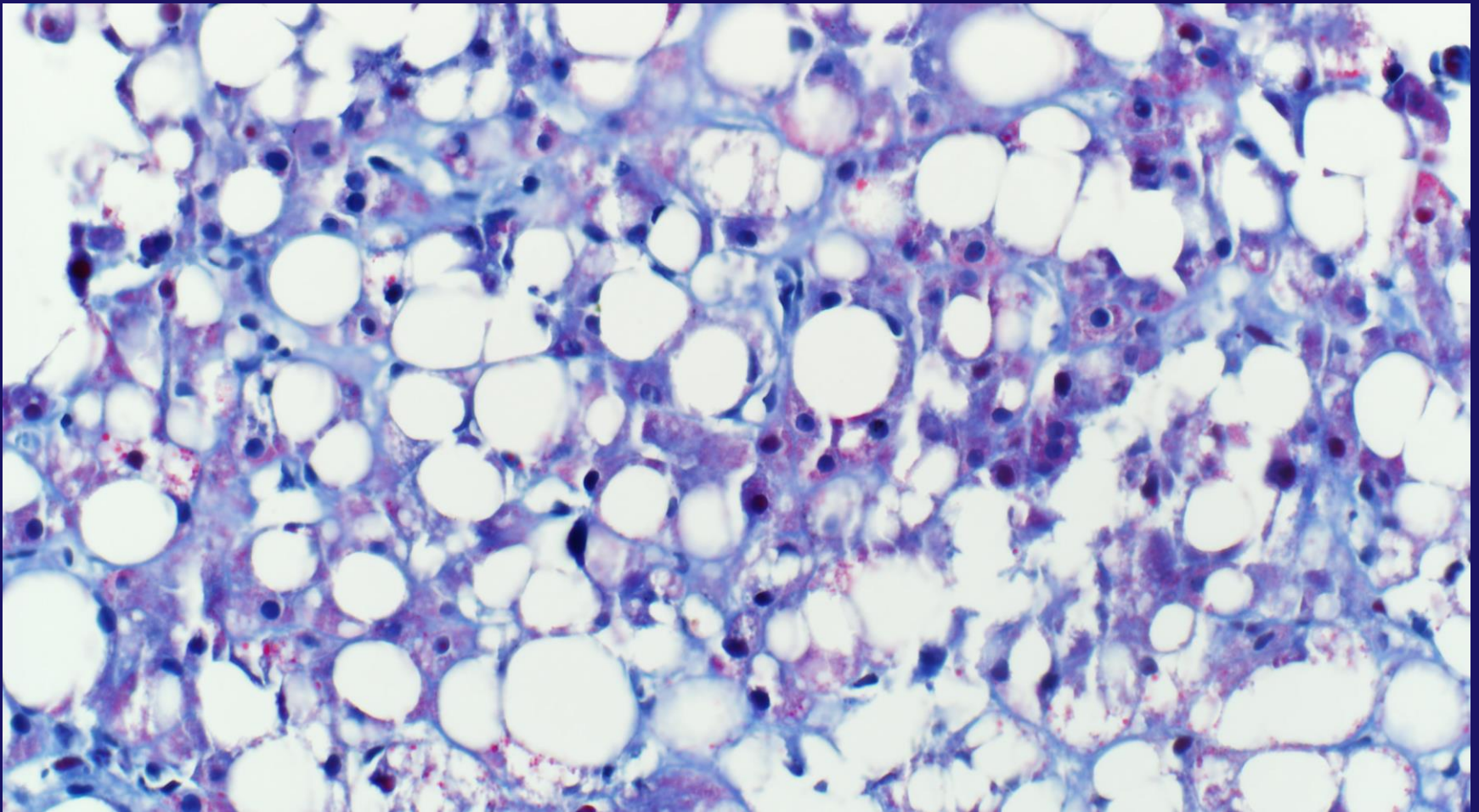
Gill R. M. and Kakar S. Non-alcoholic steatohepatitis, an update on diagnostic challenges, *Surgical Pathology Clinics*, Volume 6, Issue 2 , Pages 227-257, June 2013), adapted with permission from Elsevier.

Fibrosis Pitfall - Subcapsular



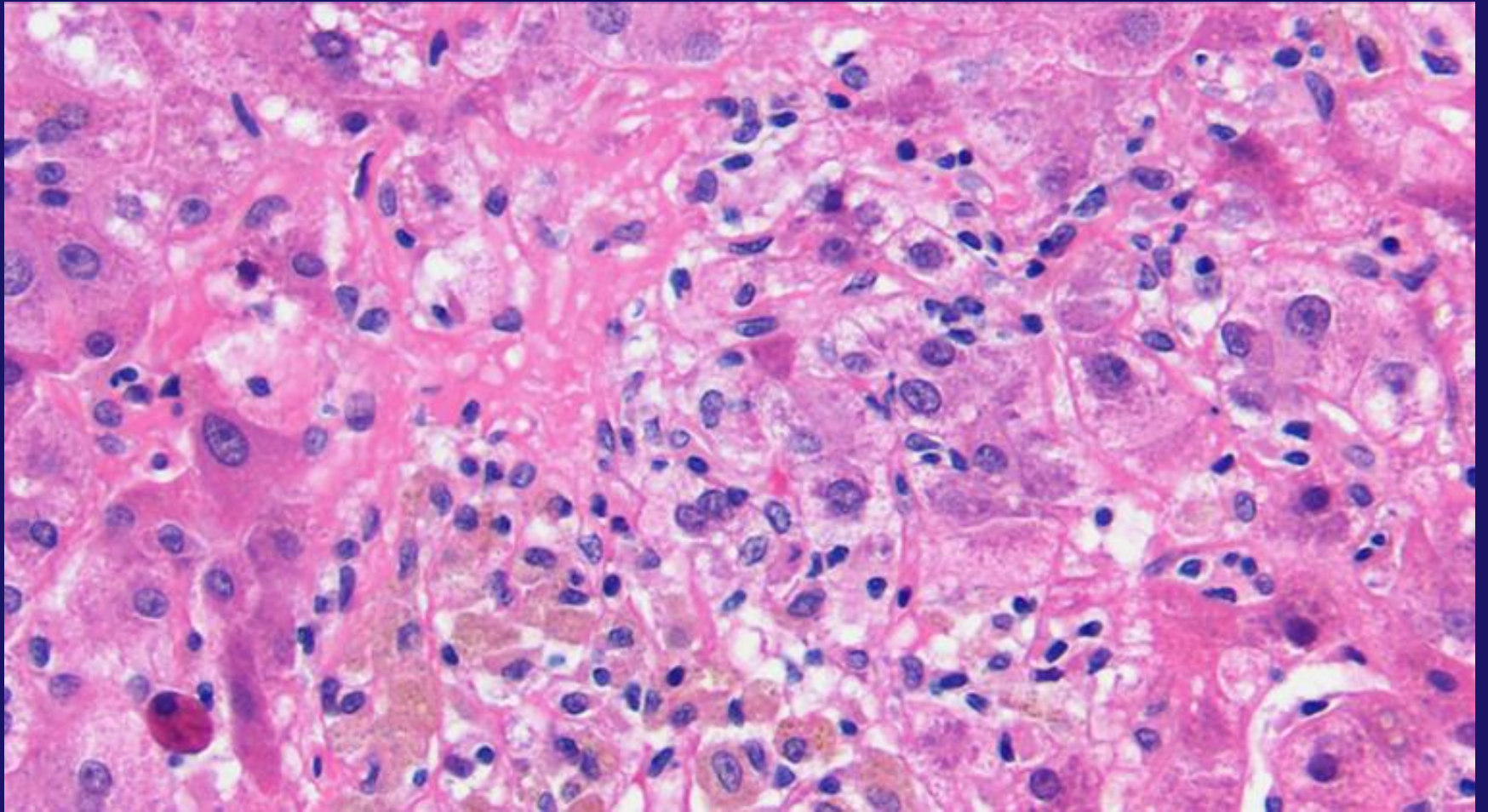
Gill R. M. and Kakar S. Non-alcoholic steatohepatitis, an update on diagnostic challenges, *Surgical Pathology Clinics*, Volume 6, Issue 2 , Pages 227-257, June 2013), adapted with permission from Elsevier.

Fibrosis Pitfall – Overstained

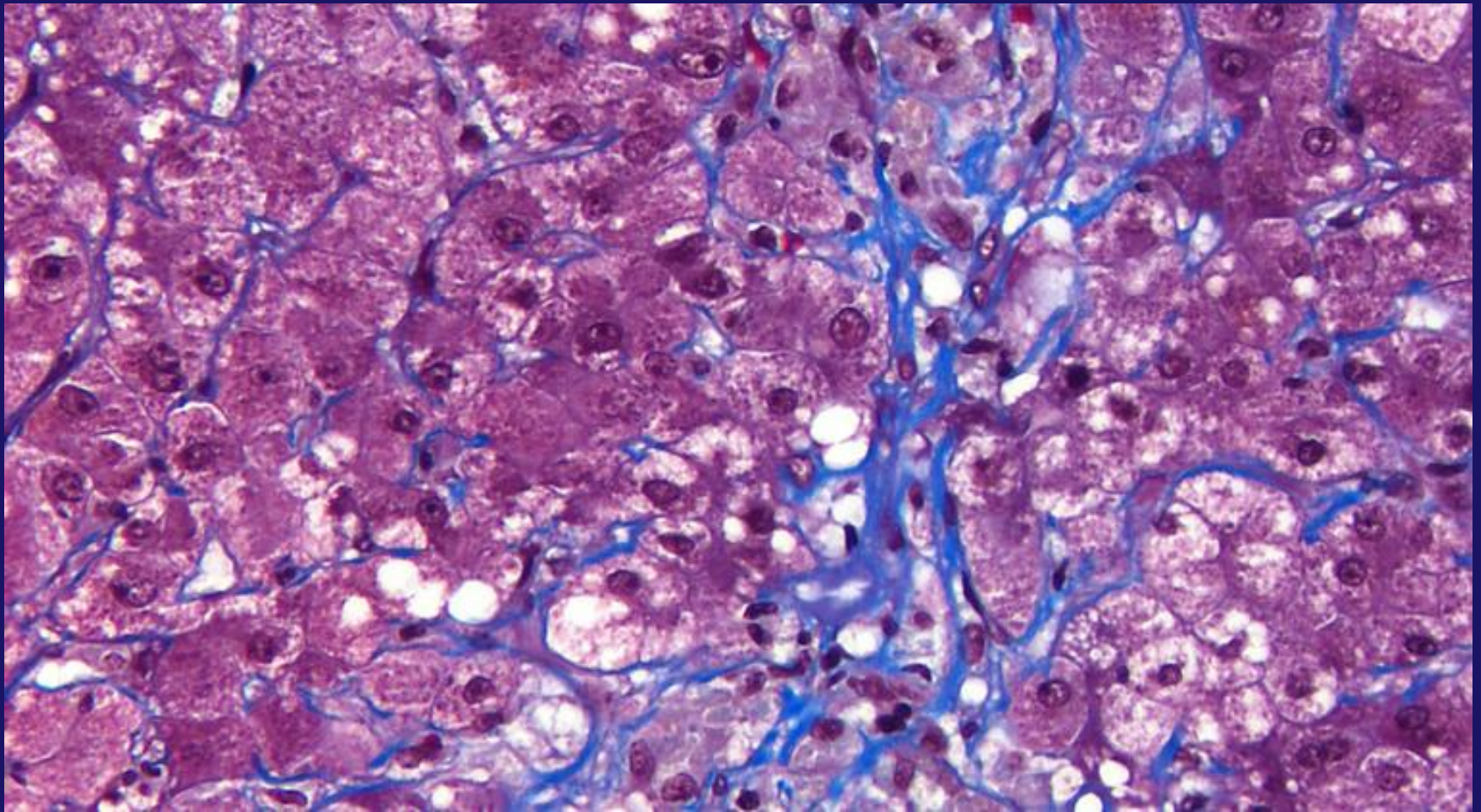


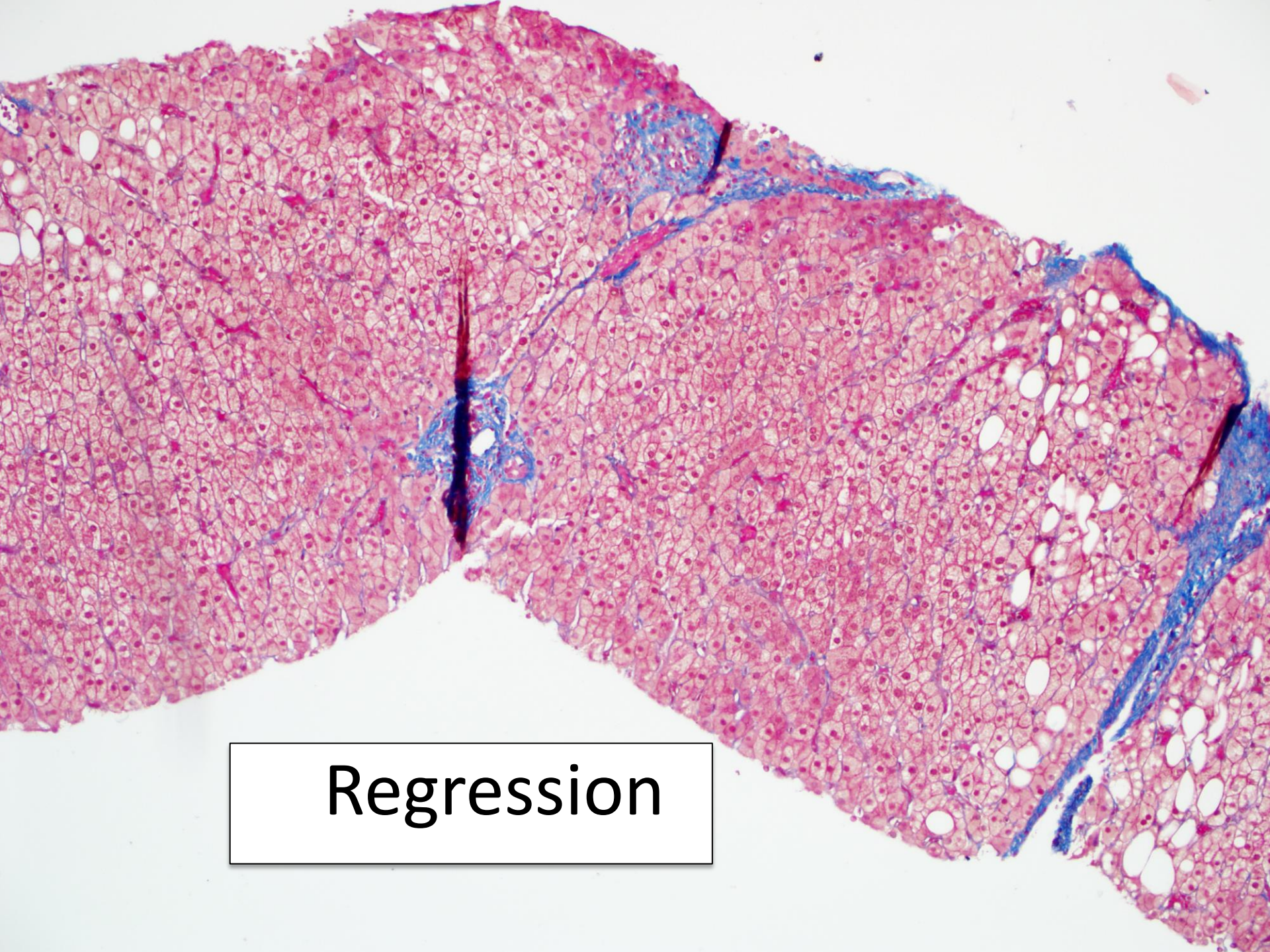
Gill R. M. and Kakar S. Non-alcoholic steatohepatitis, an update on diagnostic challenges, *Surgical Pathology Clinics*, Volume 6, Issue 2 , Pages 227-257, June 2013), adapted with permission from Elsevier.

Fibrosis Pitfall – Histiocyte Aggregate



Fibrosis Pitfall – Histiocyte Aggregate



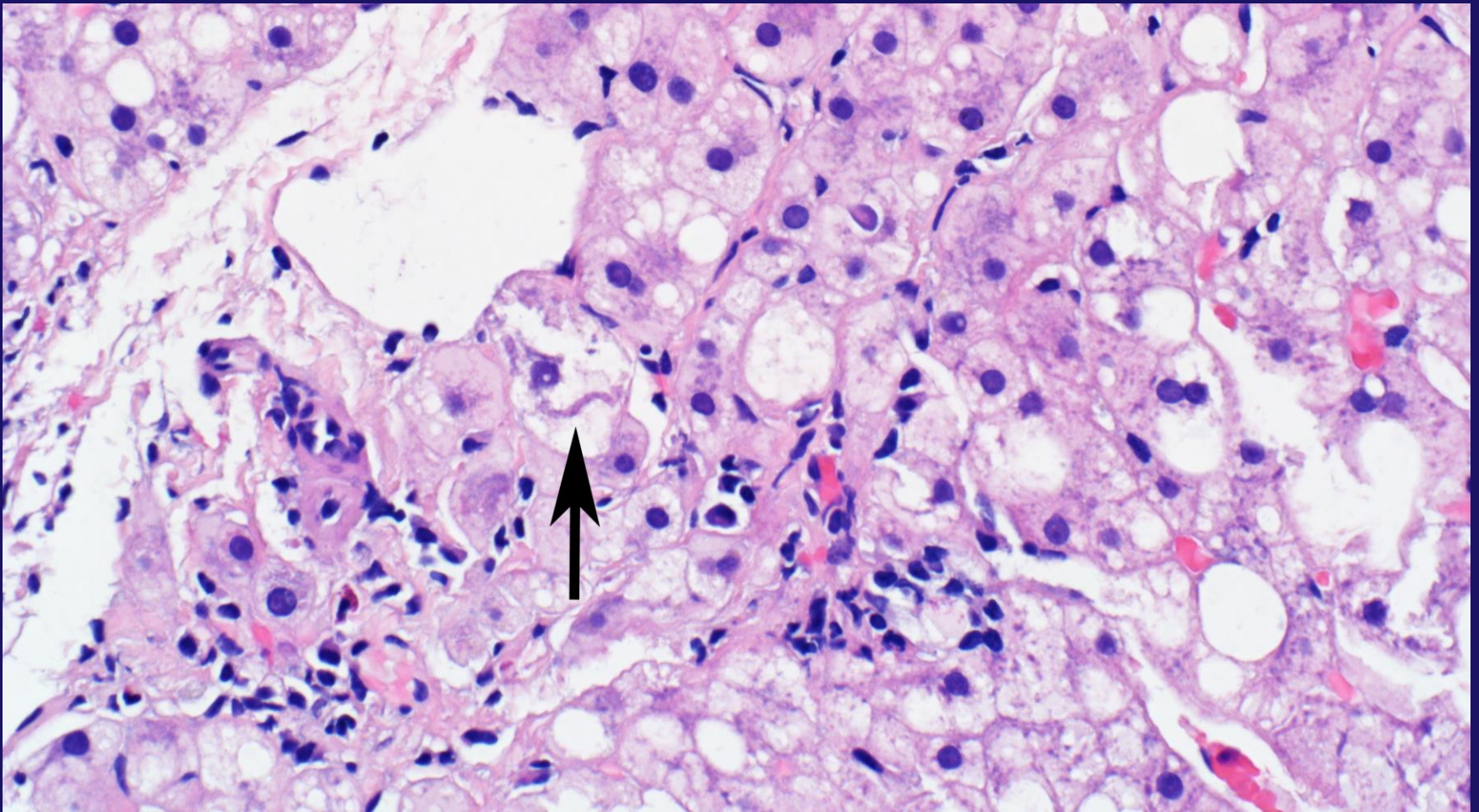


Regression

Steatohepatitis: Non-essential Features

- Mallory hyaline in Zone 3
- Mild iron deposits in hepatocytes or sinusoidal cells
- Megamitochondria
- Glycogenated nuclei
- Lipogranulomas
- Acidophil bodies (occasional)
- Centrizonal arteries

Mallory Hyaline



Gill R. M. and Kakar S. Non-alcoholic steatohepatitis, an update on diagnostic challenges, *Surgical Pathology Clinics*, Volume 6, Issue 2 , Pages 227-257, June 2013), adapted with permission from Elsevier.

Histologic Variation

PATTERN 1: CLASSIC STEATOHEPATITIS

Steatosis with mild inflammation, hepatocellular ballooning, and pericellular fibrosis

Histologic Variation

PATTERN 2: STEATOSIS WITHOUT HEPATOCELLULAR INJURY

Steatosis without hepatocyte ballooning or pericellular fibrosis is insufficient for a diagnosis of steatohepatitis and represents NAFL

Low rate of progression (~5%) to significant fibrosis

Histologic Variation

PATTERN 3: STEATOSIS WITH SWOLLEN HEPATOCTES/NON-CLASSIC BALLOONED HEPATOCTES

Borderline for steatohepatitis; if clinical risk factors are present, it is best to manage the patient as appropriate for steatohepatitis

Histologic Variation

PATTERN 4: BALLOONED HEPATOCYTES OR PERICELLULAR FIBROSIS WITHOUT STEATOSIS

Uncommon in patients with metabolic risk factors

Ballooned Hepatocytes Only

Recent cessation of Alcohol

Amiodarone

Pericellular Fibrosis Only

Chronic venous outflow obstruction

Remote CZ injury

Histologic Variation

PATTERN 5: STEATOSIS WITH PERICELLULAR FIBROSIS, BUT NO BALLOONED HEPATOCYTES

Borderline for steatohepatitis in the appropriate clinical context

Other considerations: chronic venous outflow obstruction, drug (e.g. oxaliplatin), remote parenchymal rejection (post-transplant)

Histologic Variation

PATTERN 6: CIRRHOSIS WITH STEATOSIS AND/OR BALLOONED HEPATOCYTES

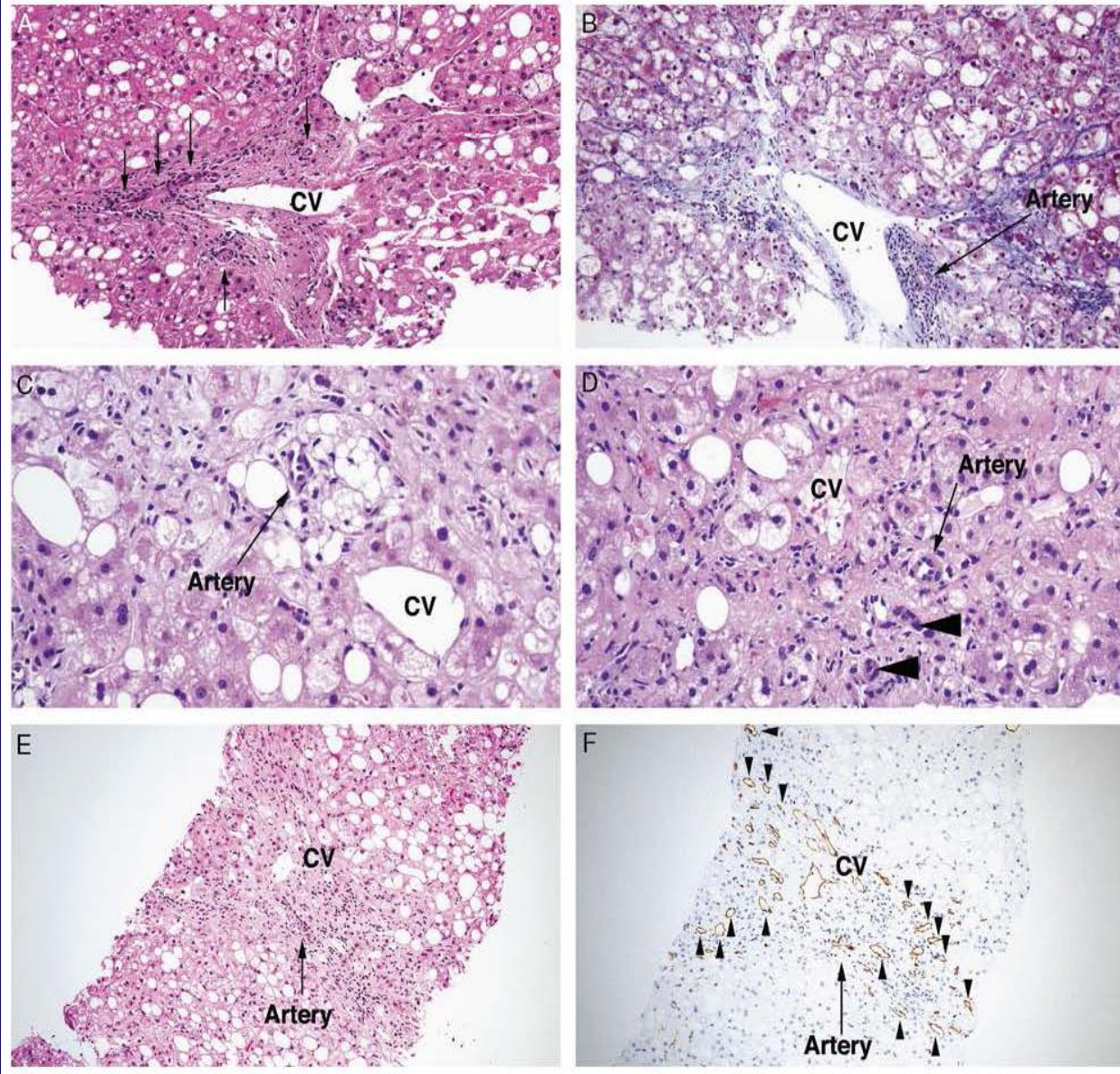
Cirrhosis with histologic features of NAFLD is best considered NASH cirrhosis. Some cases may show residual pericellular fibrosis.

ORIGINAL ARTICLE

Centrizonal Arteries and Microvessels in Nonalcoholic Steatohepatitis

Ryan M. Gill, MD, PhD, Patricia Belt, BS,† Laura Wilson, ScM,† Nathan M. Bass, MD, PhD,‡
and Linda D. Ferrell, MD**

(*Am J Surg Pathol* 2011;35:1400–1404)



Gill RM, Belt P, Wilson L, Bass NM, Ferrell LD. Centrilobular arteries and microvessels in nonalcoholic steatohepatitis. *Am J Surg Pathol.* 2011 Sep;35(9):1400-4. doi: 10.1097/PAS.0b013e3182254283. PubMed PMID: 21836480; PubMed Central PMCID: PMC3156381.

TABLE 1. NASH Fibrosis Stage Versus Prevalence of Centrizonal Arteries (Grade)*

	Grade 0	Grade 1	Grade 2	Grade 3	Total (%)
Stage 1b/1c	17	2	0	0	2/19 (11%)
Stage 2	25	7	1	1	9/34 (27%)
Stage 3	15	8	10	3	21/36 (58%)
Stage 4	3	1	2	5	8/11 (73%)
Total	60	18	13	9	40/100 (40%)

Artery grades: 0, no central zones with artery; 1, 1 to 2 central zones with artery/biopsy; 2, > 2 and < 50% of central zones with artery; 3, ≥ 50% of central zones with artery. Definitions of stages: 1b centrizonal fibrosis only, without the use of trichrome stain (ie, readily discernible on H&E stain), 1c periportal fibrosis only, 2 centrizonal and periportal fibrosis, 3 bridging fibrosis, 4 cirrhosis.

* $P < 0.001$ using univariate ordinal logistic regression.

Aggressive non-alcoholic steatohepatitis following rapid weight loss and/or malnutrition

Jia-Huei Tsai^{1,2}, Linda D Ferrell³, Vivian Tan⁴, Matthew M Yeh⁵, Monika Sarkar⁶ and Ryan M Gill³

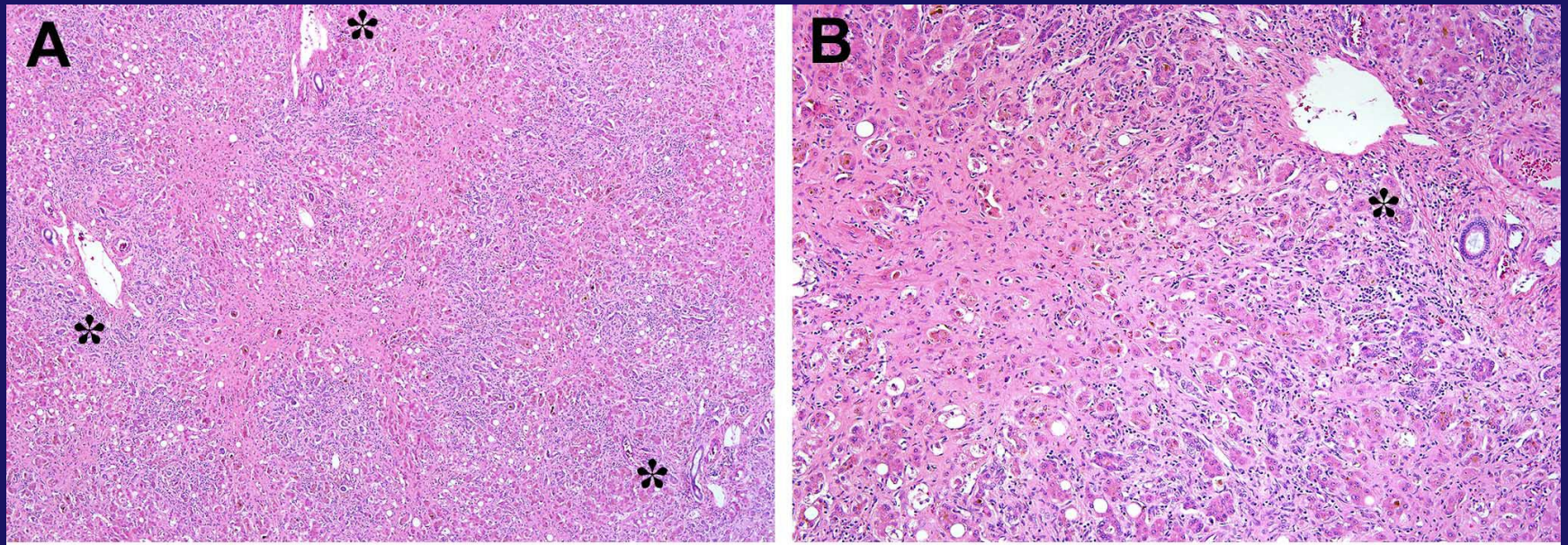
Aggressive NASH

- NASH presenting as ALF
- We described 6 patients who developed ALF following rapid loss or malnutrition
- 4 patients either died or required urgent liver transplant
- Pathologic findings similar to advanced alcoholic steatohepatitis

Pathologic Features

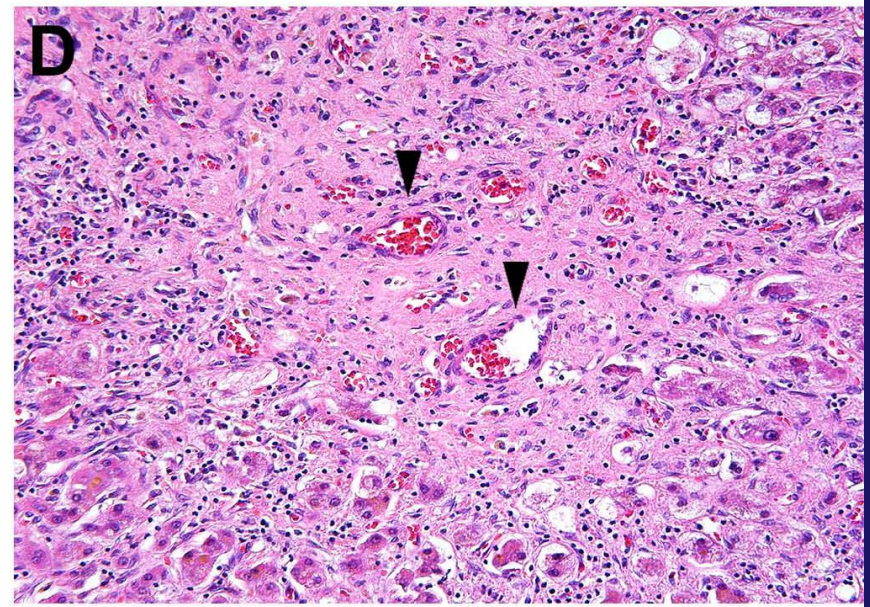
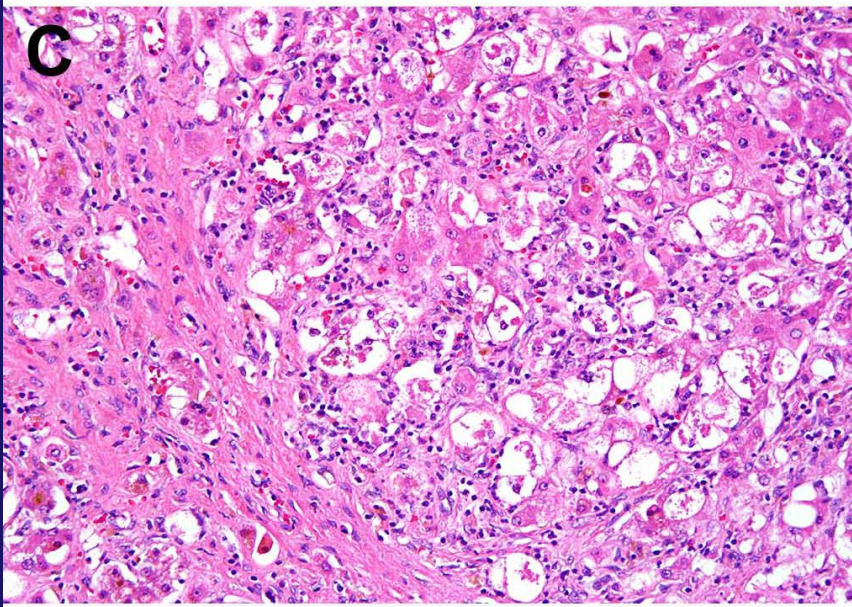
- Extensive/circumferential centrizonal pericellular fibrosis
- Central scar with perivenular sclerosis/veno-occlusion with superimposed hepatocellular dropout
- Abundant/prominent hepatocellular balloons, and numerous Mallory-Denk bodies
- Centrizonal arteries often prominent

Severe Centrizonal Scarring



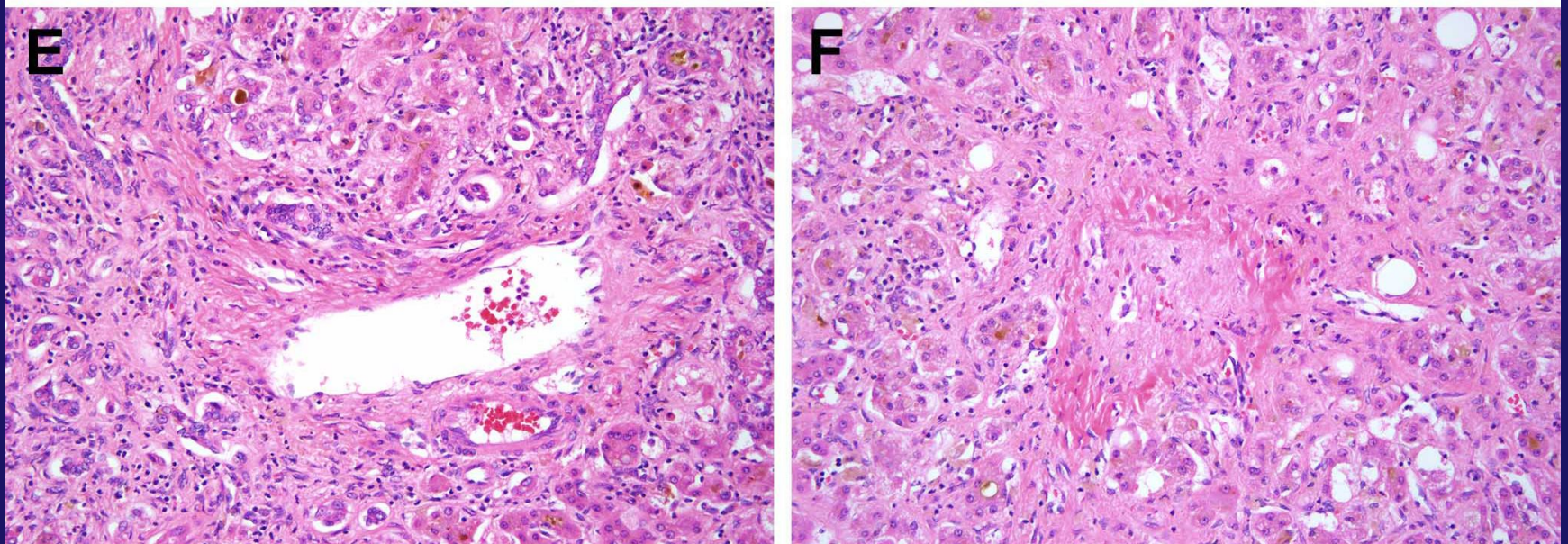
Tsai JH, Ferrell LD, Tan V, Yeh MM, Sarkar M, Gill RM. Aggressive non-alcoholic steatohepatitis following rapid weight loss and/or malnutrition. *Mod Pathol.* 2017 Jun;30(6):834-842. doi: 10.1038/modpathol.2017.13. Epub 2017 Mar 3. PubMed PMID: 28256569.

Prominent BH and Centrizonal Arteries



Tsai JH, Ferrell LD, Tan V, Yeh MM, Sarkar M, Gill RM. Aggressive non-alcoholic steatohepatitis following rapid weight loss and/or malnutrition. *Mod Pathol.* 2017 Jun;30(6):834-842. doi: 10.1038/modpathol.2017.13. Epub 2017 Mar 3. PubMed PMID: 28256569.

Ductular Reaction, Cholestasis, and Central Vein Occlusion



Tsai JH, Ferrell LD, Tan V, Yeh MM, Sarkar M, Gill RM. Aggressive non-alcoholic steatohepatitis following rapid weight loss and/or malnutrition. *Mod Pathol*. 2017 Jun;30(6):834-842. doi: 10.1038/modpathol.2017.13. Epub 2017 Mar 3. PubMed PMID: 28256569.

Diagnostic Challenges

1. Alcoholic steatohepatitis
2. Burnt out NASH cirrhosis
3. Drug induced steatohepatitis
4. Hereditary hemochromatosis
5. Metabolic disorders
6. Microvesicular steatosis
7. More than mild portal inflammation

Alcoholic Steatohepatitis

- Alcoholic steatohepatitis can not be definitively distinguished from NASH by histology

	NASH	ASH
Steatosis	++	+
Ballooned hepatocytes	+	++
Lobular inflammation	+	++
Mallory hyaline	+	++
Neutrophil infiltrate	+	++
Cholestasis	+/-	+
Obliterated CV	+/-	+

Burnt-out NASH Cirrhosis

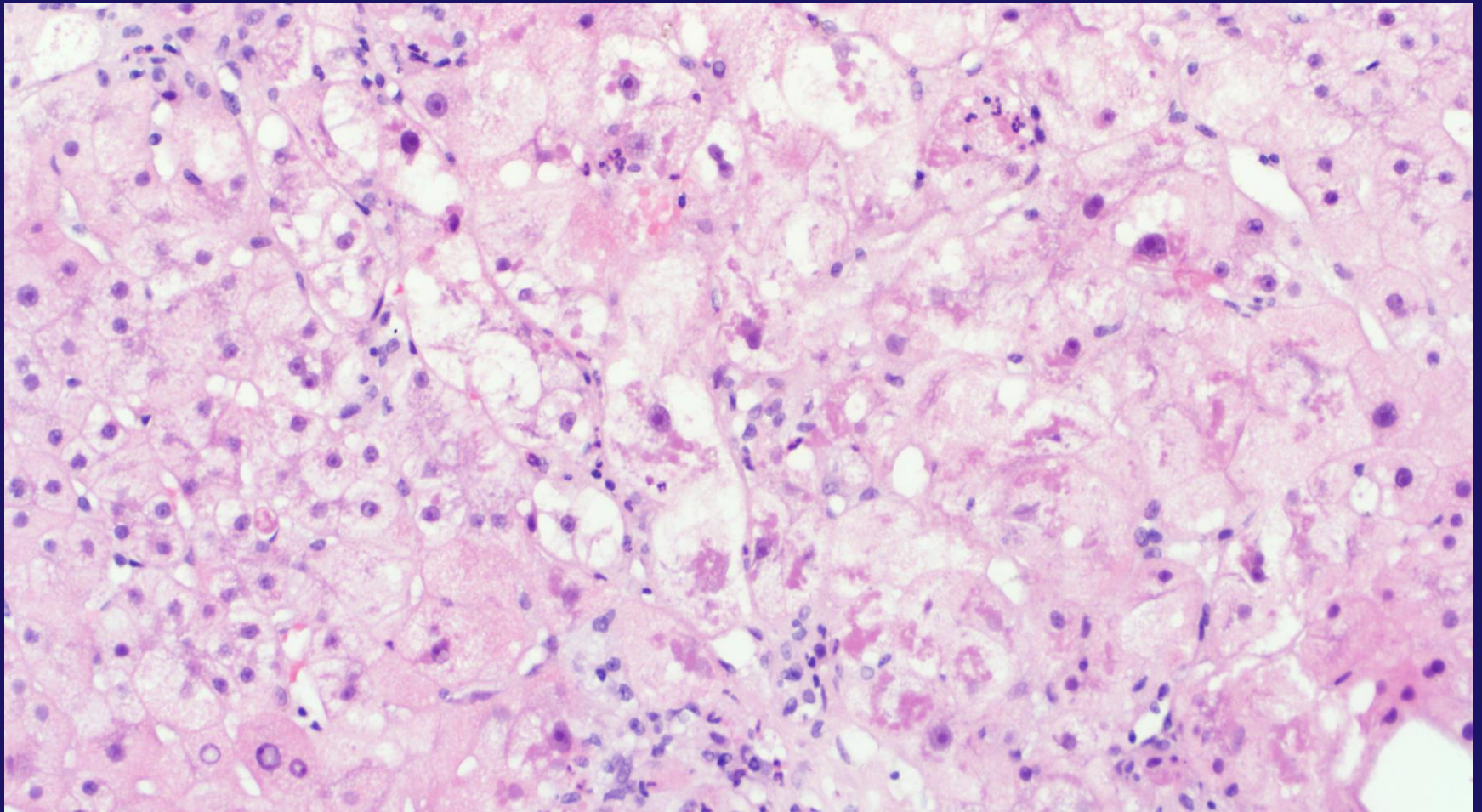
- Typical steatohepatitis features regress with progression of fibrosis and may be lost with cirrhosis
- Many cases labeled as cryptogenic cirrhosis; since this population has a high incidence of type 2 DM, NASH is considered to be the most likely etiology
- Rule out other etiologies and correlate with NASH risk factors

Drug Induced Steatohepatitis

- Histologic changes identical to NASH have been identified in patients without NASH risk factors exposed to certain drugs

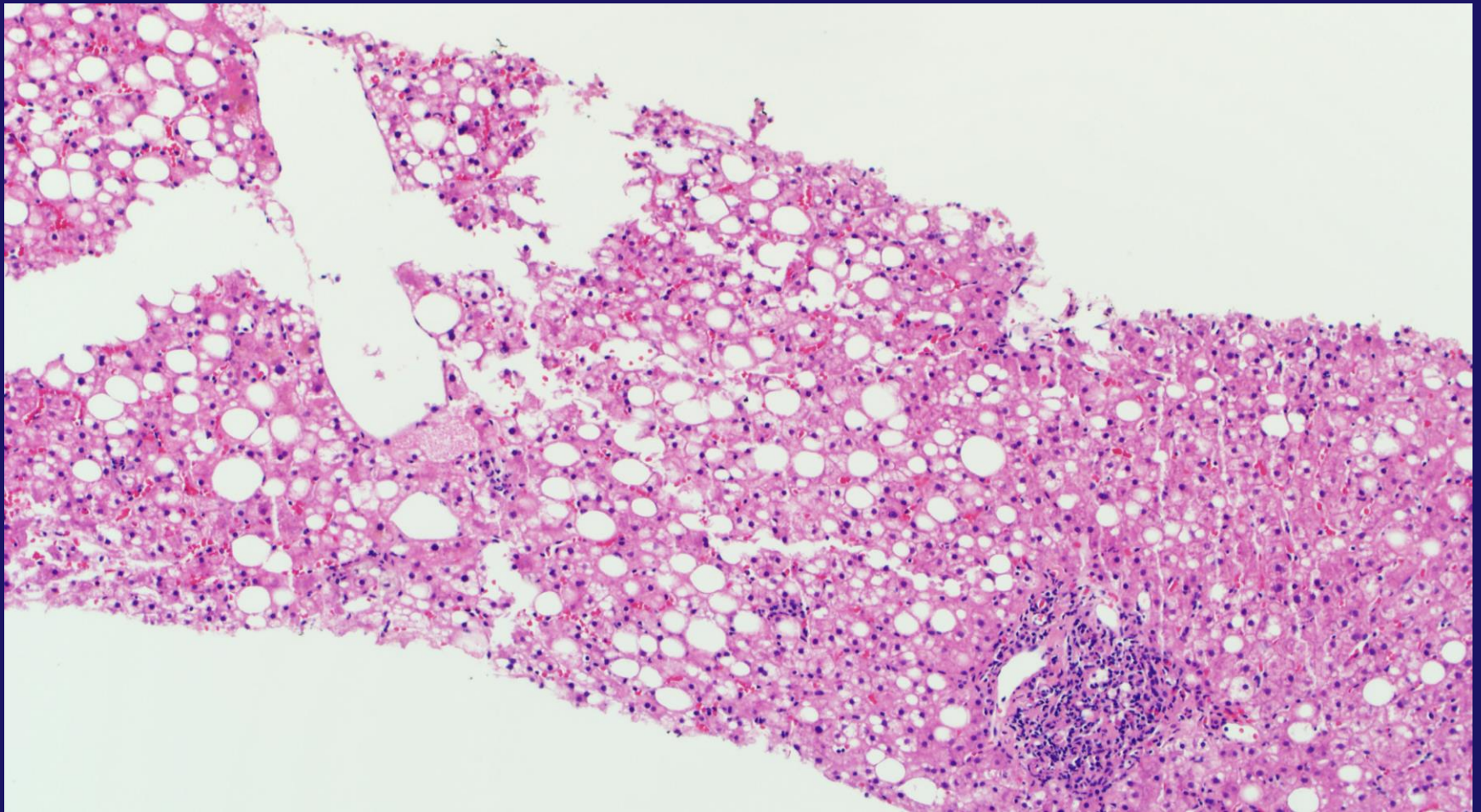
Definite Association	Possible Association
Amiodarone	Tamoxifen
Irinotecan	Steroids
Methotrexate	Estrogen
Perhexiline Maleate/Diethylaminoethoxyh exesterol	Diethylstilbestrol

Amiodarone Toxicity



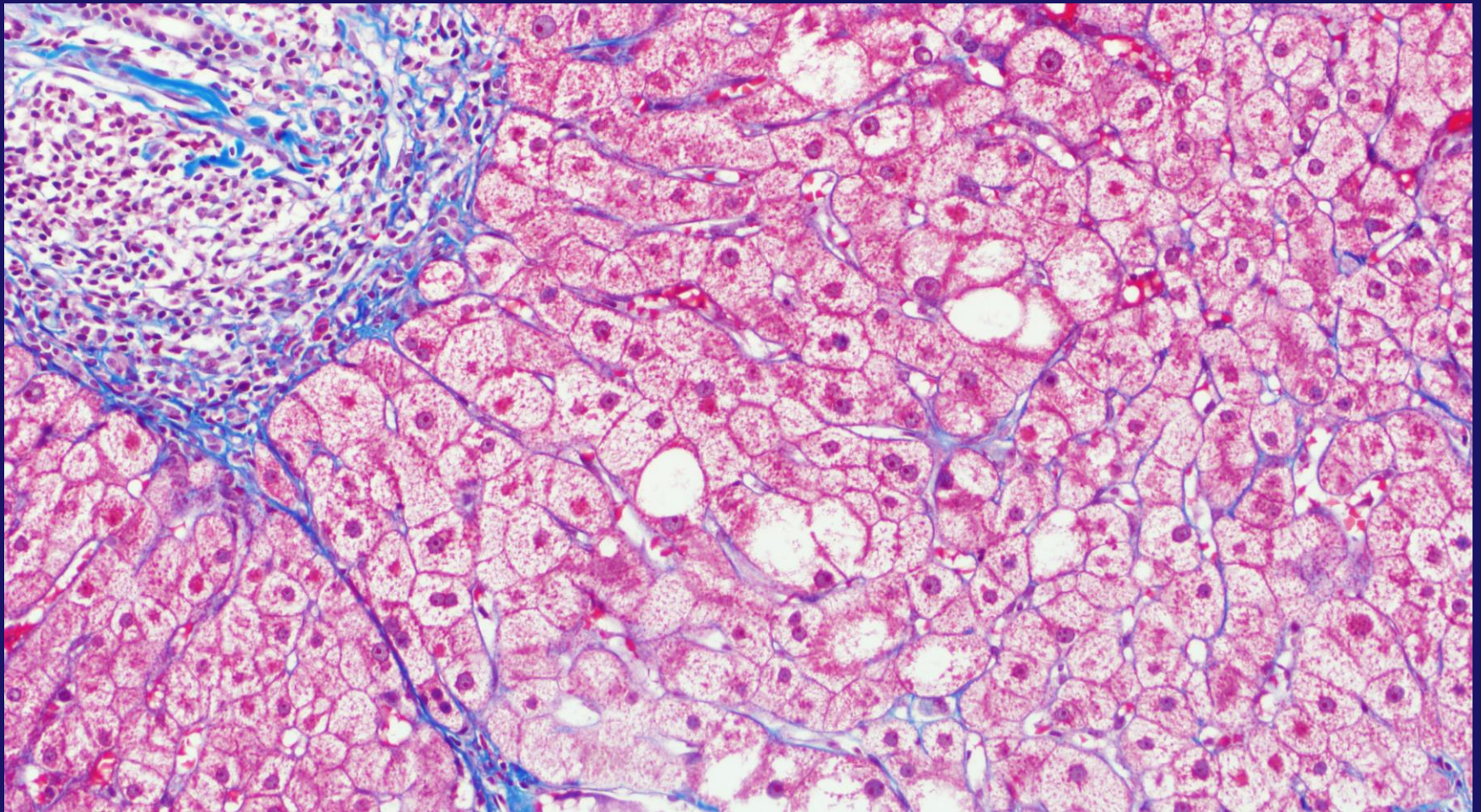
Gill R. M. and Kakar S. Non-alcoholic steatohepatitis, an update on diagnostic challenges, *Surgical Pathology Clinics*, Volume 6, Issue 2 , Pages 227-257, June 2013), adapted with permission from Elsevier.

Methotrexate



Gill R. M. and Kakar S. Non-alcoholic steatohepatitis, an update on diagnostic challenges, *Surgical Pathology Clinics*, Volume 6, Issue 2 , Pages 227-257, June 2013), adapted with permission from Elsevier.

Methotrexate with Portal Fibrosis

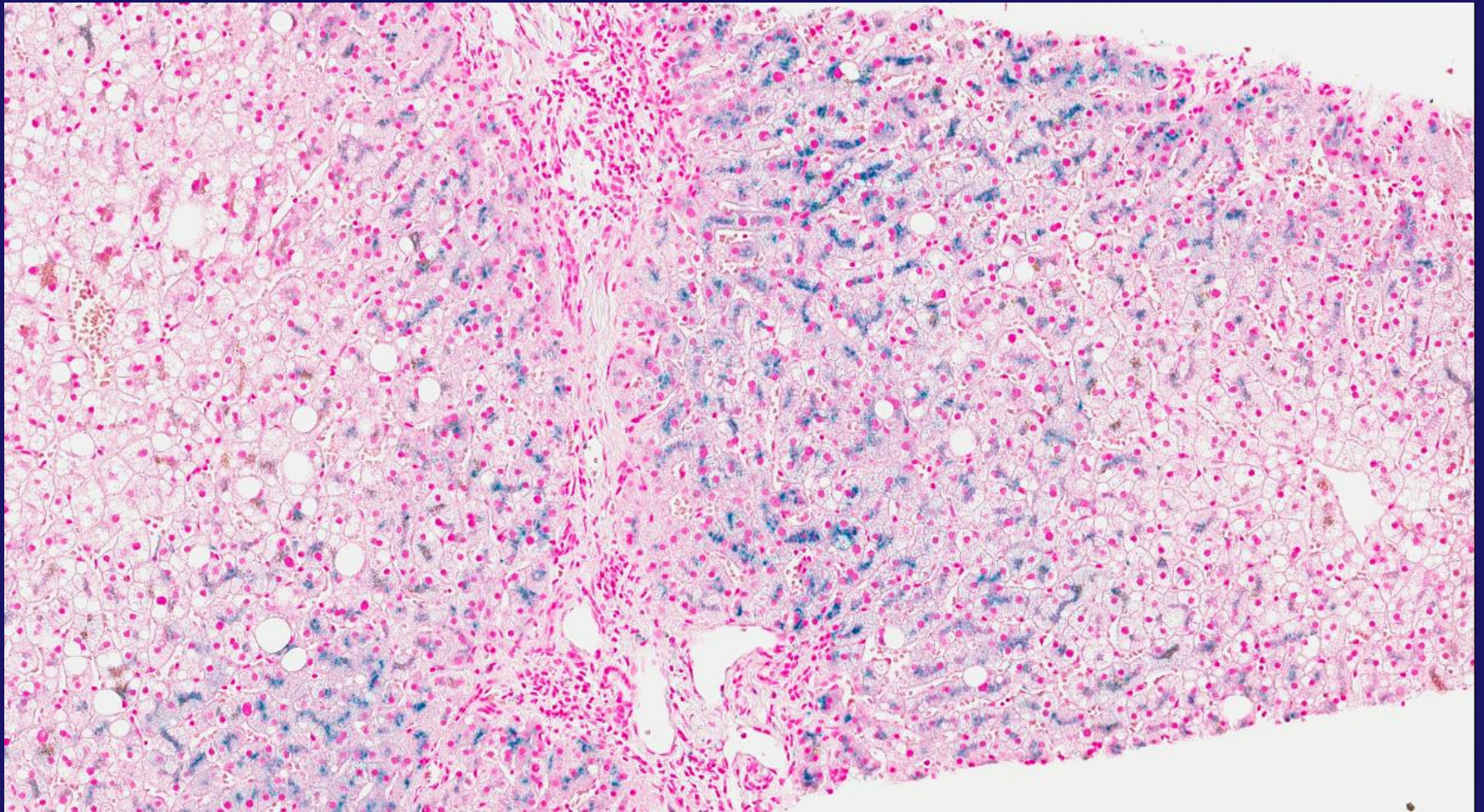


Gill R. M. and Kakar S. Non-alcoholic steatohepatitis, an update on diagnostic challenges, *Surgical Pathology Clinics*, Volume 6, Issue 2 , Pages 227-257, June 2013), adapted with permission from Elsevier.

Hereditary Hemochromatosis

- A mild to moderate hepatocyte siderosis (generally nonzonal) and/or Kupffer cell siderosis is seen in ~20% of NAFLD patients
- Serum ferritin is an acute phase reactant that is commonly increased in NAFLD patients
- Increased iron saturation would more strongly suggest hereditary hemochromatosis
- C282Y *HFE* mutation in an established NASH patient may warrant biopsy to evaluate iron overload

Periportal Siderosis in HH

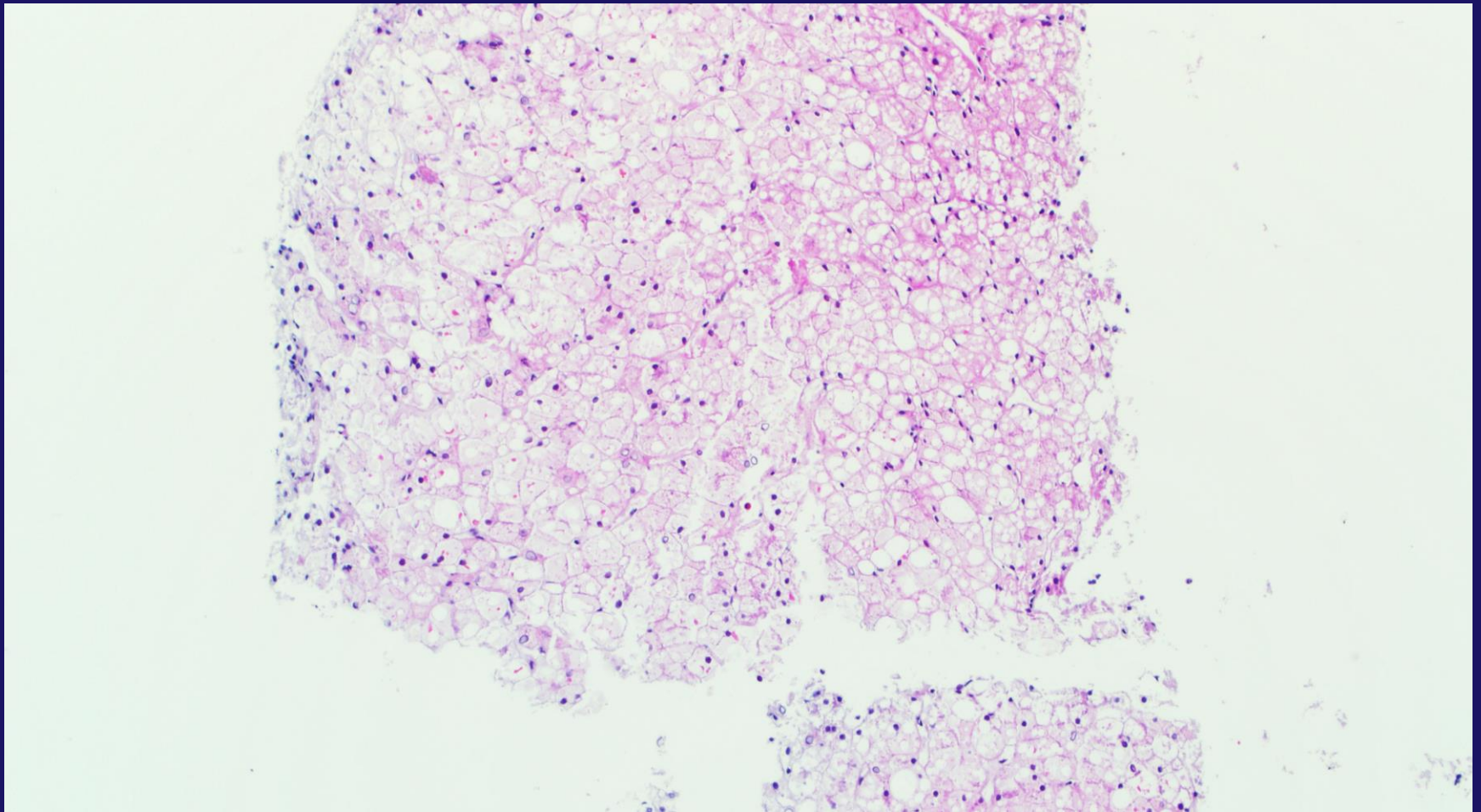


Gill R. M. and Kakar S. Non-alcoholic steatohepatitis, an update on diagnostic challenges, *Surgical Pathology Clinics*, Volume 6, Issue 2, Pages 227-257, June 2013), adapted with permission from Elsevier.

Metabolic Disorders

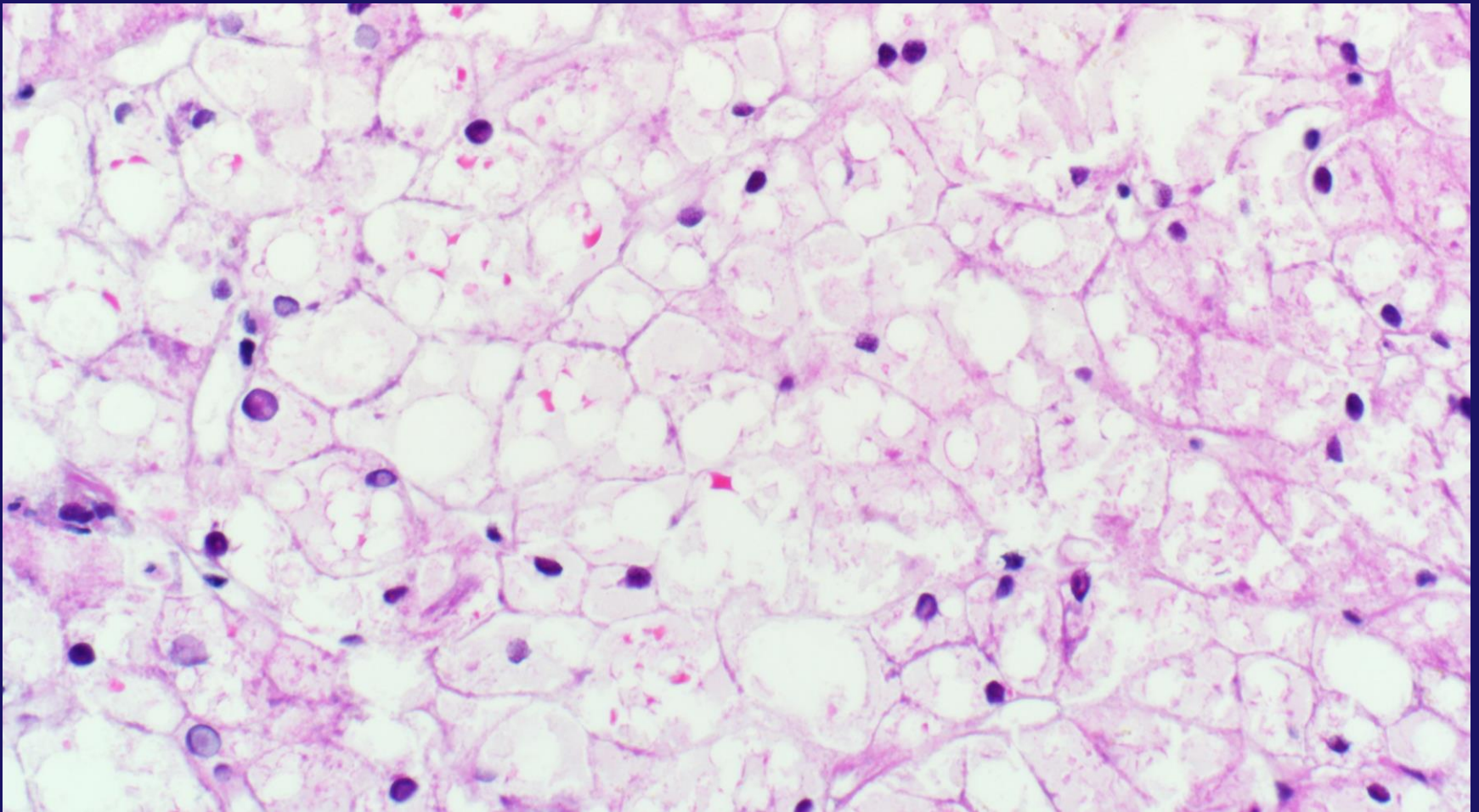
- **Glycogenic hepatopathy**
 - Type 1 DM with poor glycemic control
 - Glycogenosis, minimal fat, and abundant megamitochondria
- **Diabetic hepatosclerosis**
 - Non-zonal perisinusoidal fibrosis and BM deposition in patients with long standing insulin dependent DM, minimal steatosis, no ballooning
- **Wilson disease**
 - Steatosis (non-zonal), glycogenated nuclei, Mallory hyaline, swollen hepatocytes, portal inflammation and fibrosis

Glycogenic Hepatopathy



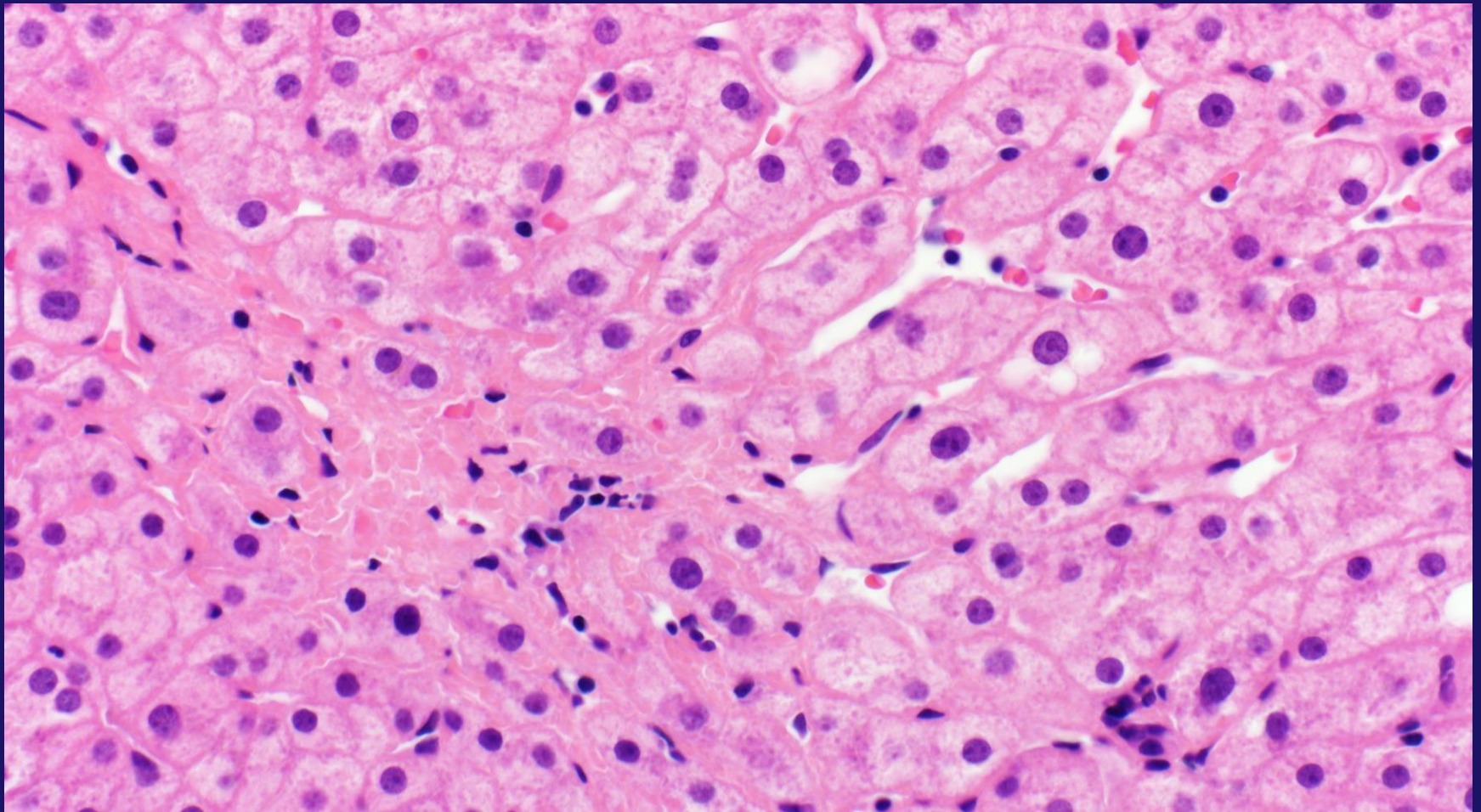
Gill R. M. and Kakar S. Non-alcoholic steatohepatitis, an update on diagnostic challenges, *Surgical Pathology Clinics*, Volume 6, Issue 2 , Pages 227-257, June 2013), adapted with permission from Elsevier.

Glycogenic Hepatopathy



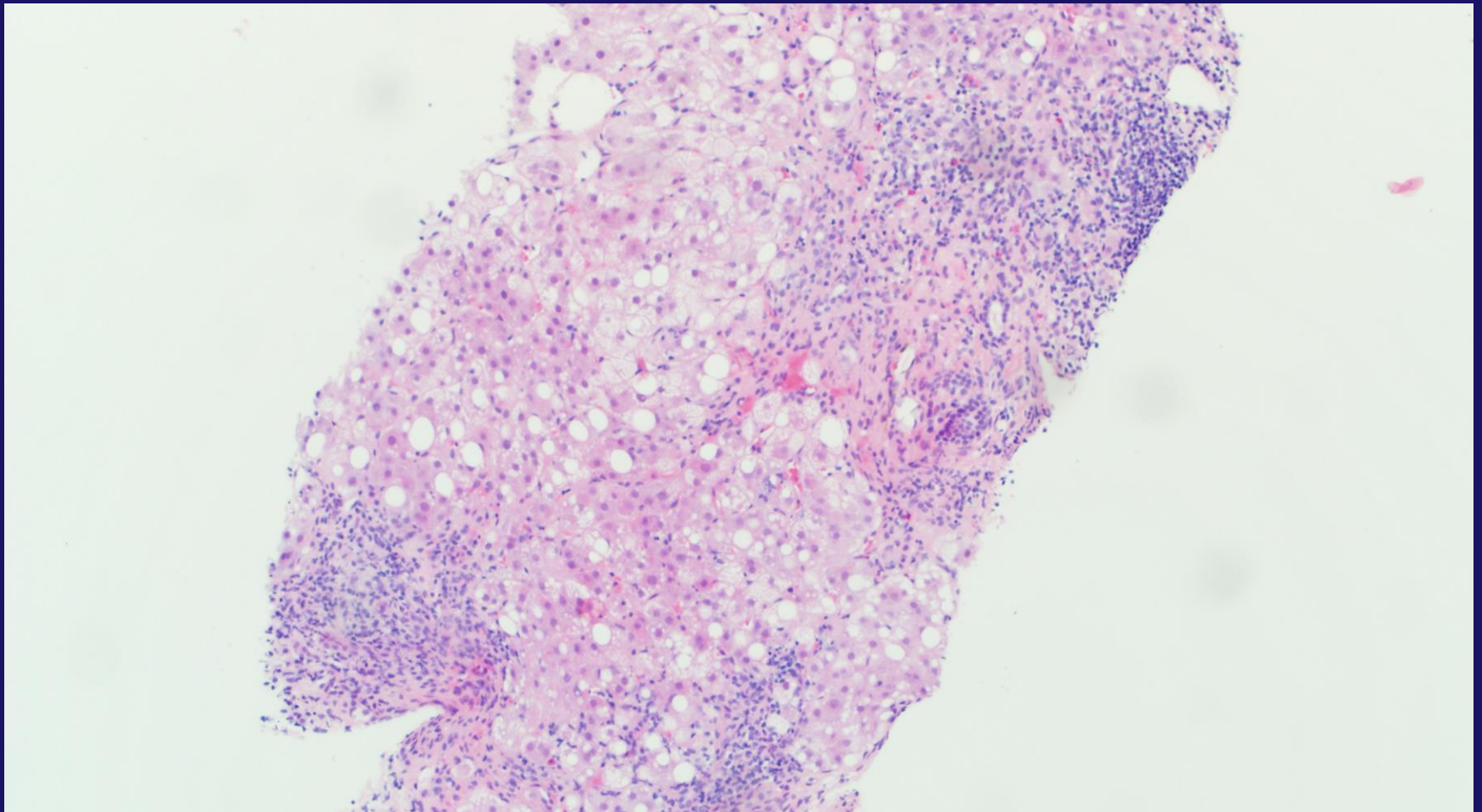
Gill R. M. and Kakar S. Non-alcoholic steatohepatitis, an update on diagnostic challenges, *Surgical Pathology Clinics*, Volume 6, Issue 2 , Pages 227-257, June 2013), adapted with permission from Elsevier.

Diabetic Hepatosclerosis



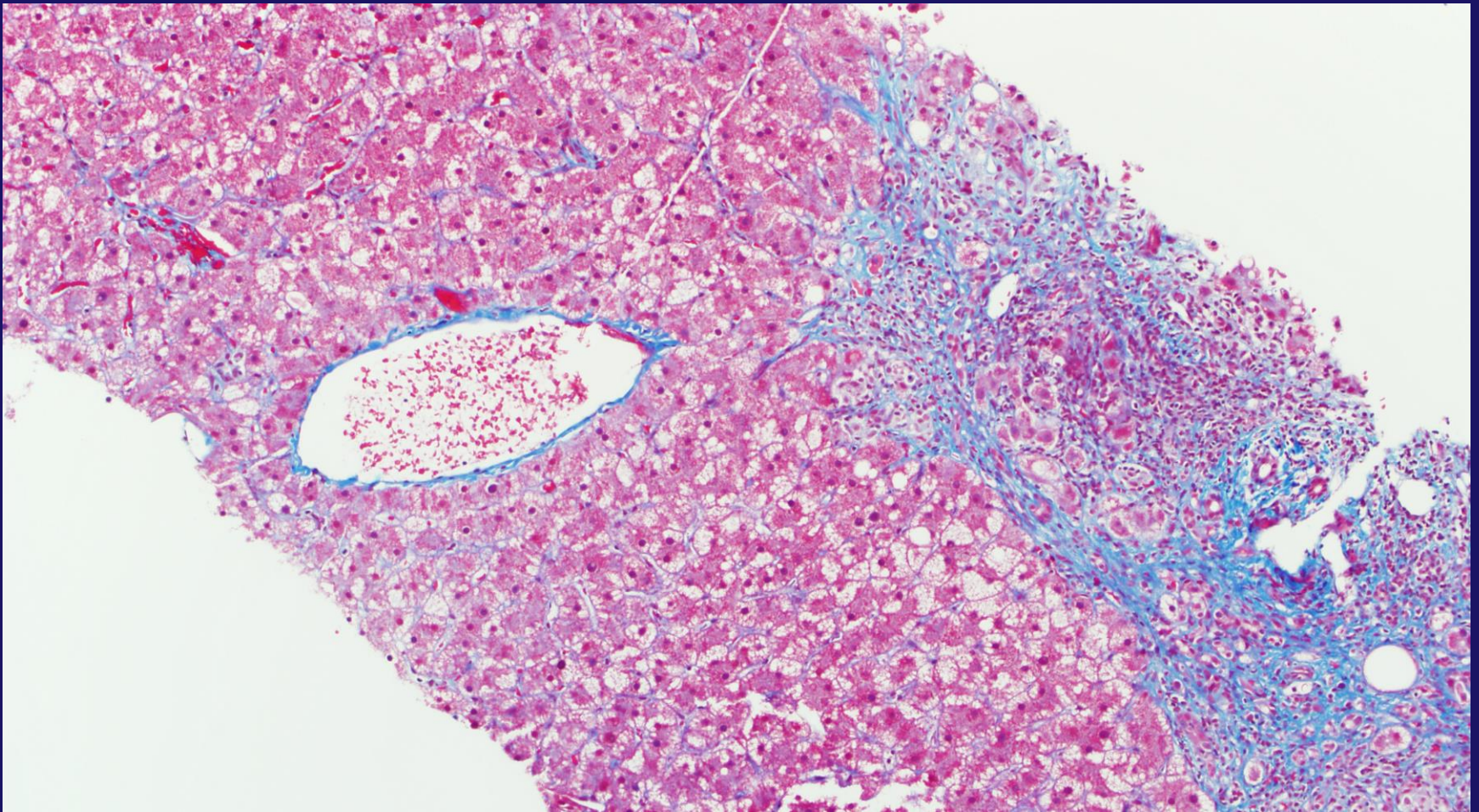
Gill R. M. and Kakar S. Non-alcoholic steatohepatitis, an update on diagnostic challenges, *Surgical Pathology Clinics*, Volume 6, Issue 2 , Pages 227-257, June 2013), adapted with permission from Elsevier.

Steatosis and Portal Inflammation in Wilson Disease



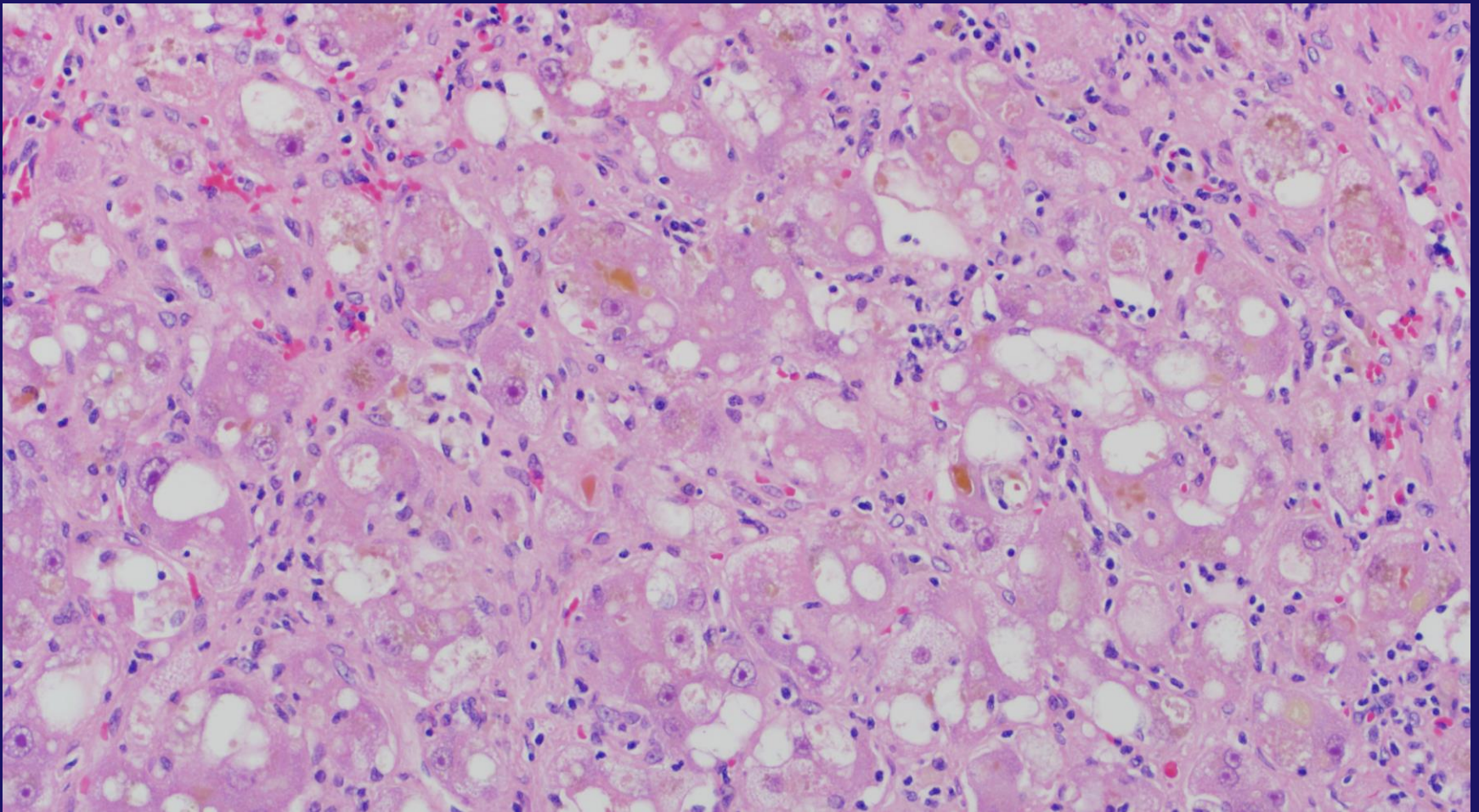
Gill R. M. and Kakar S. Non-alcoholic steatohepatitis, an update on diagnostic challenges, *Surgical Pathology Clinics*, Volume 6, Issue 2 , Pages 227-257, June 2013), adapted with permission from Elsevier.

Periportal Fibrosis in Wilson Disease



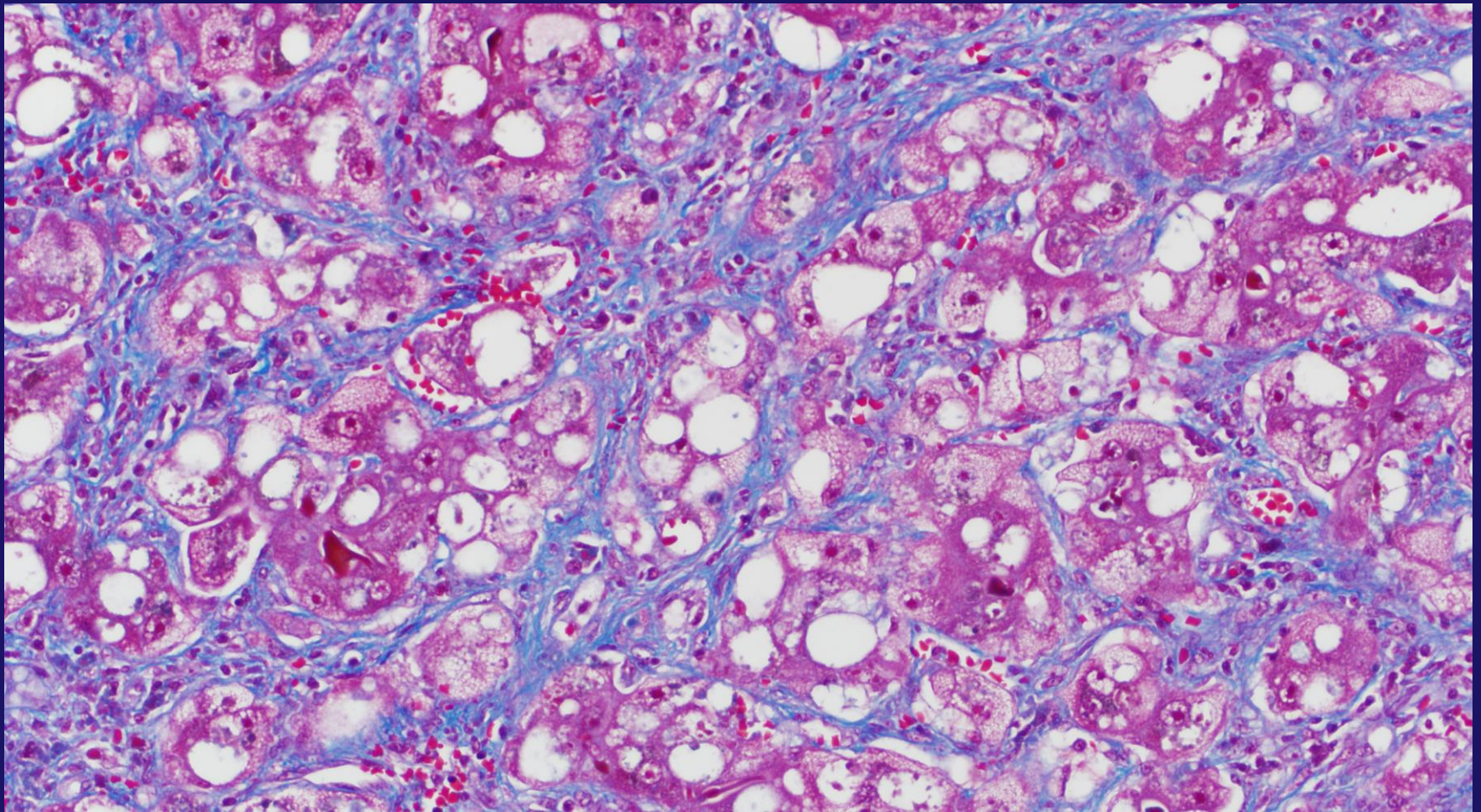
Gill R. M. and Kakar S. Non-alcoholic steatohepatitis, an update on diagnostic challenges, *Surgical Pathology Clinics*, Volume 6, Issue 2 , Pages 227-257, June 2013), adapted with permission from Elsevier.

Wilson Disease with Swollen Hepatocytes



Gill R. M. and Kakar S. Non-alcoholic steatohepatitis, an update on diagnostic challenges, *Surgical Pathology Clinics*, Volume 6, Issue 2 , Pages 227-257, June 2013), adapted with permission from Elsevier.

Wilson Disease with Pericellular Fibrosis

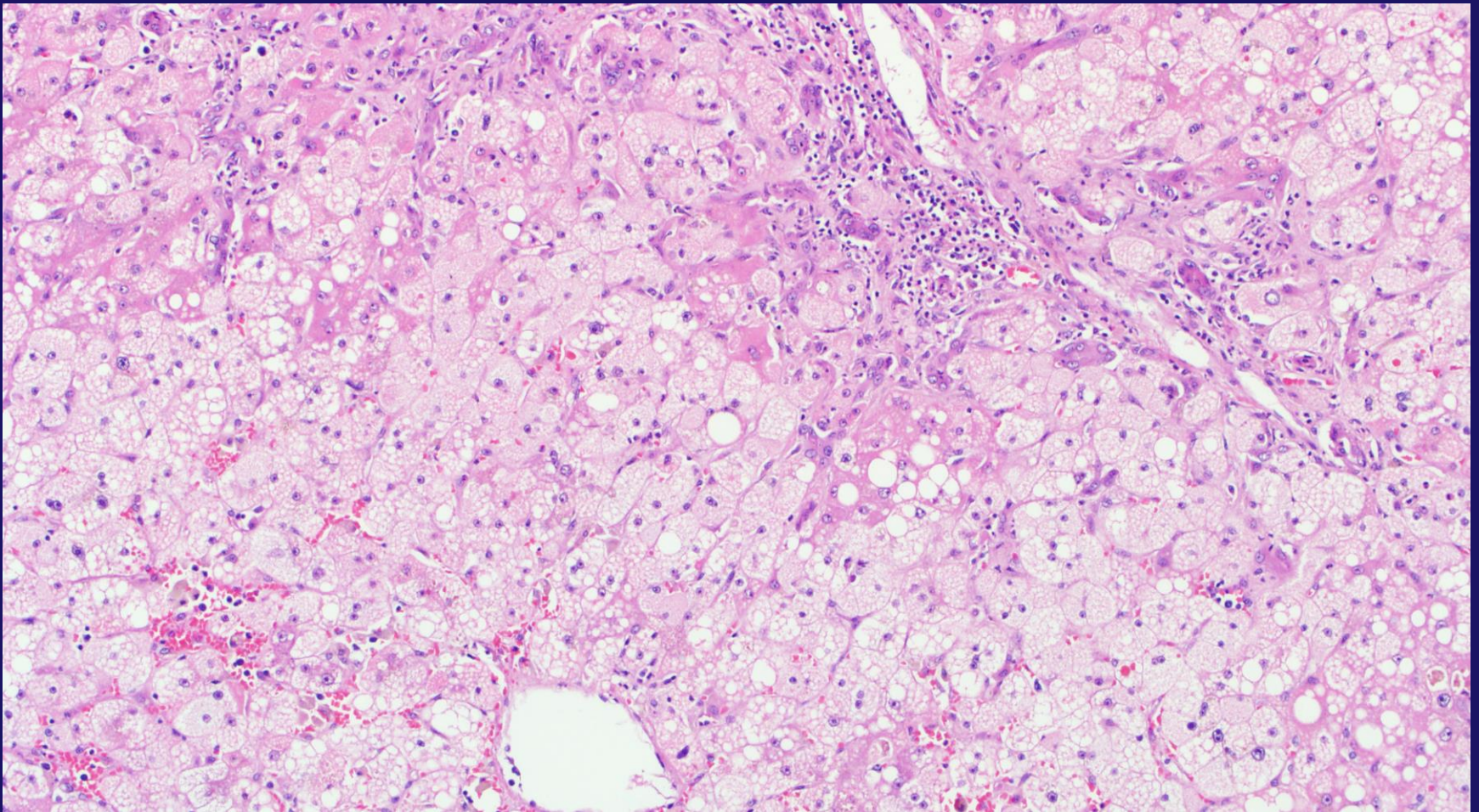


Gill R. M. and Kakar S. Non-alcoholic steatohepatitis, an update on diagnostic challenges, *Surgical Pathology Clinics*, Volume 6, Issue 2 , Pages 227-257, June 2013), adapted with permission from Elsevier.

Microvesicular Steatosis

- Pure microvesicular steatosis does not occur in NASH and indicates severe mitochondrial injury
- Reye syndrome, acute fatty liver of pregnancy, alcoholic foamy liver degeneration, drug (cocaine, tetracycline, valproic acid, zidovudine), and rare genetic disorders.
- Many NAFLD cases will have a minor component of microvesicular fat

Diffuse Microvesicular Steatosis

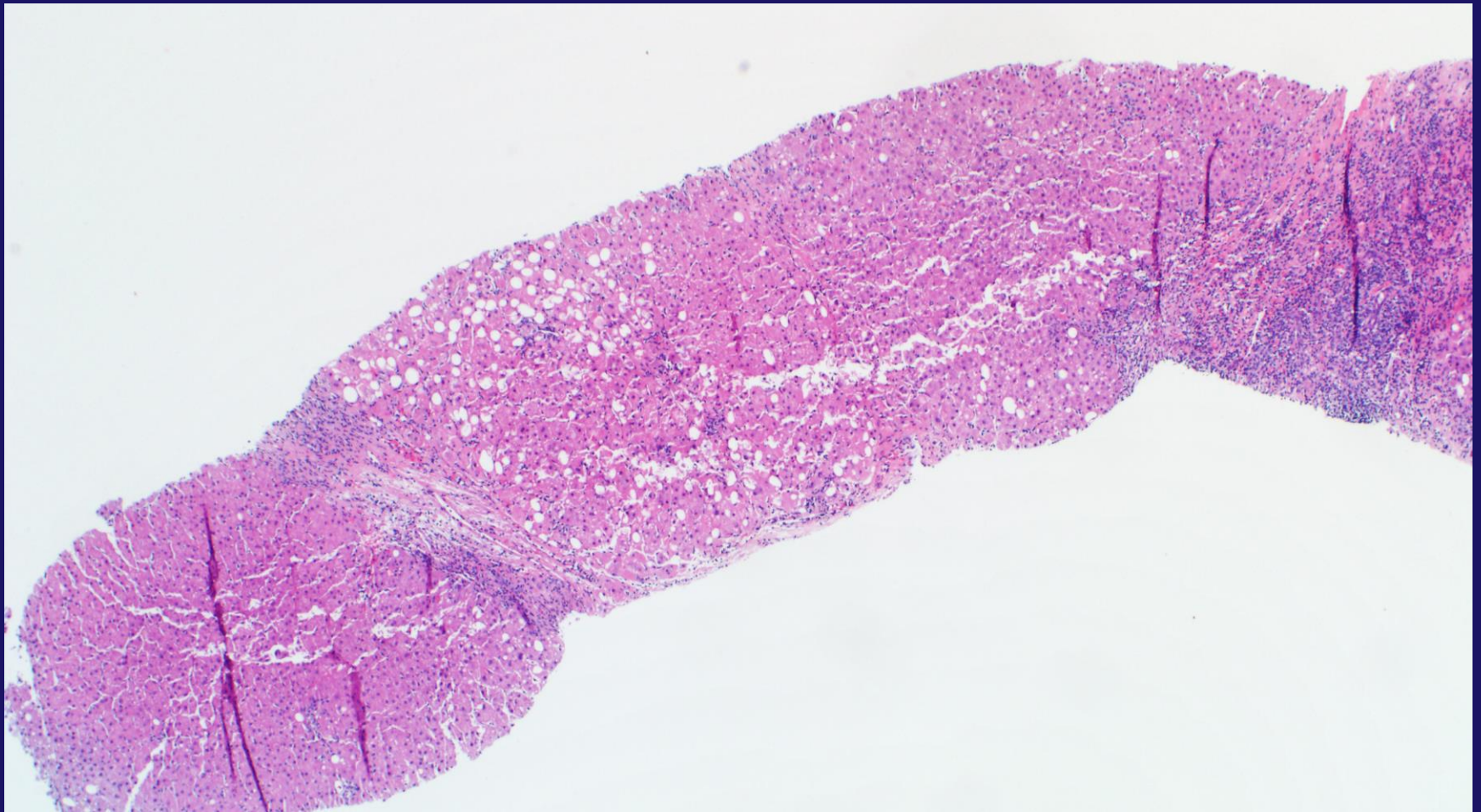


Gill R. M. and Kakar S. Non-alcoholic steatohepatitis, an update on diagnostic challenges, *Surgical Pathology Clinics*, Volume 6, Issue 2 , Pages 227-257, June 2013), adapted with permission from Elsevier.

More than Mild Portal Inflammation

- NASH portal inflammation is typically mild
- Prominent portal inflammation raises consideration of other causes (HBV, HCV, AIH, PBC, Wilson disease)
- If other etiologies are excluded, this can be considered NASH with prominent portal inflammation
- May be associated with a higher degree of fibrosis

More than Mild Portal Inflammation

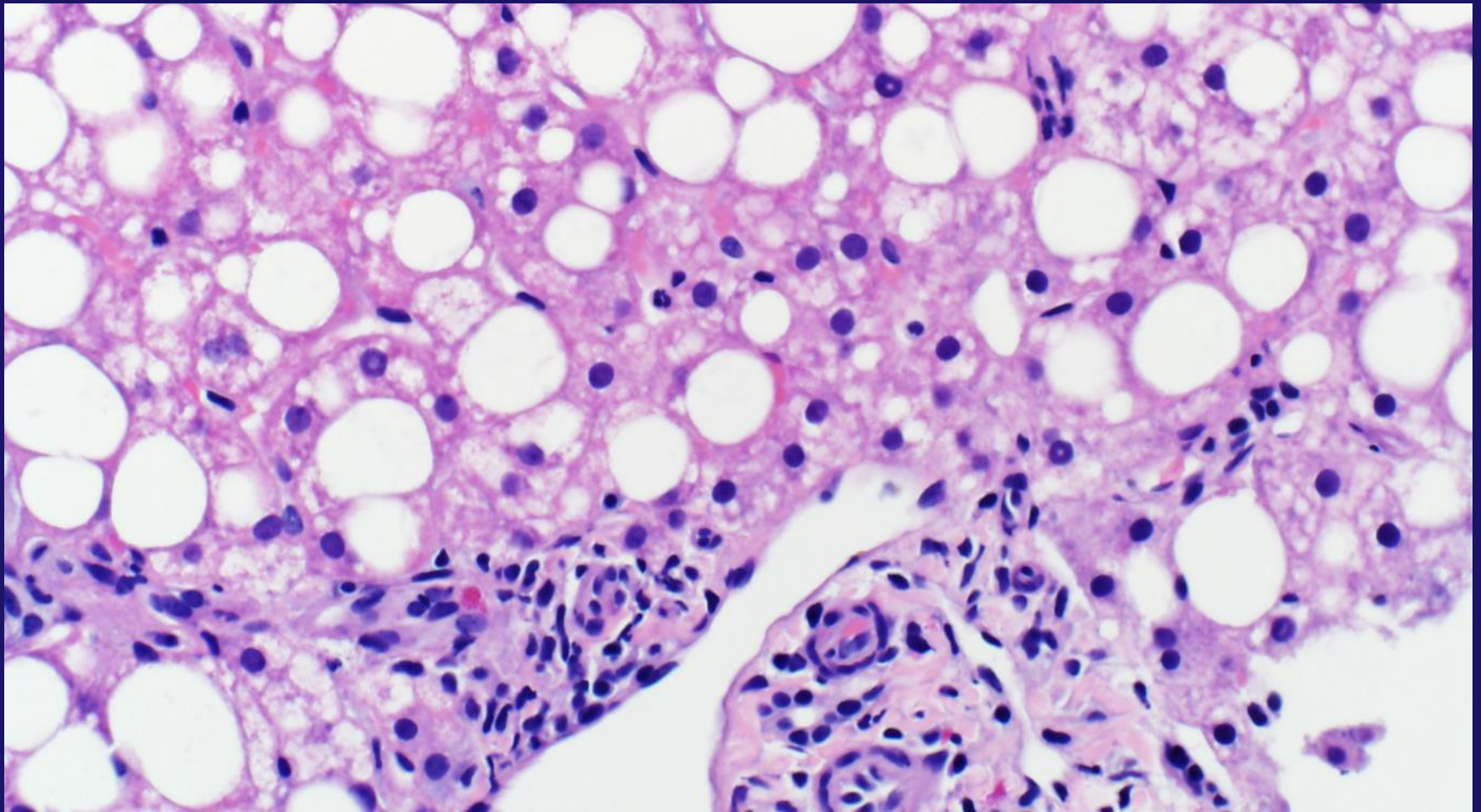


Gill R. M. and Kakar S. Non-alcoholic steatohepatitis, an update on diagnostic challenges, *Surgical Pathology Clinics*, Volume 6, Issue 2 , Pages 227-257, June 2013), adapted with permission from Elsevier.

Pediatric NASH

- NASH cirrhosis seen as young as 8 years of age
- AST/ALT screening has been considered for obese children starting at age 10
- Type 1 pediatric NASH: Identical to adult type NASH
- Type 2 pediatric NASH: Severe panacinar steatosis, no ballooned hepatocytes, early portal based fibrosis (stage 1C)
- Children younger than age 2 with fatty liver should be evaluated for rare genetic disorders

Severe Pan-acinar Steatosis



Gill R. M. and Kakar S. Non-alcoholic steatohepatitis, an update on diagnostic challenges, *Surgical Pathology Clinics*, Volume 6, Issue 2 , Pages 227-257, June 2013), adapted with permission from Elsevier.

**NASH CLINICAL RESEARCH
NETWORK (CRN)**

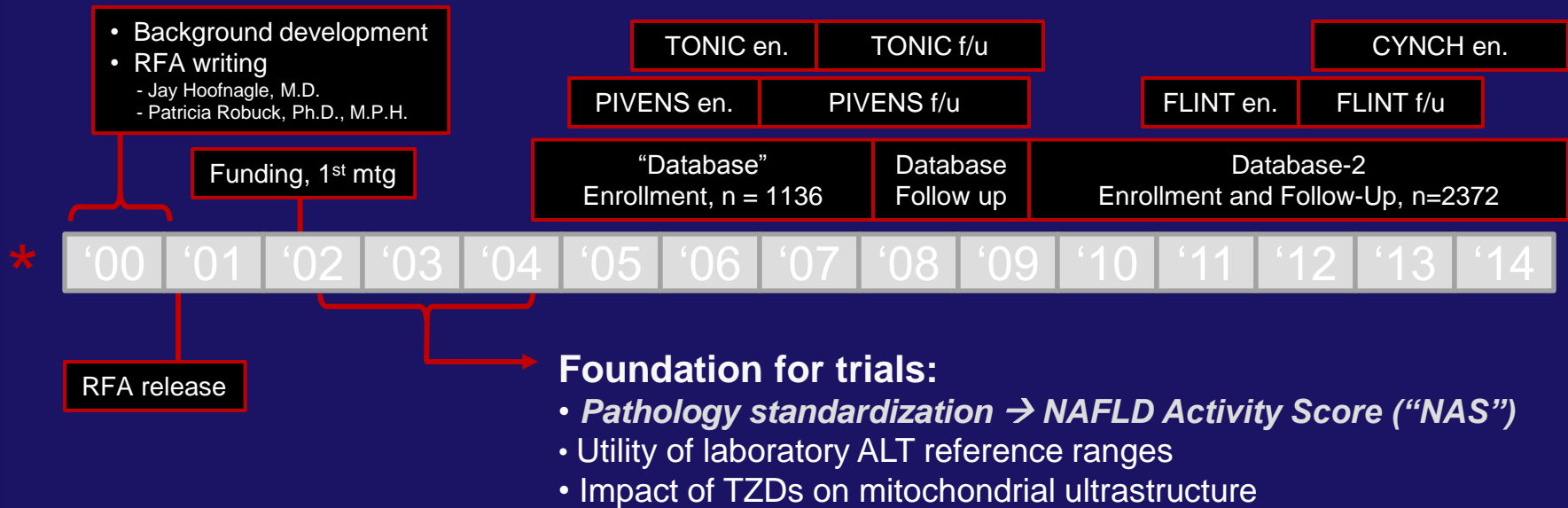
NIDDK Workshop on Fatty Liver Disease 1998

- No good estimates of disease prevalence or severity (but suspected that this was a big problem)
- Little information on the natural history
- No non-invasive diagnostic tests
- No standard methods for evaluating liver biopsy
- No approved therapies

NASH Clinical Research Network

- Sponsored by the National Institute of Diabetes and Digestive and Kidney Diseases
- 18 Participating Academic Clinical Centers (8 Adult, 10 Pediatric), 1 Data Coordination Center, and the NIDDK Project Scientists
- Established to focus on the etiology, contributing factors, natural history, complications, and therapy of nonalcoholic steatohepatitis

NASH CRN Studies



Primary Goal of the Pathology Committee

Create a scoring system for evaluating liver biopsies that could be used for clinical trials and natural history studies

Design and Validation of a Histological Scoring System for Nonalcoholic Fatty Liver Disease

David E. Kleiner,¹ Elizabeth M. Brunt,² Mark Van Natta,³ Cynthia Behling,⁴ Melissa J. Contos,⁵ Oscar W. Cummings,⁶ Linda D. Ferrell,⁷ Yao-Chang Liu,⁸ Michael S. Torbenson,⁹ Aynur Unalp-Arida,³ Matthew Yeh,¹⁰ Arthur J. McCullough,¹¹ and Arun J. Sanyal¹² for the Nonalcoholic Steatohepatitis Clinical Research Network¹³

- H&E and Trichrome only
- 9 pathologists, 2 independent reads
- Scoring system included features for grading/staging plus other findings
- Defined an “**Activity Score**” for use in clinical trials to objectively measure composite histologic change
- Score based on results of multivariable analysis
- Excluded fibrosis to avoid mixing “stage” with “grade”

NAFLD Activity Score (NAS) = Steatosis (0-3) + Lob. Inf. (0-3) + Ballooning (0-2)

Hepatology 41: 1313;
2005

Courtesy of Dr. David Kleiner, NIH

ORIGINAL ARTICLE

Pioglitazone, Vitamin E, or Placebo
for Nonalcoholic Steatohepatitis

N Engl J Med 2010;362:1675-85.

**Effect of Vitamin E or Metformin for Treatment
of Nonalcoholic Fatty Liver Disease
in Children and Adolescents**

The TONIC Randomized Controlled Trial

JAMA, April 27, 2011—Vol 305, No. 16 **1659**

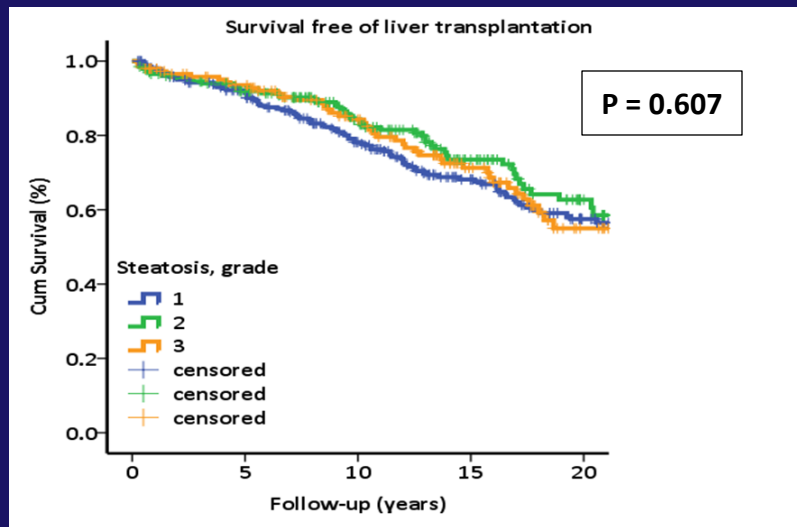
**Farnesoid X nuclear receptor ligand obeticholic acid for
non-cirrhotic, non-alcoholic steatohepatitis (FLINT):
a multicentre, randomised, placebo-controlled trial**

www.thelancet.com Published online November 7, 2014 [http://dx.doi.org/10.1016/S0140-6736\(14\)61933-4](http://dx.doi.org/10.1016/S0140-6736(14)61933-4)

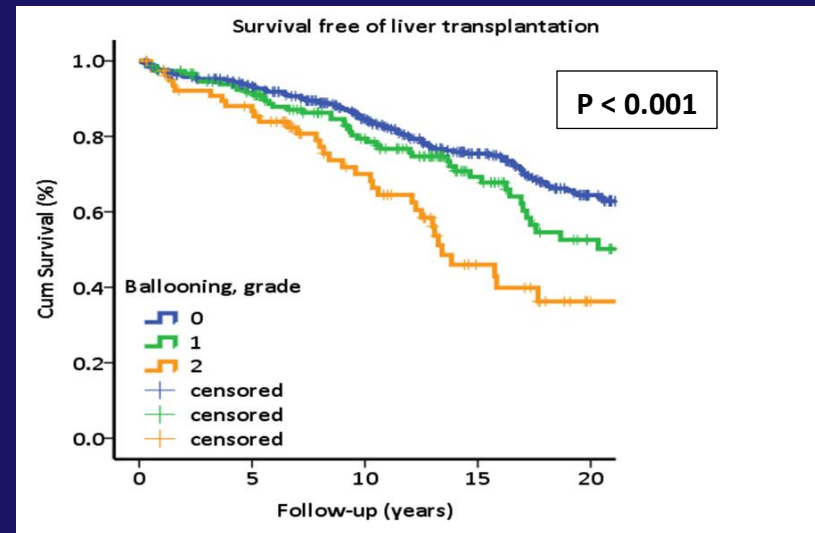
Ballooning is Associated with Long Term Survival, Whereas Steatosis is Not

Angulo et al., Gastroenterology 149: 389; 2015

Steatosis



Ballooning



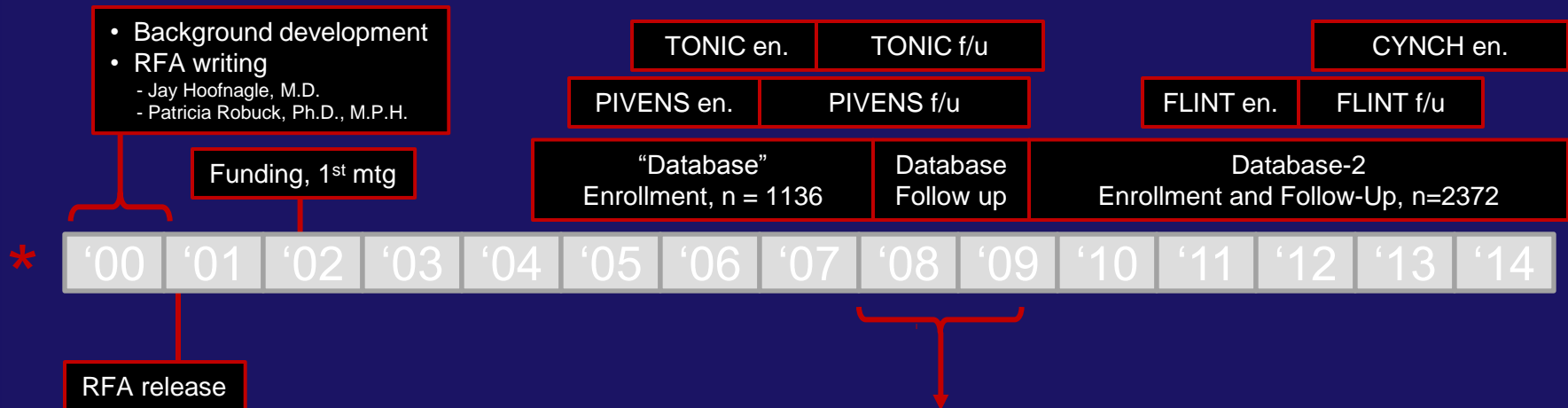
Problem

Steatosis accounts for more weight
in the NAS than Ballooning

Possible Solutions

- Drop Steatosis from the score
- Extend the Ballooning Scale

NASH CRN Studies



Pathology committee discussions on better characterization of ballooning

Defined two new concepts for prospective evaluation:

- Classical vs Non-Classical Ballooning
- Severe vs Not Severe Ballooning

New definitions implemented with the first case in DB2

Classical vs Non-Classical

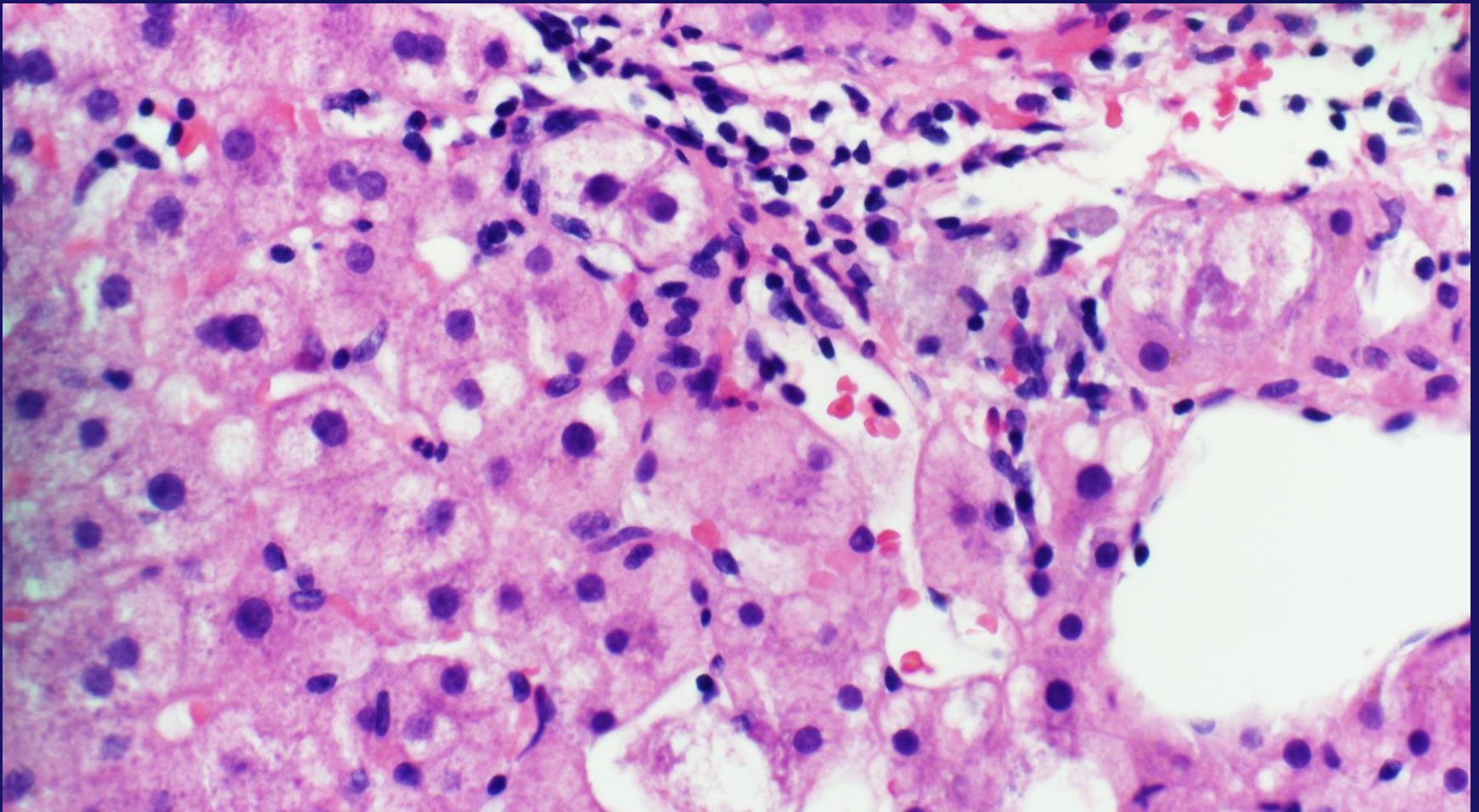
- **Classical ballooning**

- Enlarged (>1.5x normal)
- Cytoplasmic clearing
- Cytoplasmic clumping
- May have Mallory-Denk bodies

- **Non-Classical ballooning**

- Typically in zone 3, perivenular
- Smaller
- Same cytoplasmic alterations
- Lack Mallory-Denk bodies

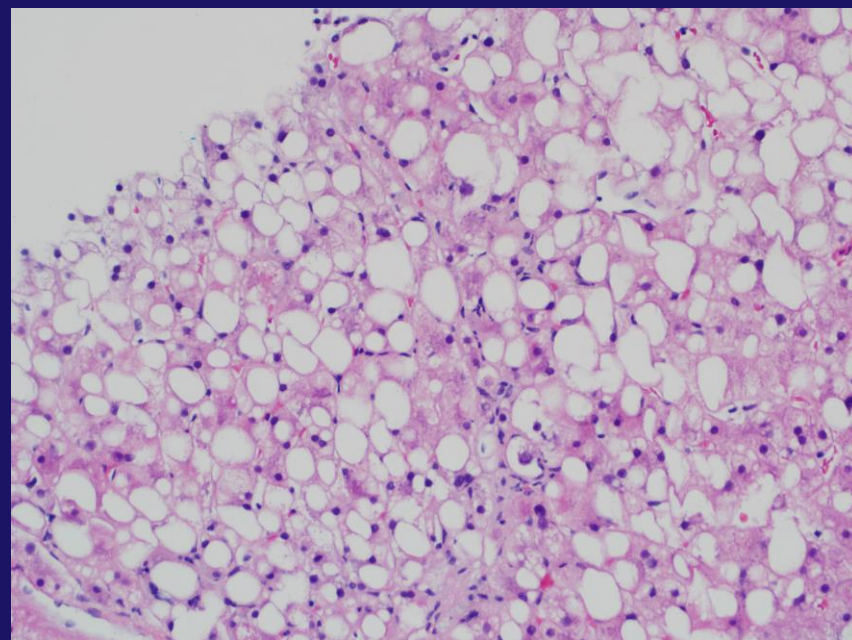
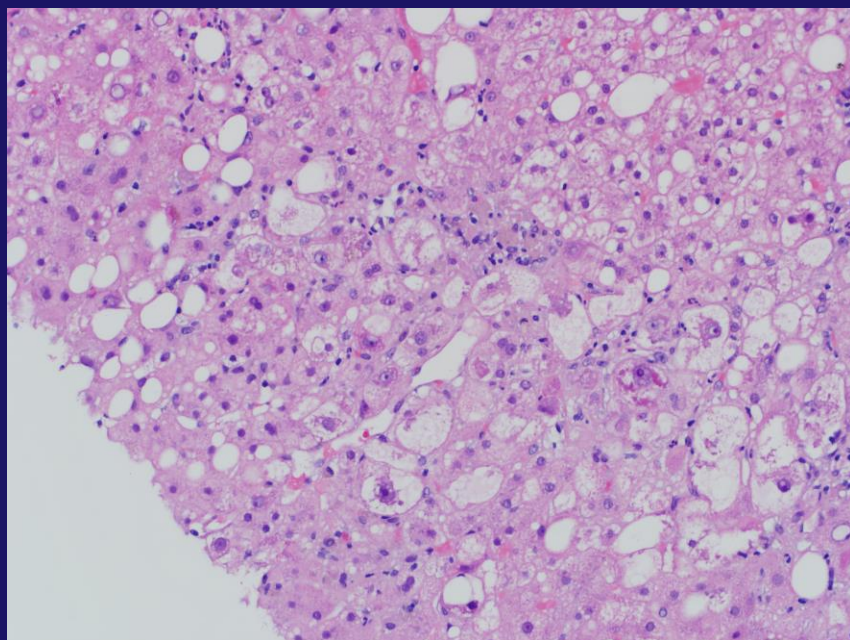
Non-Classic Ballooned Hepatocyte



Gill R. M. and Kakar S. Non-alcoholic steatohepatitis, an update on diagnostic challenges, *Surgical Pathology Clinics*, Volume 6, Issue 2 , Pages 227-257, June 2013), adapted with permission from Elsevier.

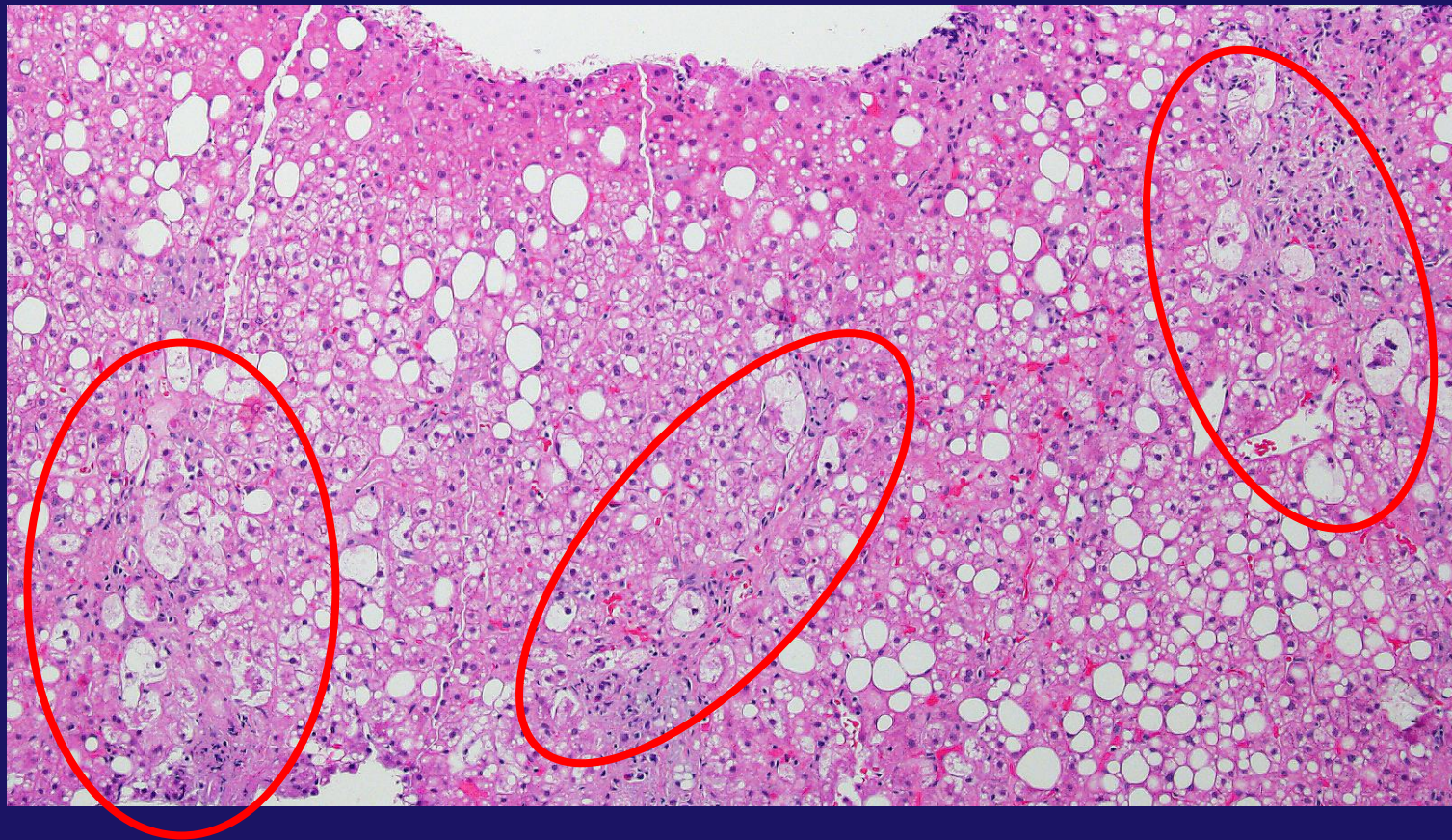Classical vs. Non-Classical HB

Substantial agreement (weight kappa 0.76 (95% CI=0.64, 0.88))



Severe Hepatocyte Balloons

- Several foci of classic hepatocyte balloons immediately apparent at low magnification (4x)



Courtesy of Dr. David Kleiner, NIH

157

Extending the Ballooning Score Beyond 2: A Proposal for a New Balloon Score

David E. Kleiner¹, Elizabeth M. Brunt³, Patricia H. Belt², Cynthia A. Behling⁴, Ryan M. Gill⁵, Cynthia D. Guy⁶, Brent A. Neuschwander-Tetri⁷, Arun J. Sanyal⁸, Mark L. Van Natta²; ¹Laboratory of Pathology, National Cancer Institute, Bethesda, MD; ²Johns Hopkins School of Public Health, Baltimore, MD; ³Washington University, St. Louis, MO; ⁴Sharp Memorial Hospital, San Diego, CA; ⁵University of California, San Francisco, San Francisco, CA; ⁶Duke University Medical Center, Durham, NC; ⁷Saint Louis University, St. Louis, MO; ⁸Virginia Commonwealth University, Richmond, VA

- 1226 biopsies
- Demographic, anthropometric, laboratory data within 6 months of biopsy extracted

Proposed Modified Hepatocyte Balloon Score

Old Ballooning Score	Classical?	Severe?	New Ballooning Score	Description
0 - None	No	No	0	No ballooning
1 - Few or 2 - Many	No	No	1	Only Non-classical
1- Few	Yes	No	2	Few Classical
2 - Many	Yes	No	3	Many Classical
2 - Many	Yes	Yes	4	Severe, Many Classical

- Reduces effect of many “non-classical” hepatocyte balloons when no classical ballooning seen
- Gives more weight to ballooning
- Better correlation with diagnosis

Highlights presented at AASLD

1. Diagnosis
2. Fibrosis
3. Age and gender associations
4. Diabetes and metabolic syndrome
5. Liver enzymes

Summary and Conclusions

- We have proposed a new ballooning score based on careful morphological characterization of the range of ballooned hepatocytes
- The new balloon score doubles the dynamic range of the current balloon score
- The score shows excellent correlation with clinical disease features, as well as with patient demographics

Acknowledgments

*Writing Group Members

- Pathologists
 - David Kleiner (NCI)
 - Elizabeth Brunt (Wash U)
 - Cynthia Behling (UCSD)
 - Melissa Contos (VCU)
 - Bill Cummings (IU)
 - Ryan M Gill (UCSF)
 - Cynthia Guy (DUKE)
 - Rish Pai (CWRU)
 - Danielle Allende (CWRU)
 - Michael Torbenson (JHU)
 - Matthew Yeh (UW)
- NIDDK Project Scientists
 - Ed Doo
 - Averell Sherker
- Clinical Centers and Principal Investigators
 - CWRU: Art McCullough
 - DUKE: Anna Mae Diehl
 - IU: Naga Chalasani
 - SLU: Brent Neuschwander-Tetri
 - UCSD: Rohit Loomba
 - UCSF: Norah Terrault
 - VMMC: Kris Kowdley
 - VCU: Arun Sanyal
- DCC (JH School of Public Health)
 - James Tonascia
 - Mark Van Natta
 - Pat Belt
 - Laura Wilson

And the many other investigators, research assistants, nurses and patients of the NASH
CRN

