2018 Park City AP Update

Hepatocellular Carcinoma

Histologic variants

Sanjay Kakar, MD
University of California, San Francisco

Outline

- Histologic variants of HCC
- Morphologic and Immunohistochemical pitfalls
- Combined hepatocellular-cholangiocarcinoma

HCC: Histologic variants

WHO 2010 classification	Other variants
• Scirrhous • Fibrolamellar • Sarcomatoid • Lymphocyte-rich	• Steatohepatitic • GCSF-rich • *Cirrhosis-like* • *Clear cell* • *Macrotrabecular-massive*

66/M, 6 cm liver mass
no other known tumor

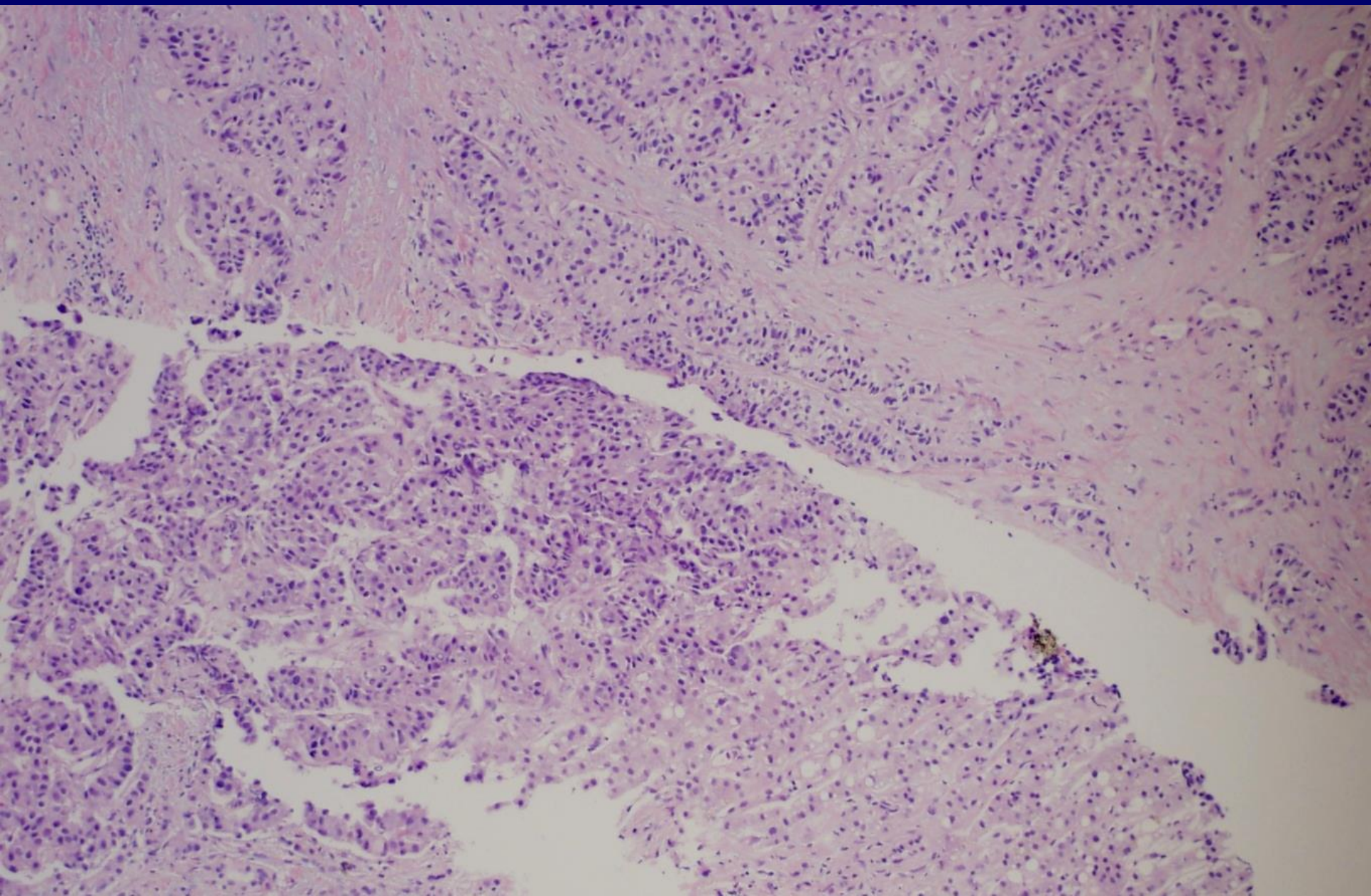

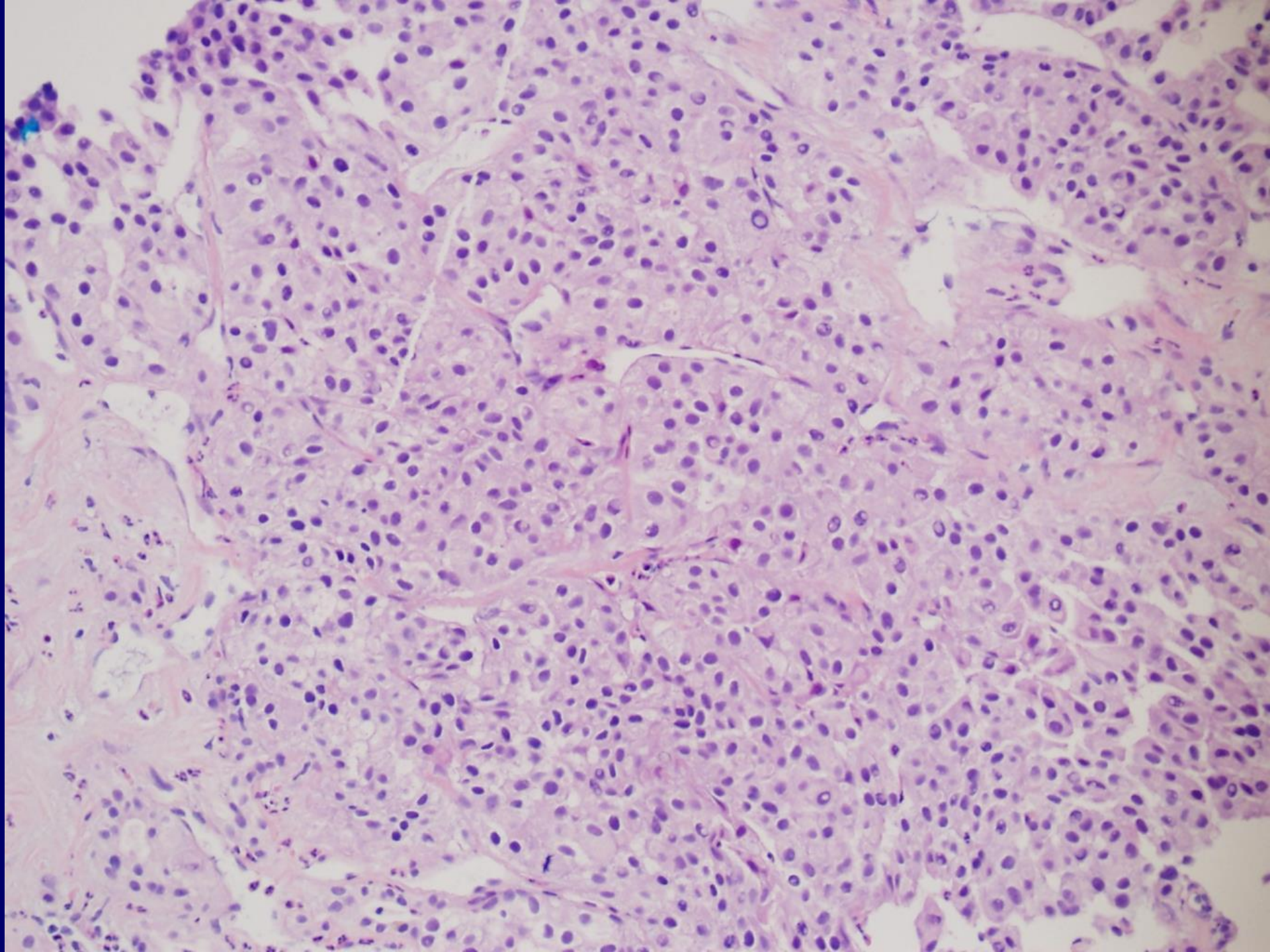

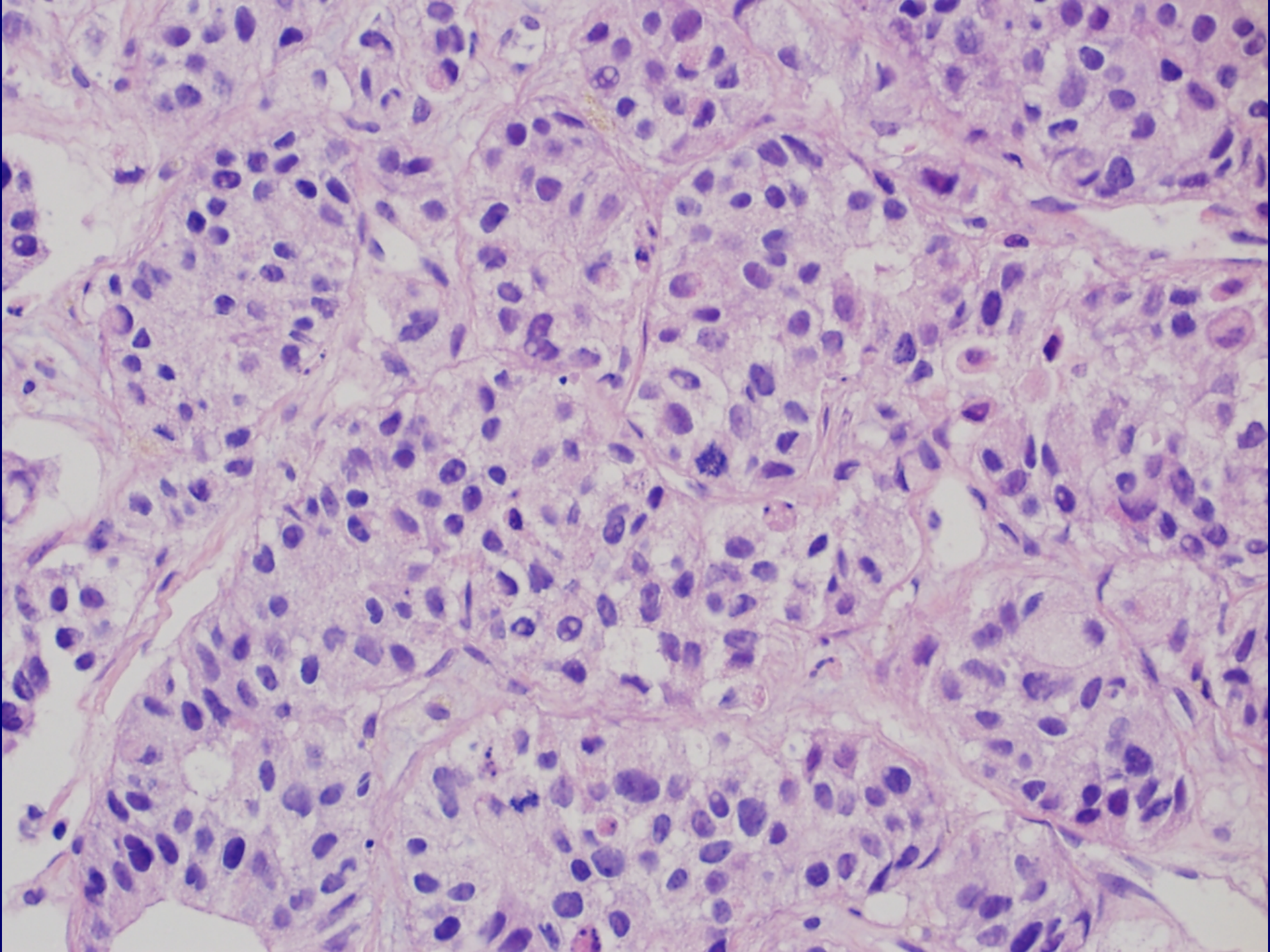

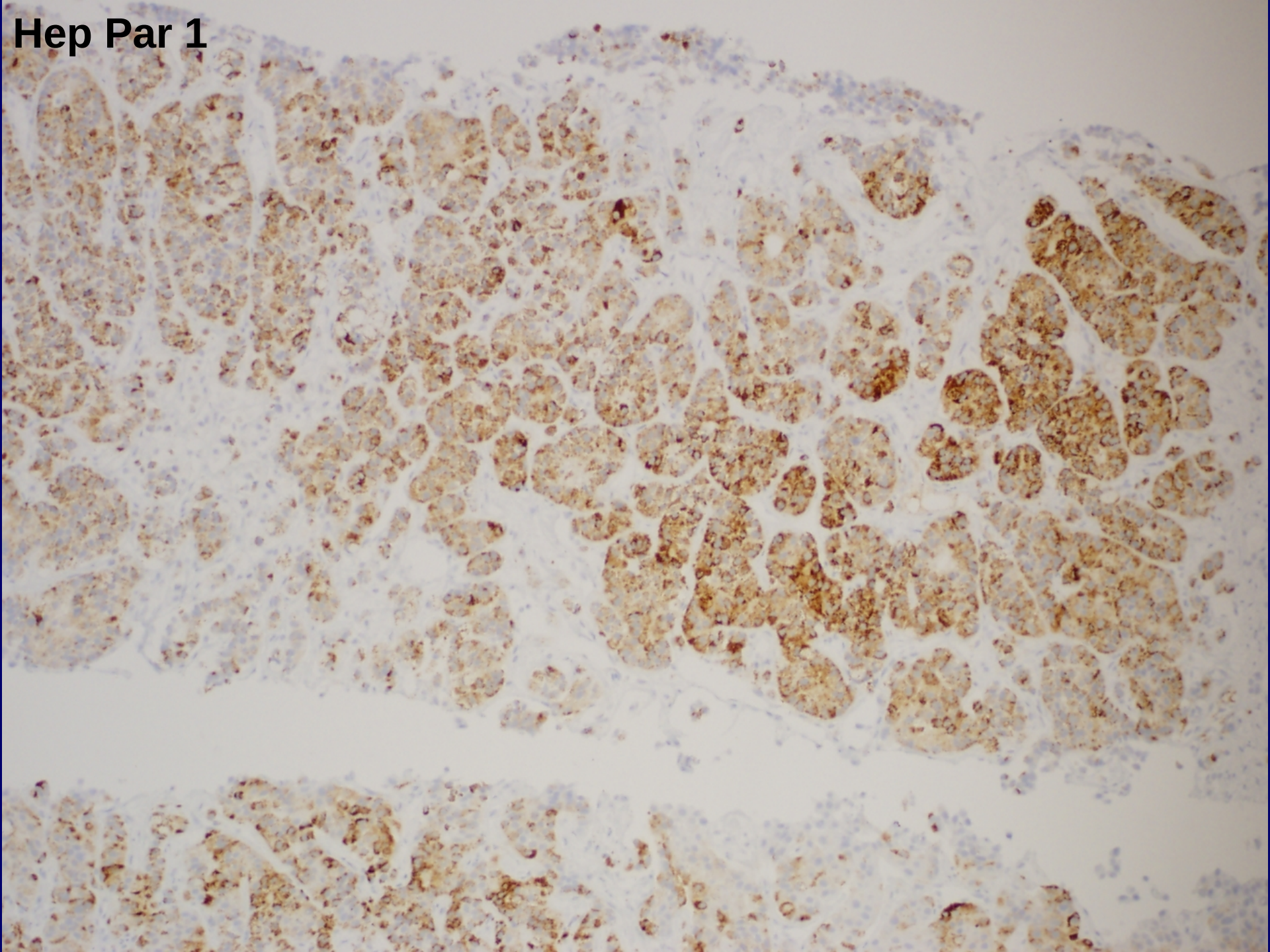
Hep Par 1

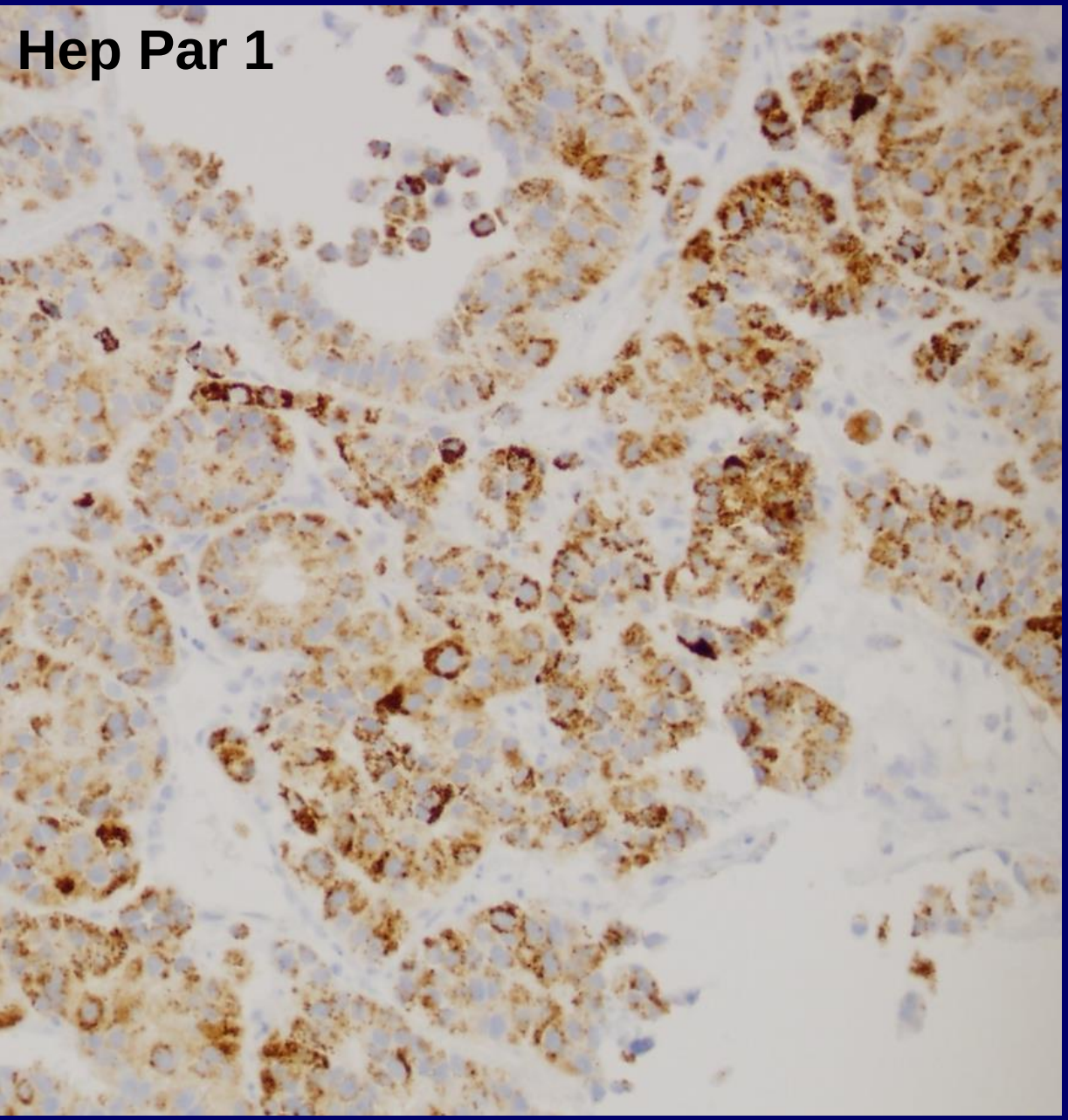

IHC summary

- Hep Par 1 +
- pCEA ±
- Pan CK +
- CK7 –
- CK20 –
- TTF1 –

‘Mesothelioma’ approach

2 hepatocellular markers	2 ‘adenocarcinoma’ markers
Arginase-1 Glypican-3 Hep Par 1 Polyclonal CEA	MOC31 CK19 CK7

Additional stains

Hep Par	CK7	Arginase-1	MOC31
+	-	-	+

- Arginase-negative HCC (rare)
- Non-HCC with aberrant Hep Par
  - -Adenocarcinoma
  - -Neuroendocrine neoplasm
  - -Renal cell carcinoma

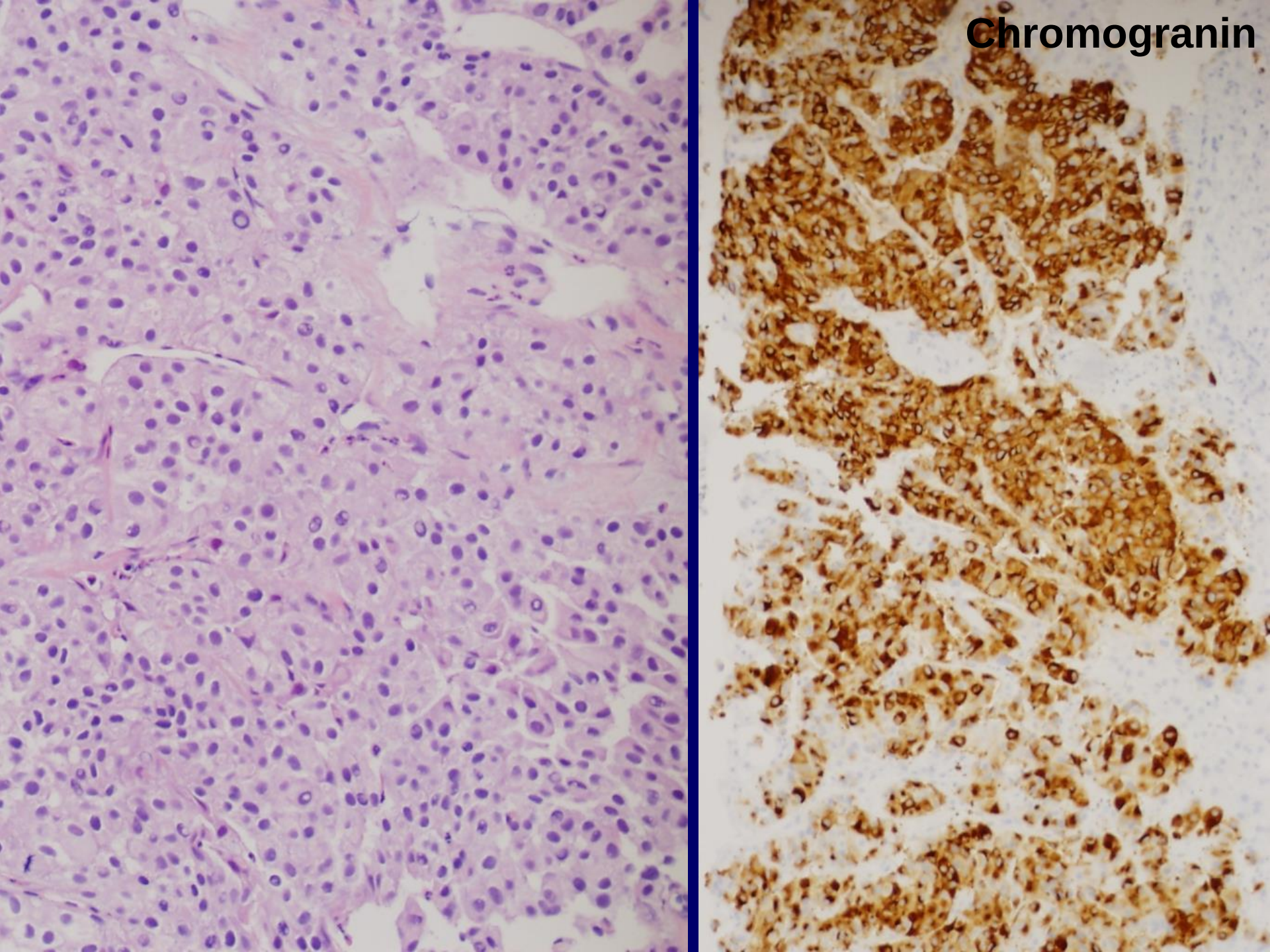
Chromogranin

Sensitivity of commonly used hepatocellular markers

	Well diff	Mod diff	Poorly diff
Hep Par 1	100%	98%	63%
pCEA	92%	88%	60%
GPC-3	62%	83%	86%
Arginase-1	100%	100%	97%

Philips/Kakar, Arch Path Lab Med 2015

Immunohistochemical approach

- Avoid large panels to determine site without excluding HCC
- Two stain approach:

  Arg-1 and CK19

Four groups

	Arg-1	CK19	Diagnosis
Group 1	+	-	HCC
Group 2	-	+	AdenoCa Arg-negative HCC
Group 3	+	+	CK19+ HCC
Group 4	-	-	Diverse group

Arginase – CK19 –

Pancytokeratin +	Pancytokeratin -
HCC	Melanoma
Adenocarcinoma	Adrenocortical CA
NE tumors, RCC	Angiomyolipoma
Urothelial CA	Sarcomas with
Squamous cell CA	epithelioid pattern

65/M with 3 cm liver mass
Imaging: 3.5 cm mass in body of pancreas

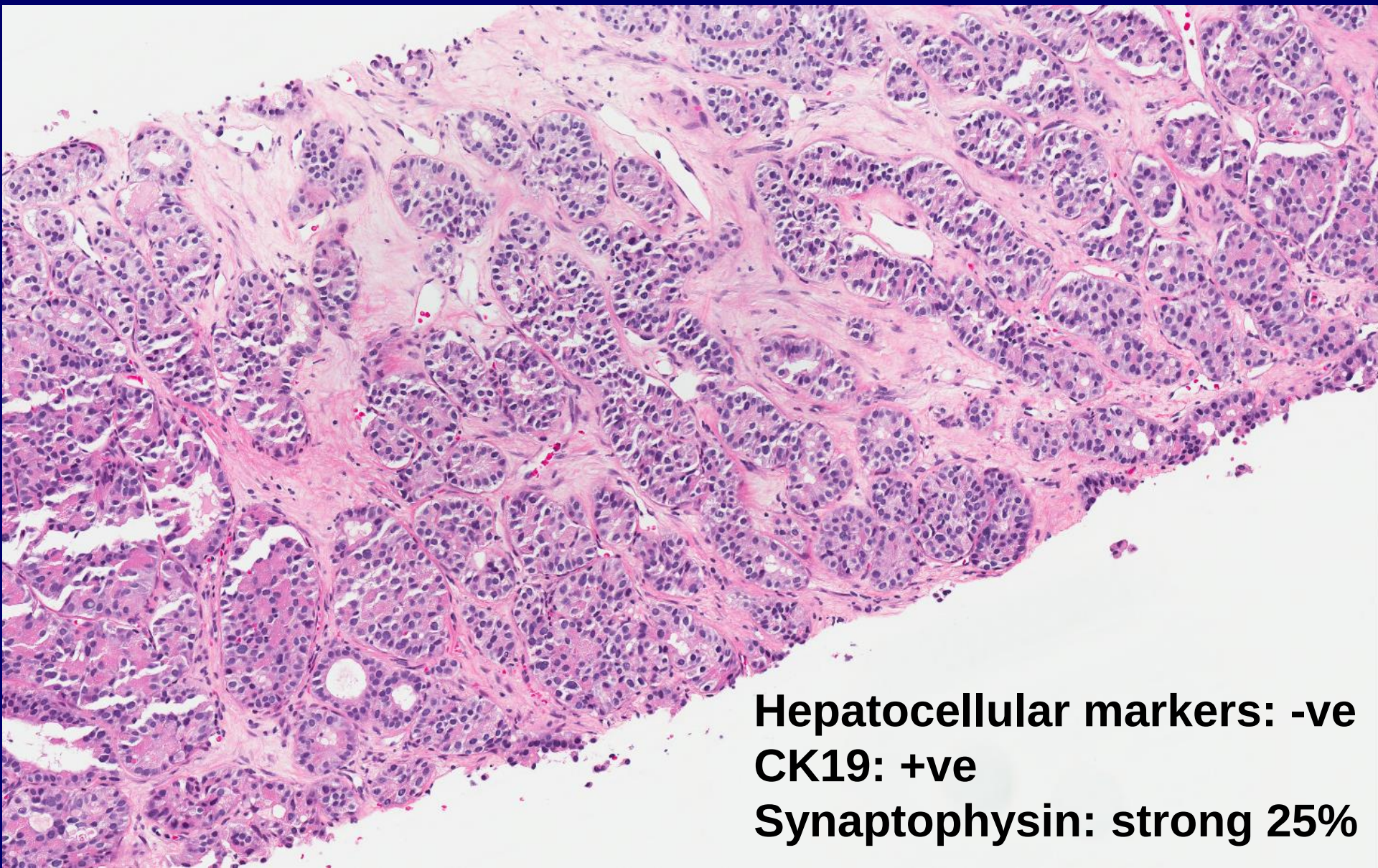

Hepatocellular markers: -ve
CK19: +ve
Synaptophysin: strong 25%

Acinar arrangement, granular cytoplasm

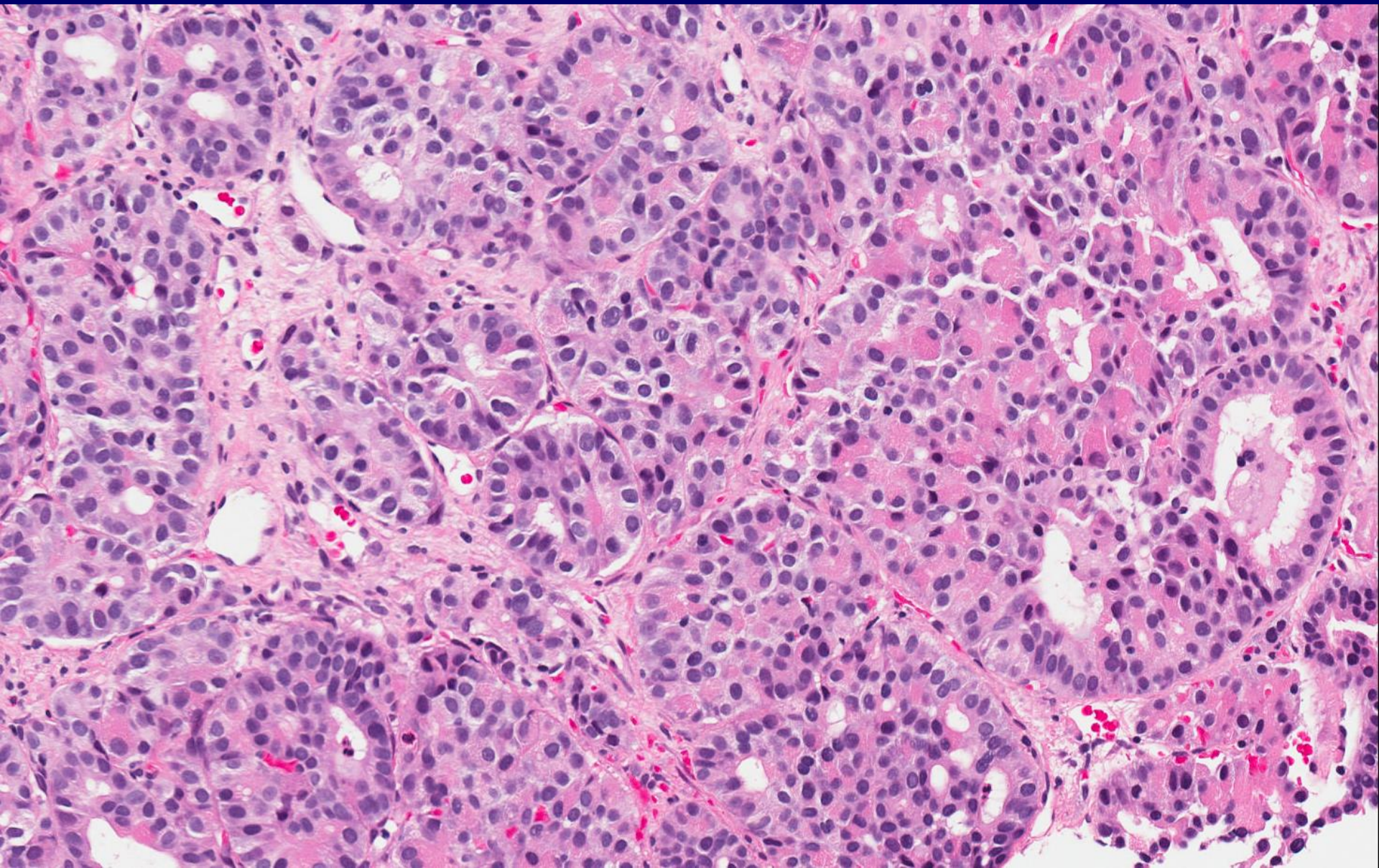

Metastatic acinar cell carcinoma

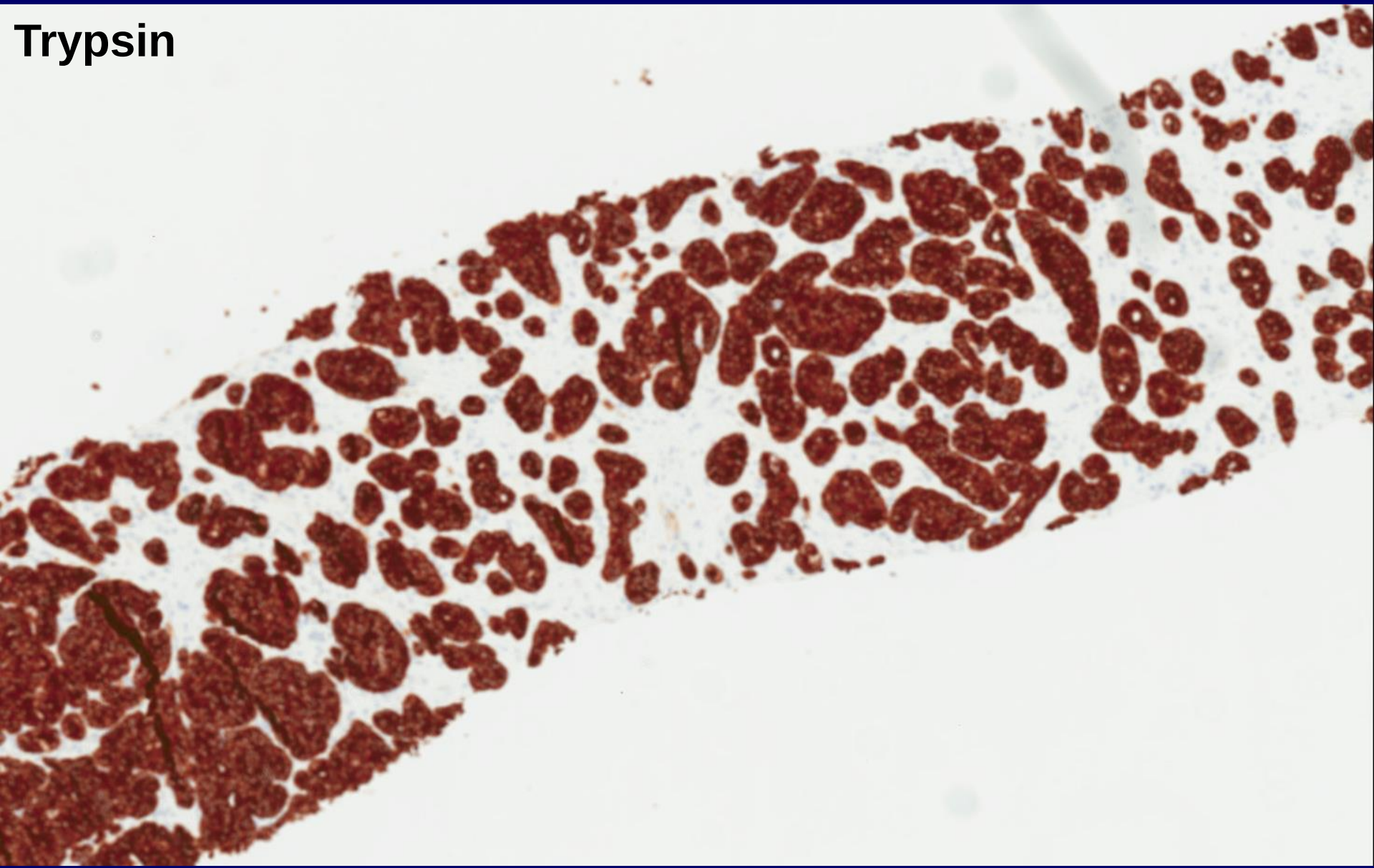

Case 1: 55/M with cirrhosis, 6 cm liver mass

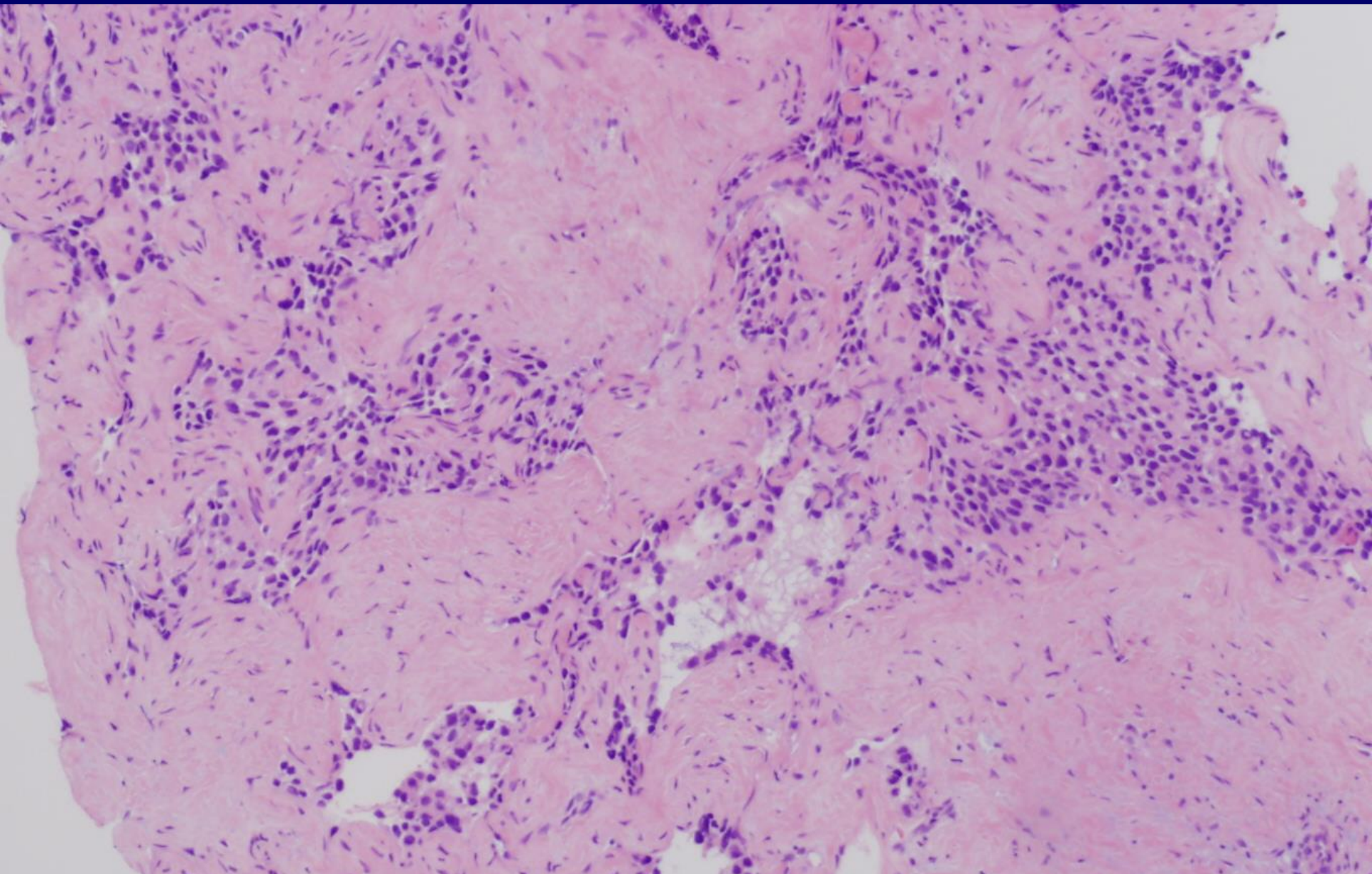

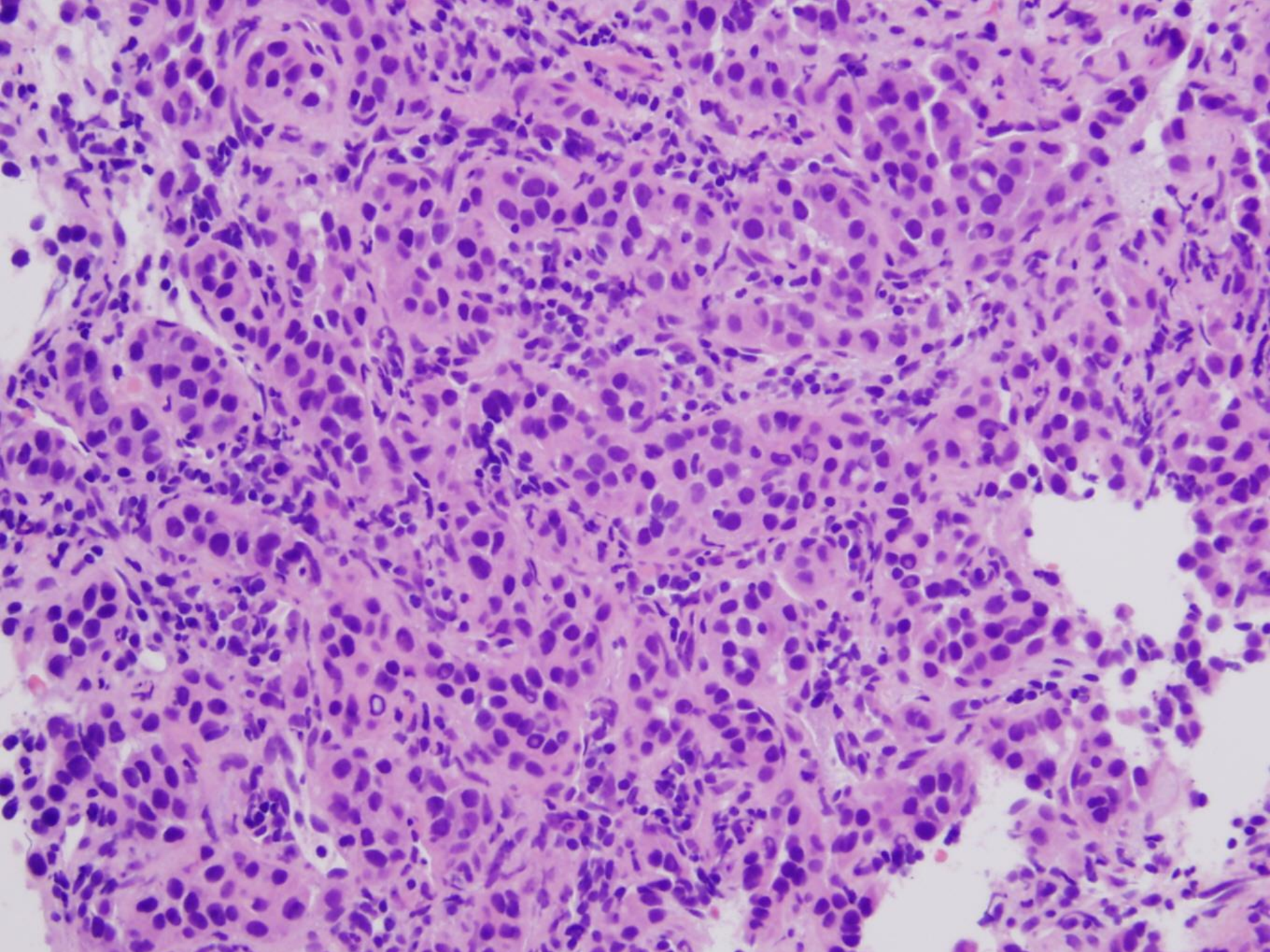

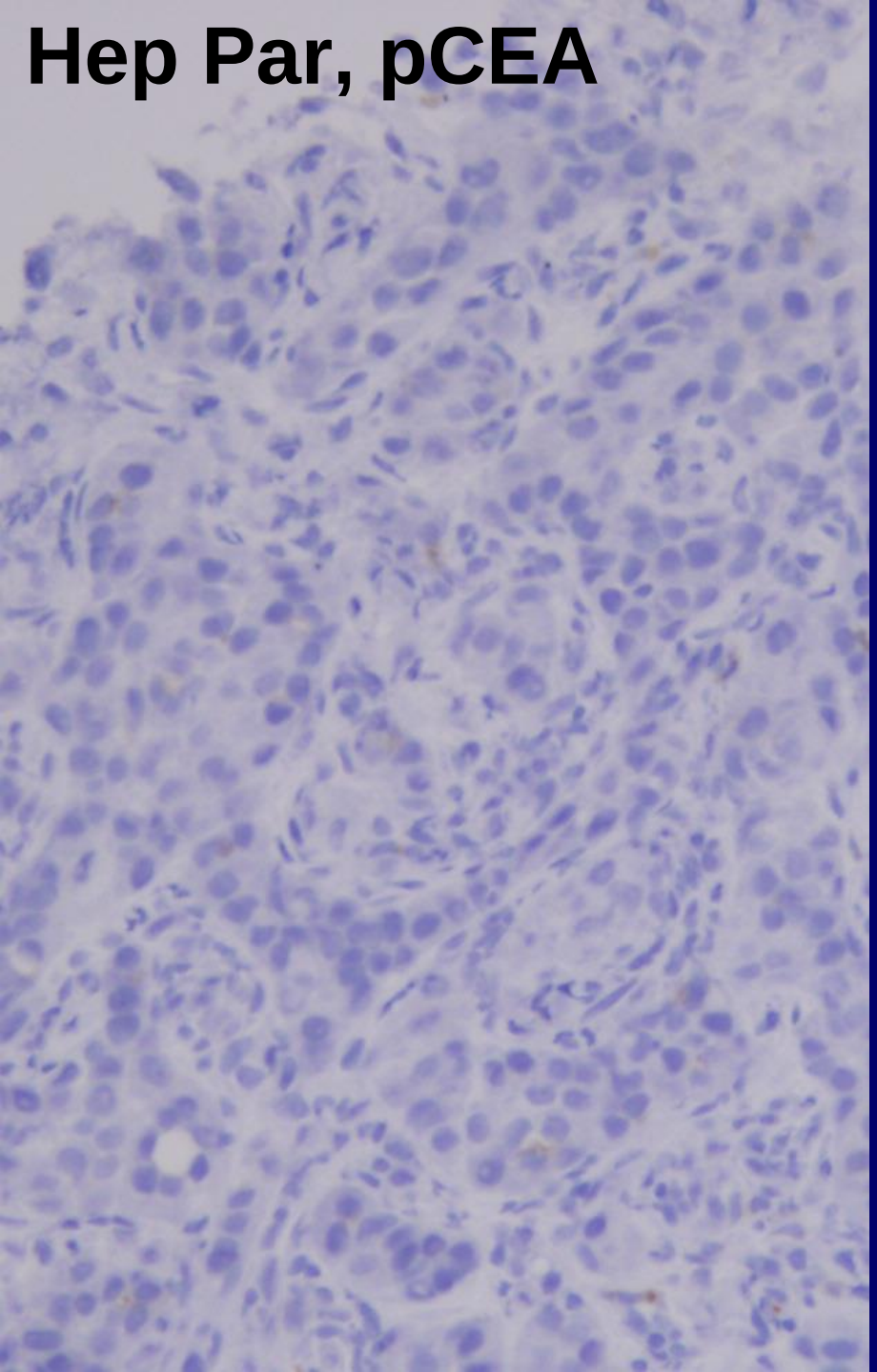
Hep Par, pCEA

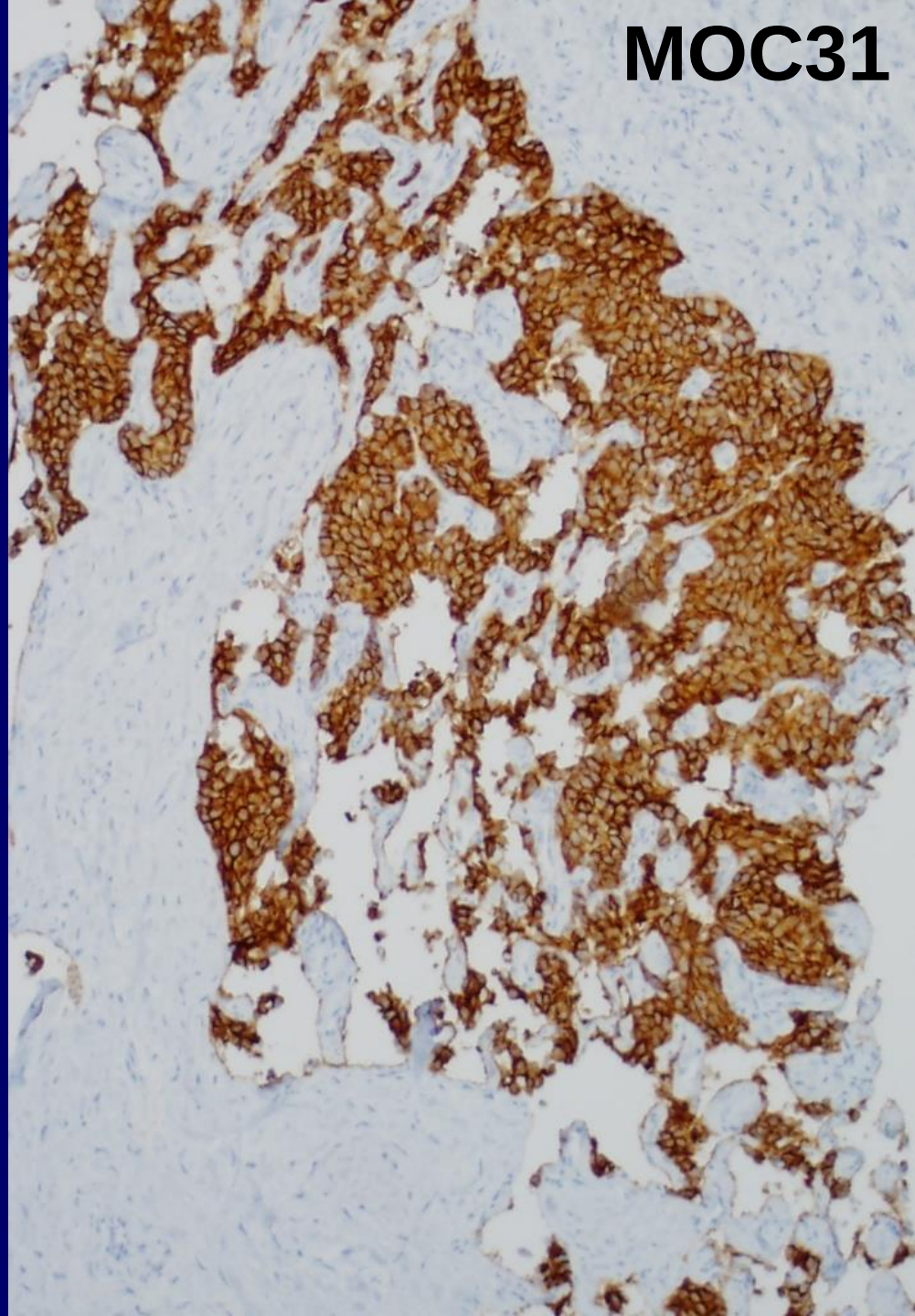
MOC31

Atypical features for HCC

- Abundant stroma
- Immunophenotypic features

  Negative: Hep Par 1, pCEA

  Positive: MOC31

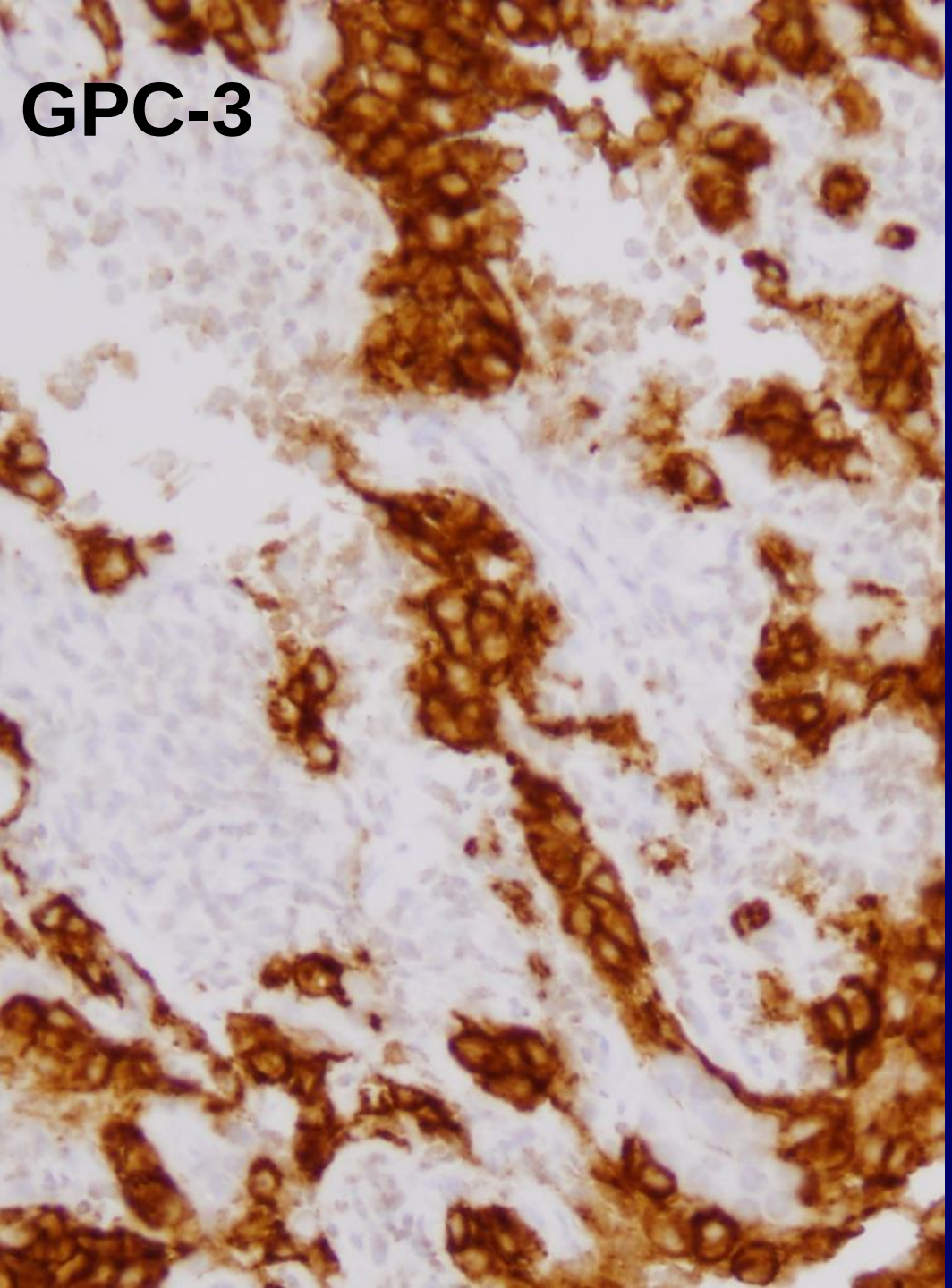
GPC-3

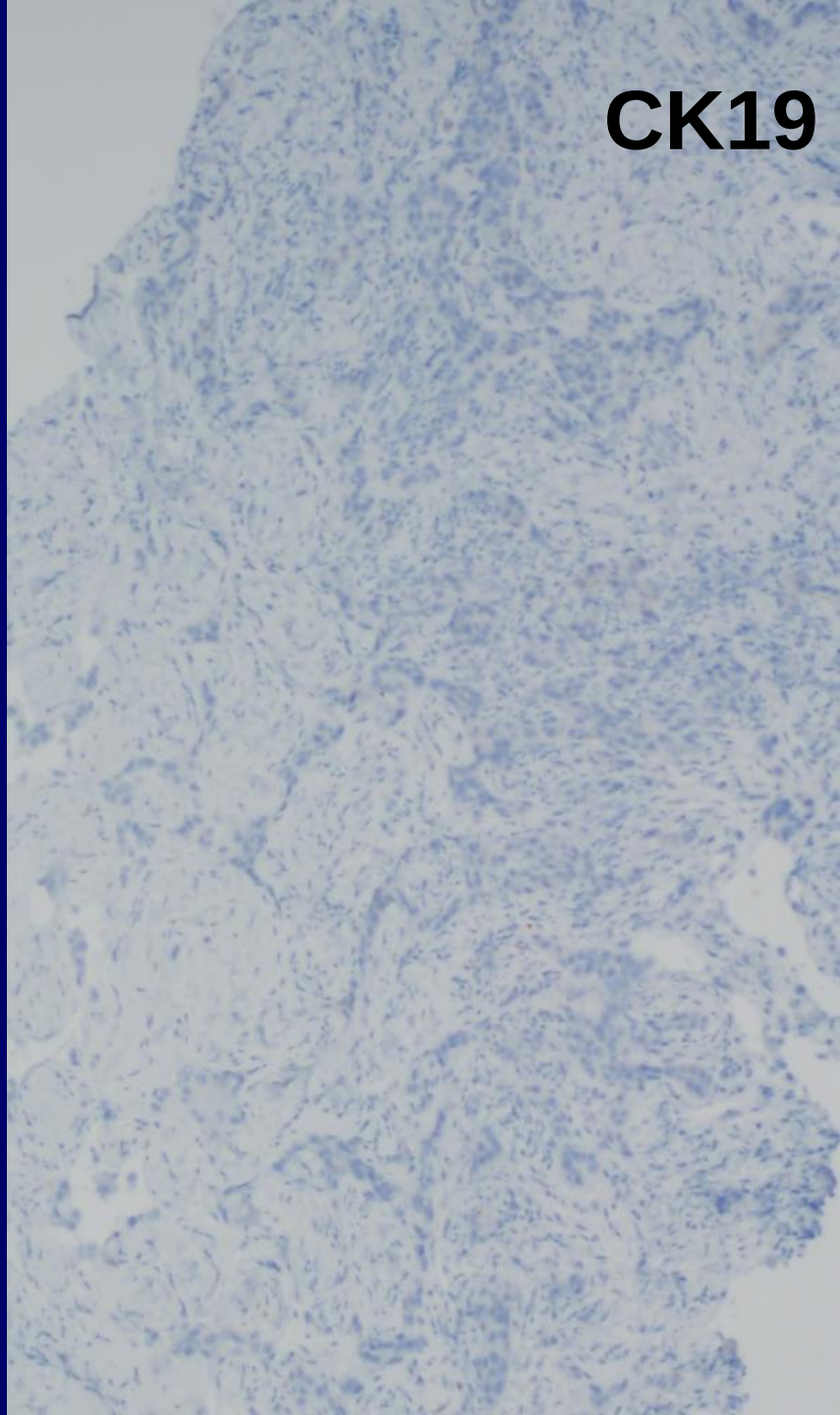
CK19

Scirrhous HCC

- Definition: >50% scirrhous component (arbitrary)
- Aberrant radiologic and immunophenotypic features

Radiologic features	Scirrhous HCC	Conventional HCC
Arterial enhancement and venous washout	19%	99%
Peripheral enhancement	62%	3%
Prolonged enhancement	95%	4%

	Scirrhous HCC	Conventional HCC
Hep Par 1	17-20%	80-90%
pCEA	33%	60-80%
CK7	58-65%	0-20%
CK19	50%	0-10%
MOC31	64%	5-11%
Arginase-1	95%	95%
Glypican-3	95%	70-80%

Matsuura, Histopath, 2005
Krings/Kakar, Mod Pathol 2013

Scirrhous HCC
Common pitfalls

- Cholangiocarcinoma or metastatic adenocarcinoma
  - Imaging, fibrous stroma, CK7+ CK19+
- Lack Hep Par 1, pCEA
  - Use sensitive markers like arginase-1

Case 2: 28/M with hepatitis B, no cirrhosis and 5 cm liver mass

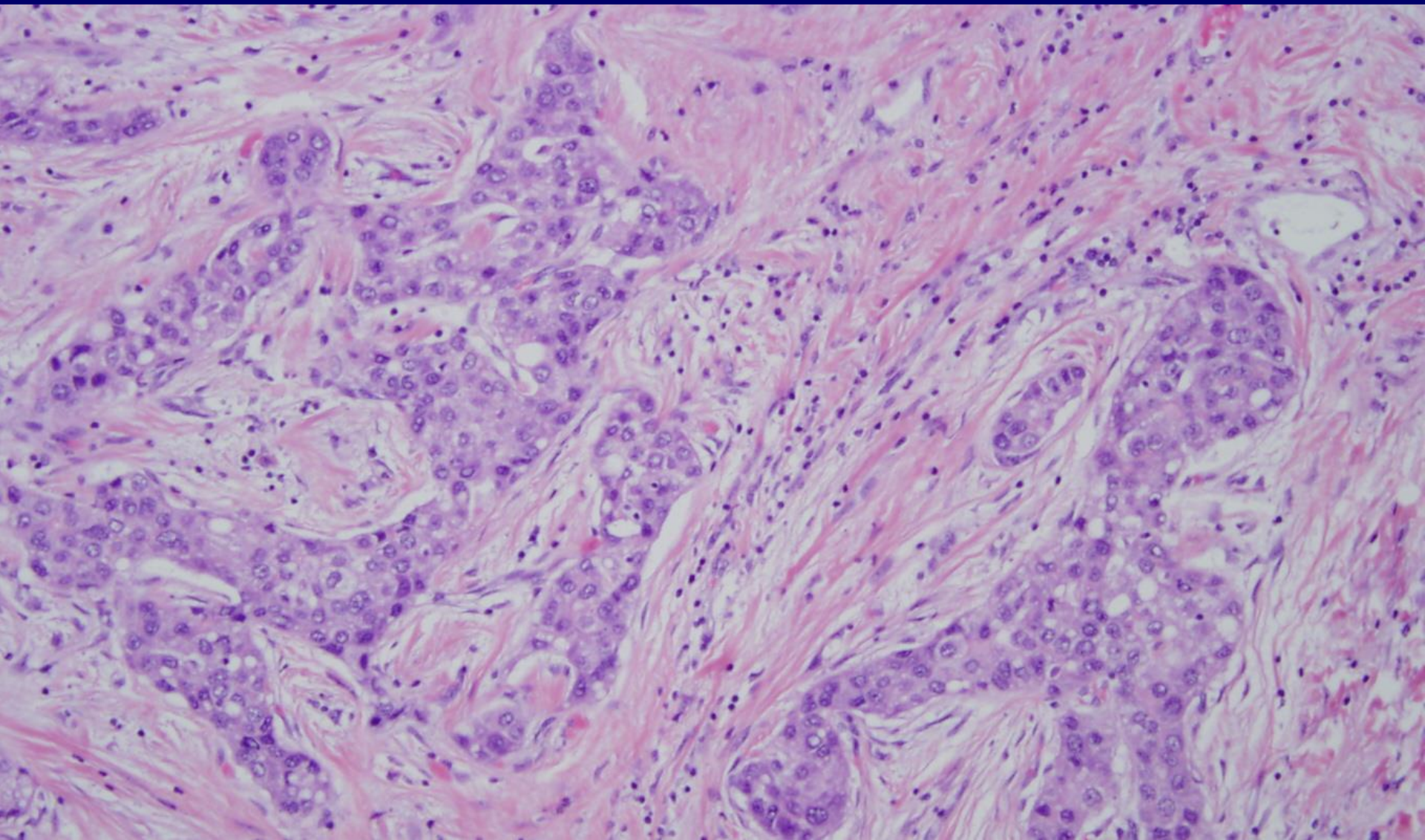

(Immuno) histochemistry

Test	Result in tumor cells
Hep Par 1	Positive
Arginase-1	Positive
CK7	Positive
CK19	Negative
Mucin	Negative

Diagnosis

- Initial: Fibrolamellar carcinoma
- Refused entry into a clinical trial for HCC
- Sent for review

Fibrolamellar carcinoma

- **Young age**
- **Mean age: 26 years**

  80% 10-35 years
- **No chronic liver disease or cirrhosis**
- **Normal AFP**

Fibrolamellar carcinoma: central scar

Triad of microscopic features

Oncocytic cytoplasm, prominent nucleoli, lamellar fibrosis

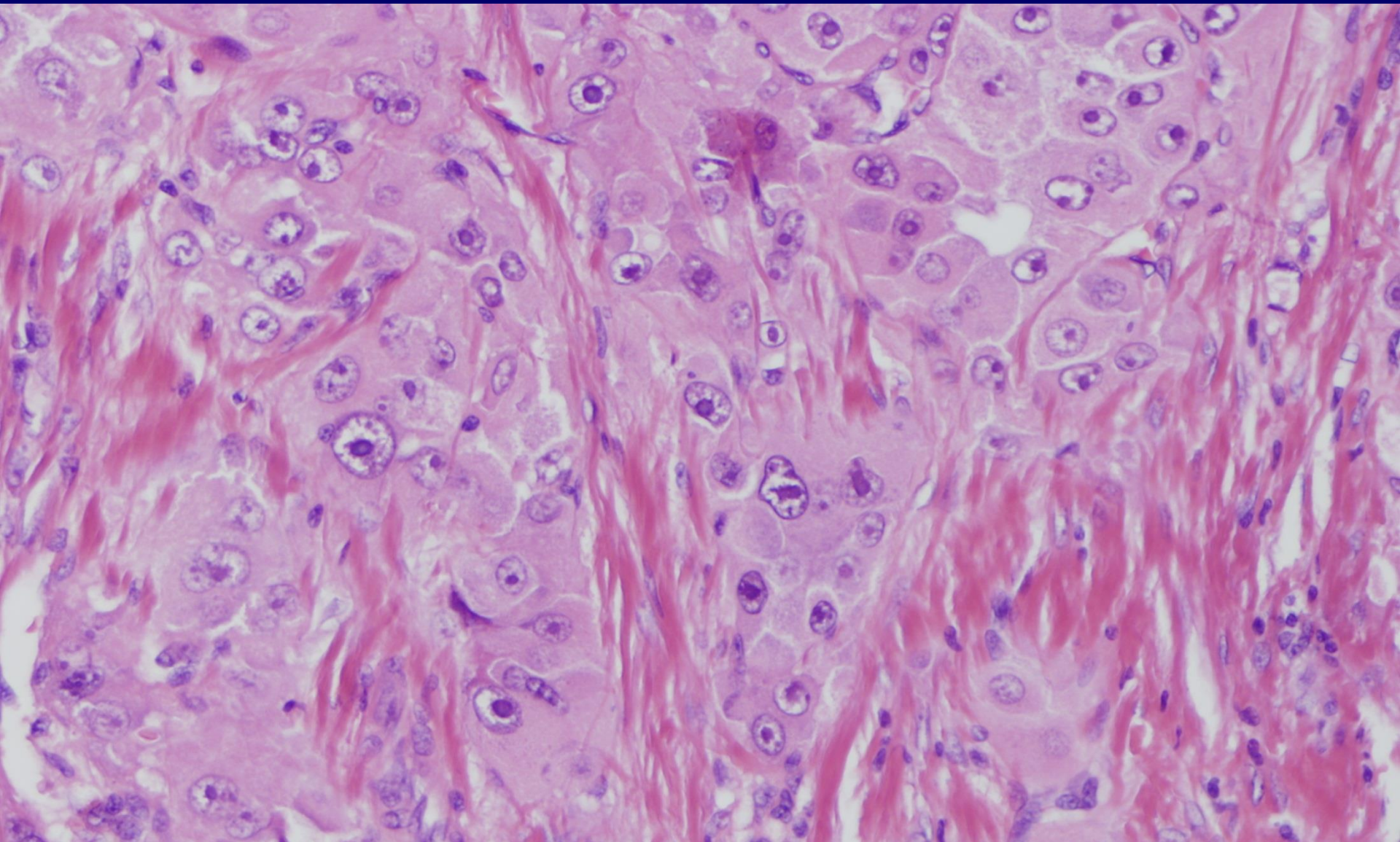

Fibrolamellar carcinoma: pale bodies

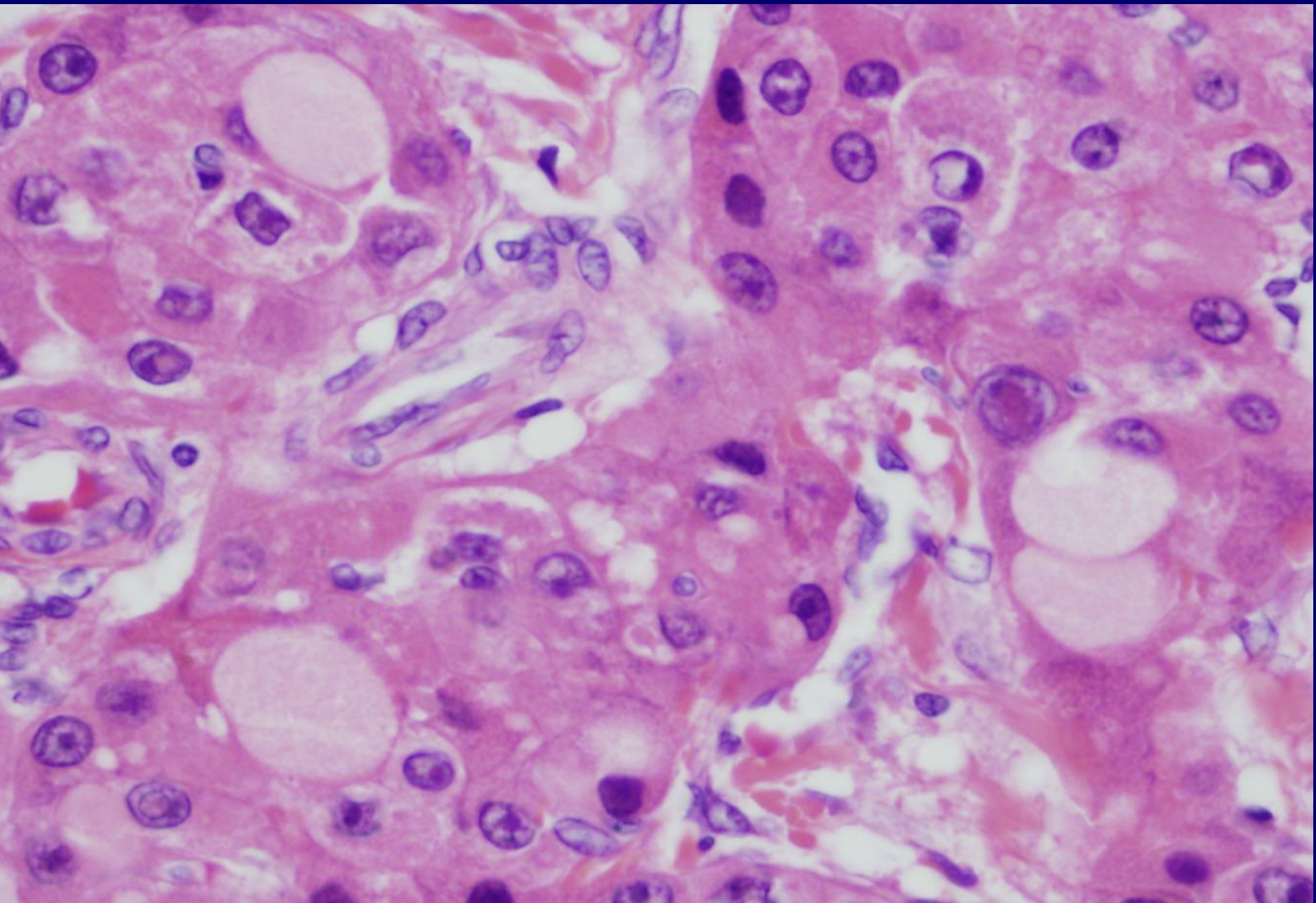

Fibrolamellar-like

- Lack diagnostic triad of FLM
- Not a recognized variant
- Lack clinicopathologic features of FLM
  - Older patients
  - Elevated AFP
  - Cirrhosis, hepatitis B or C

CD68, CK7: Nearly all FLM

CD68: HCC 25%, cholangiocarcinoma negative

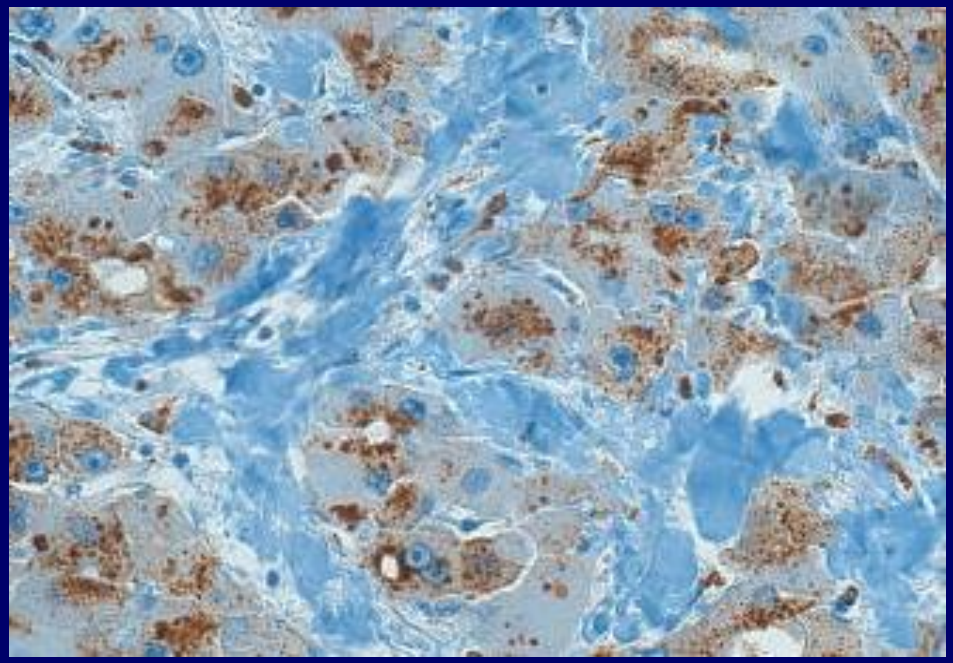

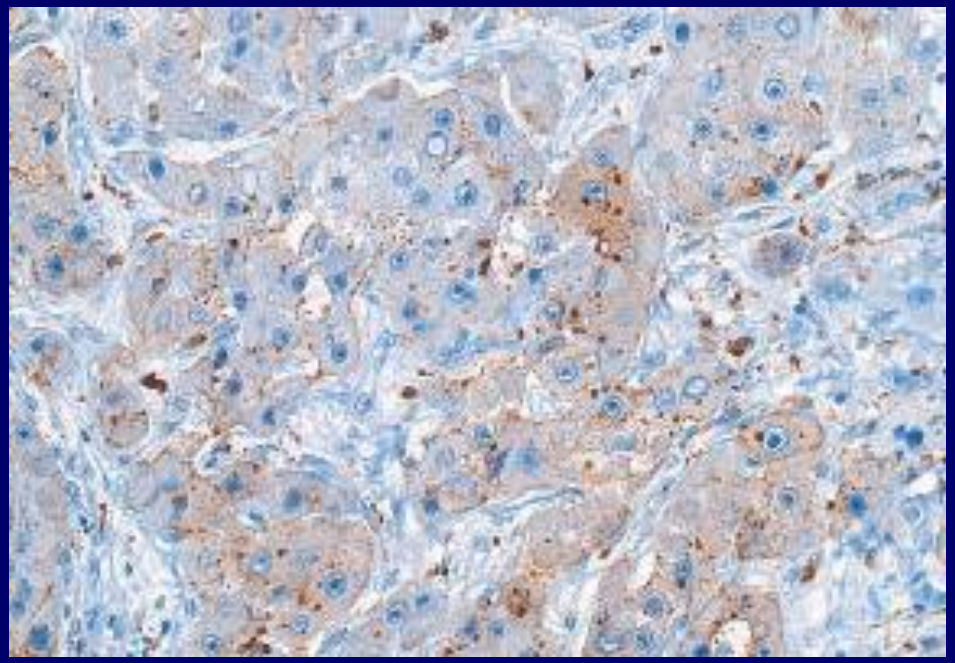

Torbenson, Mod Pathol, 2011

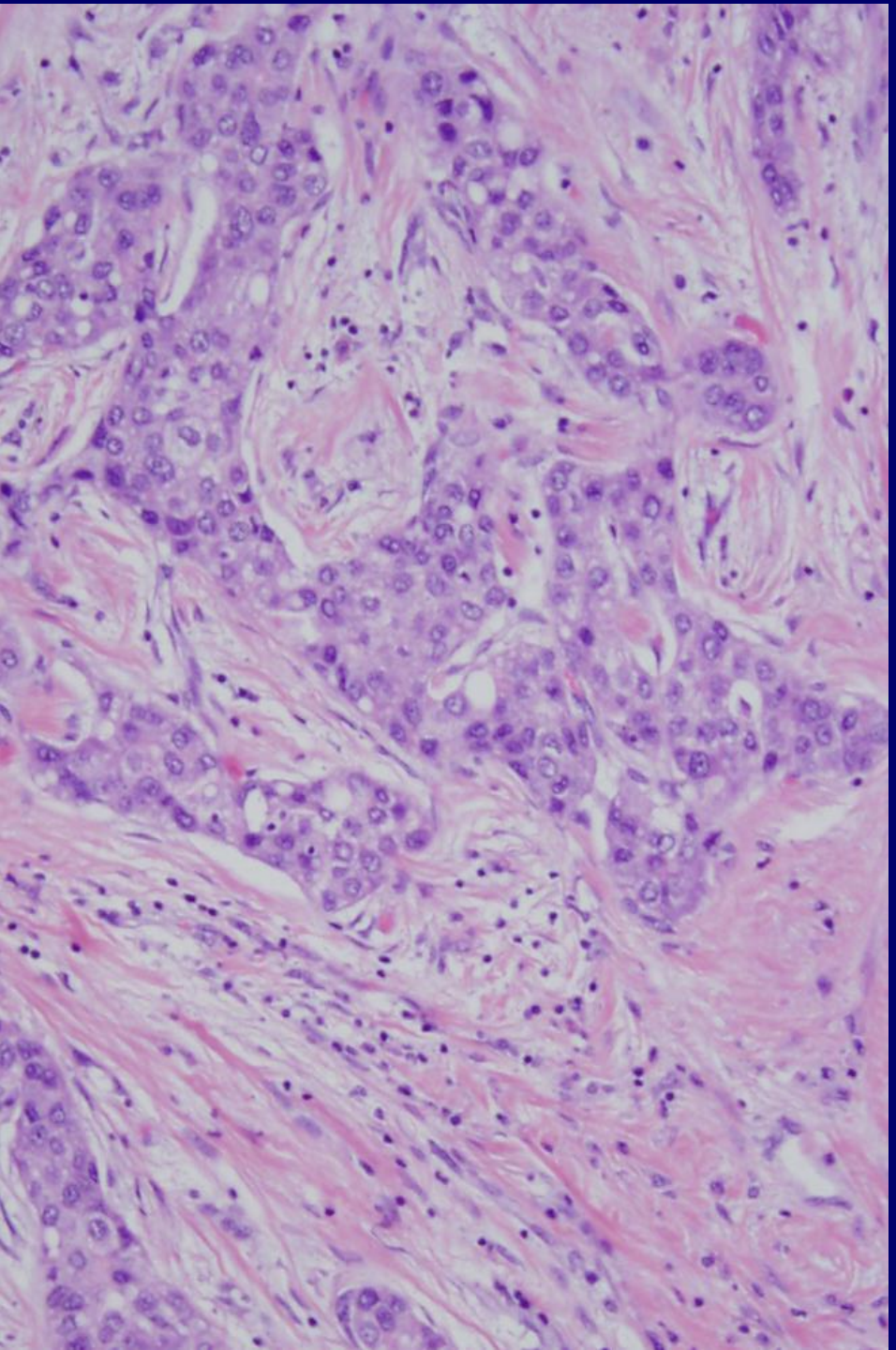

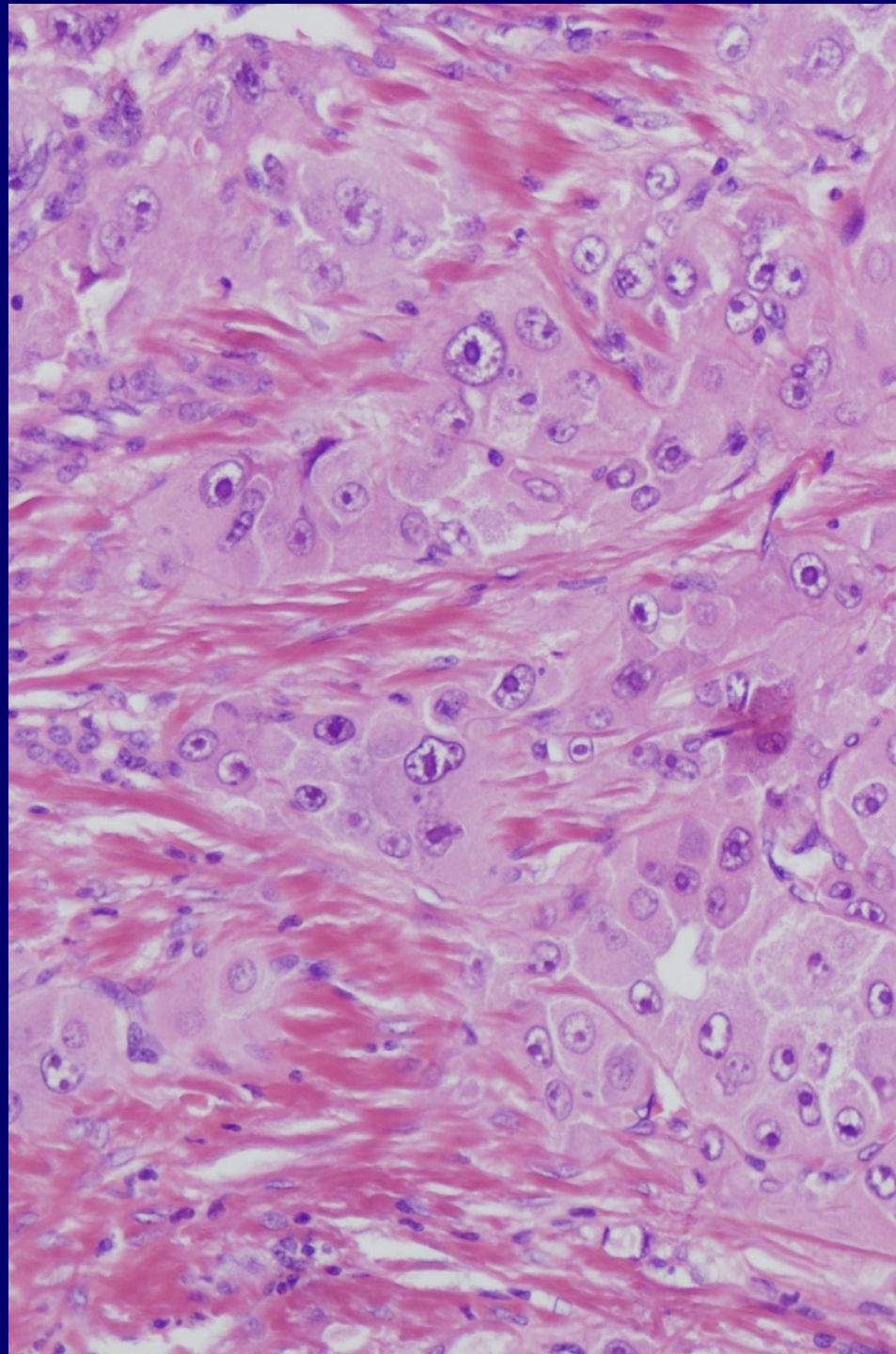

FLM: outcome same as HCC in noncirrhotic liver

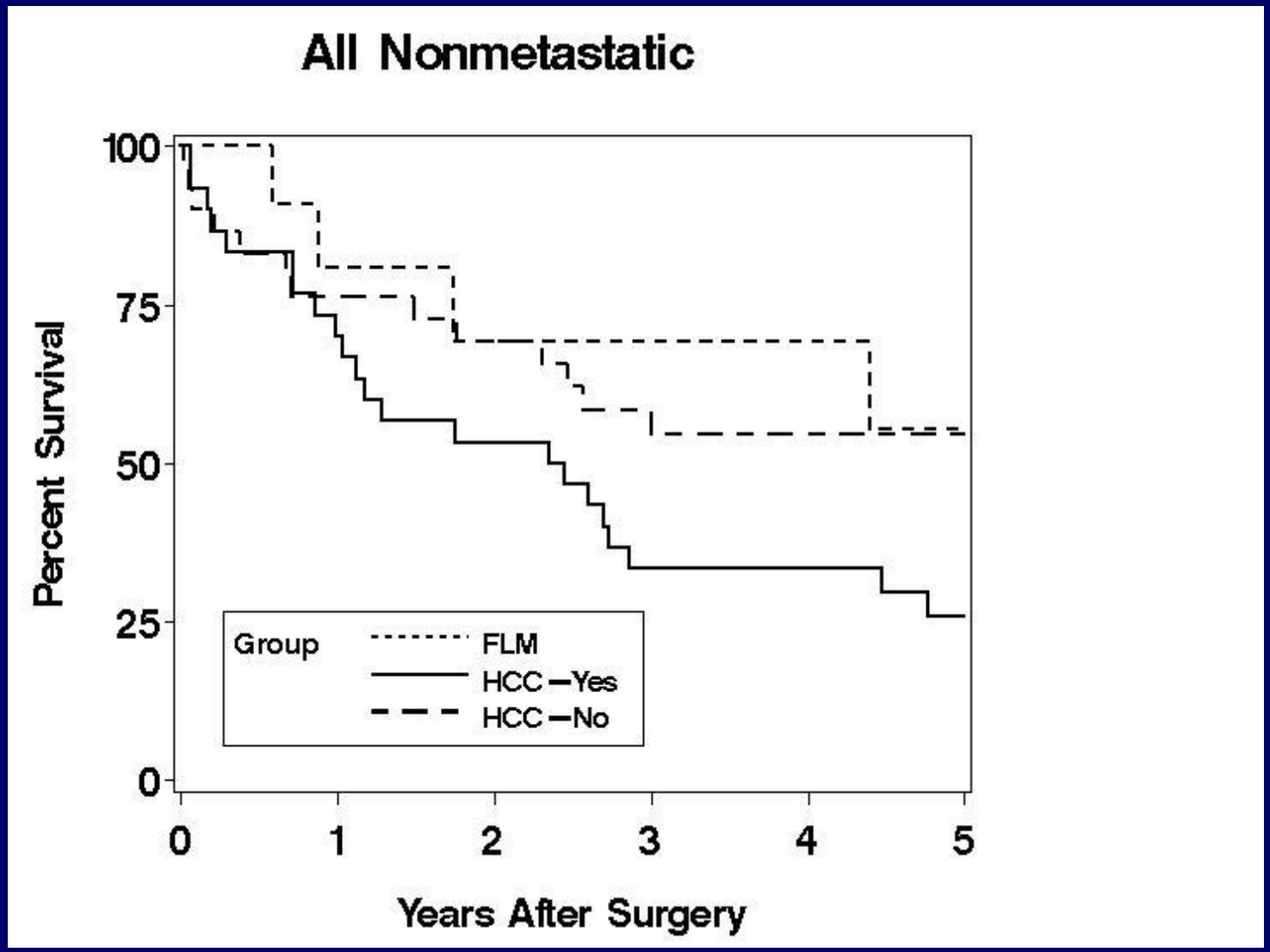

Kakar, Mod Pathol, 2004

Significance

- Affects surgical approach:

  Lymph node metastasis: 50-60%
- Affects enrollment in clinical trials

Detection of a Recurrent *DNAJB1-PRKACA* Chimeric Transcript in Fibrolamellar Hepatocellular Carcinoma

Joshua N. Honeyman,[1,2]* Elana P. Simon,[1,3]* Nicolas Robine,[4]* Rachel Chiaroni-Clarke,[1]

- **400-kb heterozygous deletion on chr 19**
- **J domain of DNAJB1 and catalytic domain of PRKACA**
- **Chimeric DNAJB1-PRKACA protein**

Science 2014

DNAJB1-PRKACA in FLM

Study	DNAJB1-PRKACA fusion
Honeyman, Science 2014	100% (n=15)
Cornella, Gastroenterol 2015	80% (n=73)
Graham, Mod Pathol 2015	100%(n=24) Other tumor types: negative 25 Classical HCC, 25 cholangiocarcinomas, 25 adenomas, 5 hepatoblastomas

Breakpart FISH assay:

PRKACA 5' end: red probe, 3' end: green probe.
Normal: together. Deletion: loss of 5' end, only 3' green signal visible

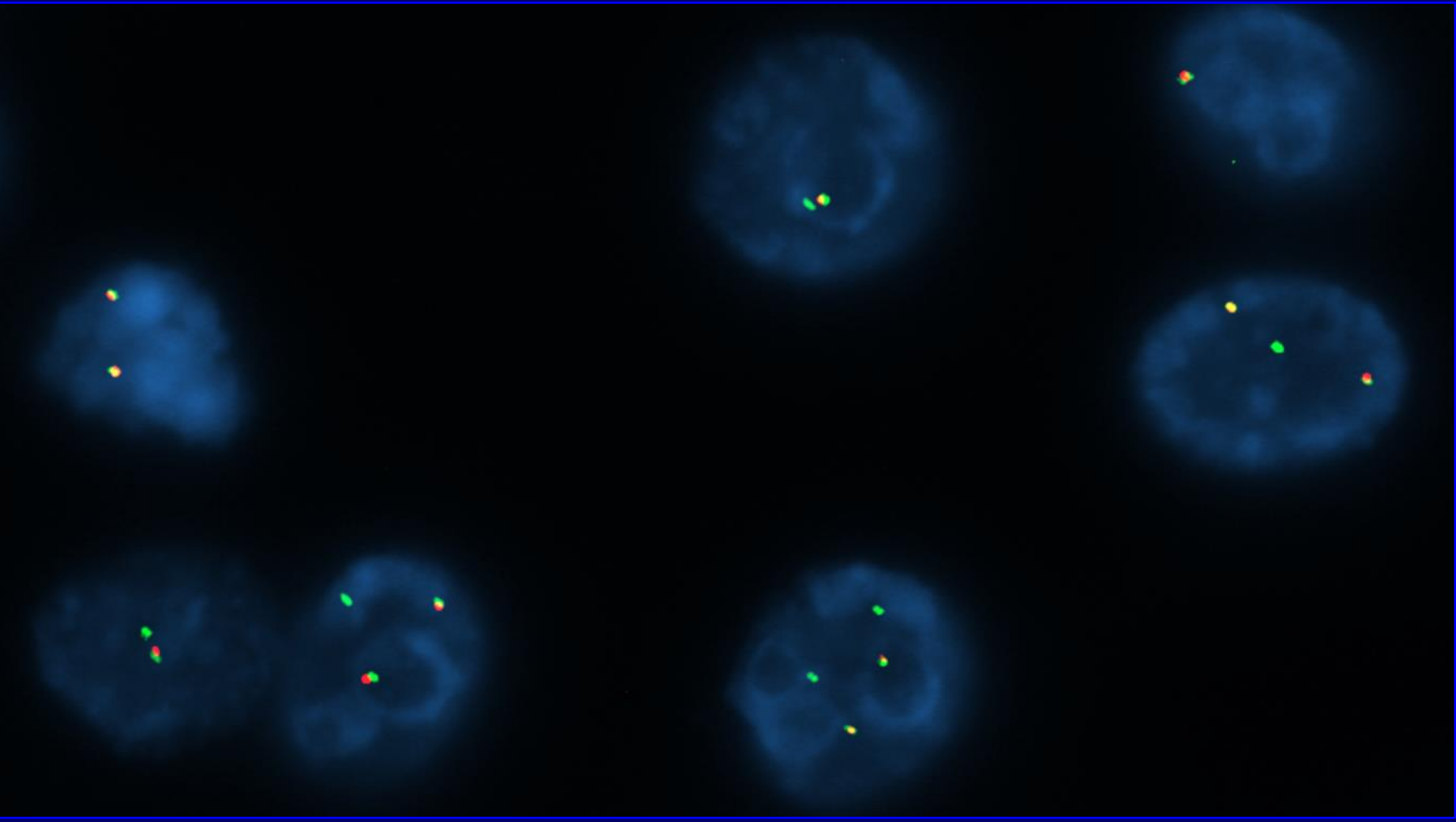

Image provided by Dr. Torbenson, Mayo Clinic

Fibrolamellar carcinoma
common pitfalls

- Young age, non-cirrhotic liver: most are conventional HCC
- Scirrhous HCC: fibrosis
- Adenocarcinoma: Glands, mucin, CK7+
- Neuroendocrine markers
- FISH/RT-PCR for borderline cases

Case 3

- 53 year old obese woman
- 5 cm liver mass
- Core needle biopsy

  Hepatocellular carcinoma

Lesional cells: fat, ballooning, fibrosis

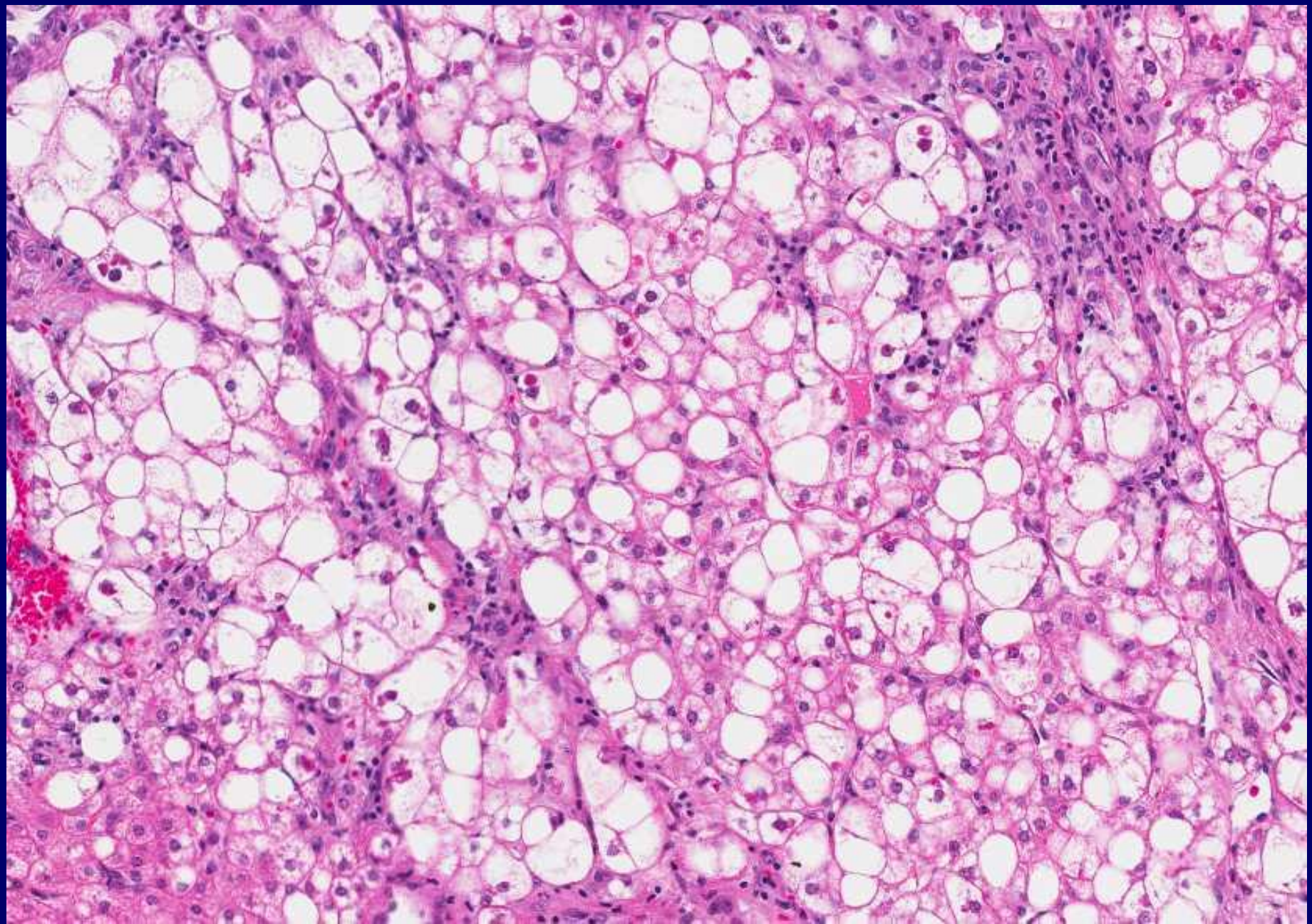

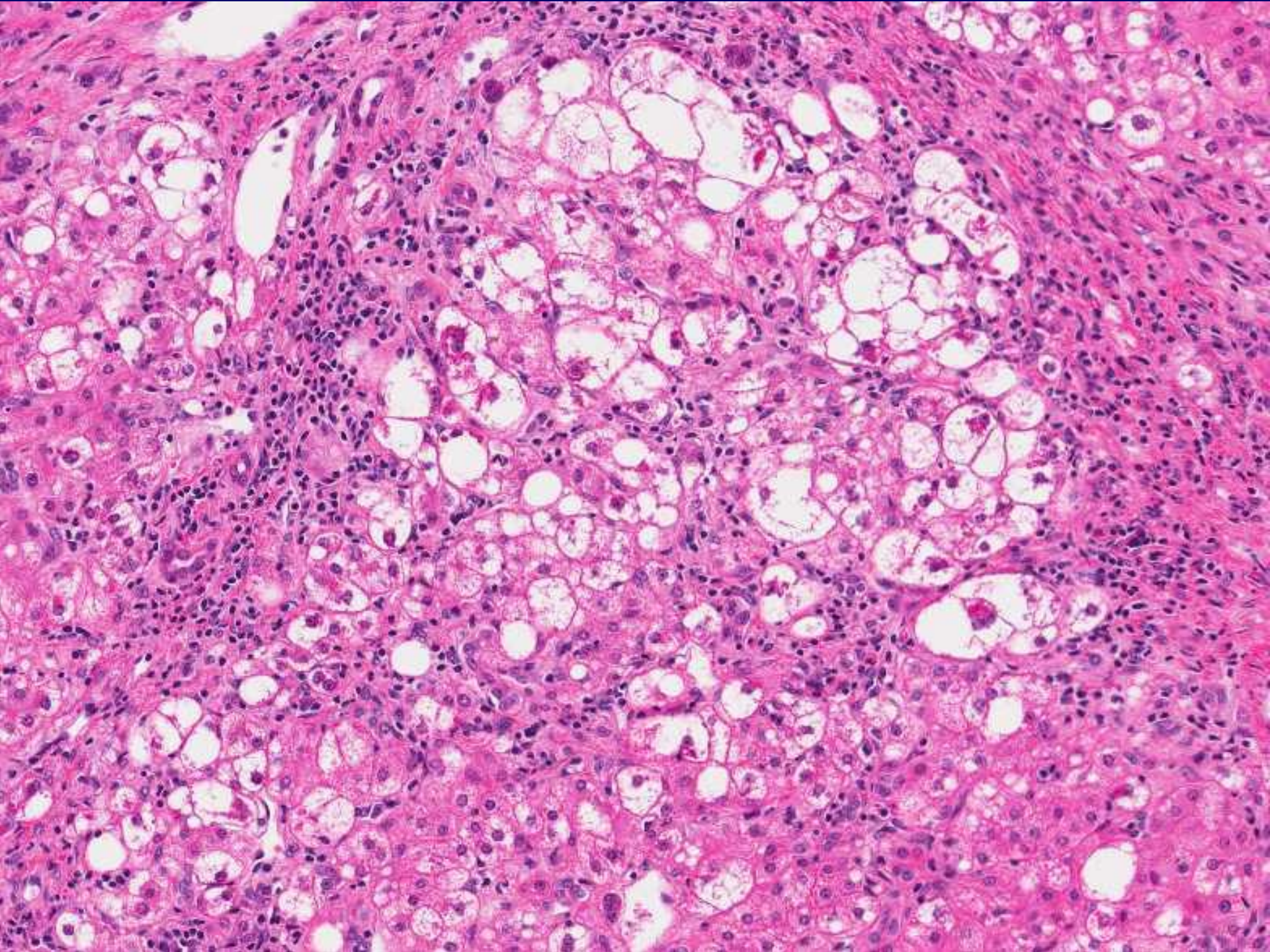

Steatohepatitic HCC

- **Tumor cells have features of SH**
  - **Steatosis**
  - **Ballooning, Mallory hyaline**
  - **Pericellular fibrosis**
- **Strong association with metabolic syndrome**

Salomao, Hum Pathol 2012

Salomao, AJSP, 2012

Reticulin Loss in Benign Fatty Liver: An Important Diagnostic Pitfall When Considering a Diagnosis of Hepatocellular Carcinoma

Singhi, AJSP, 2012

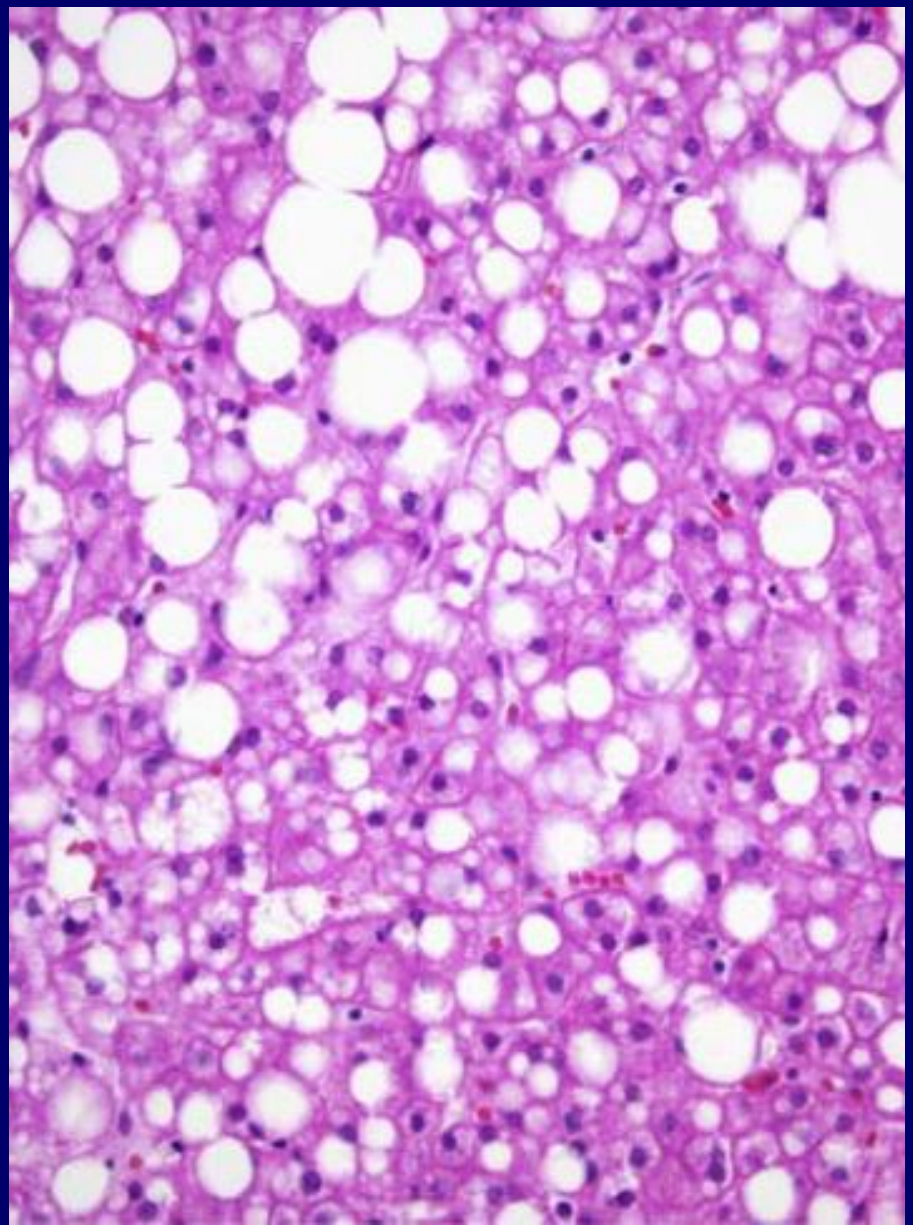

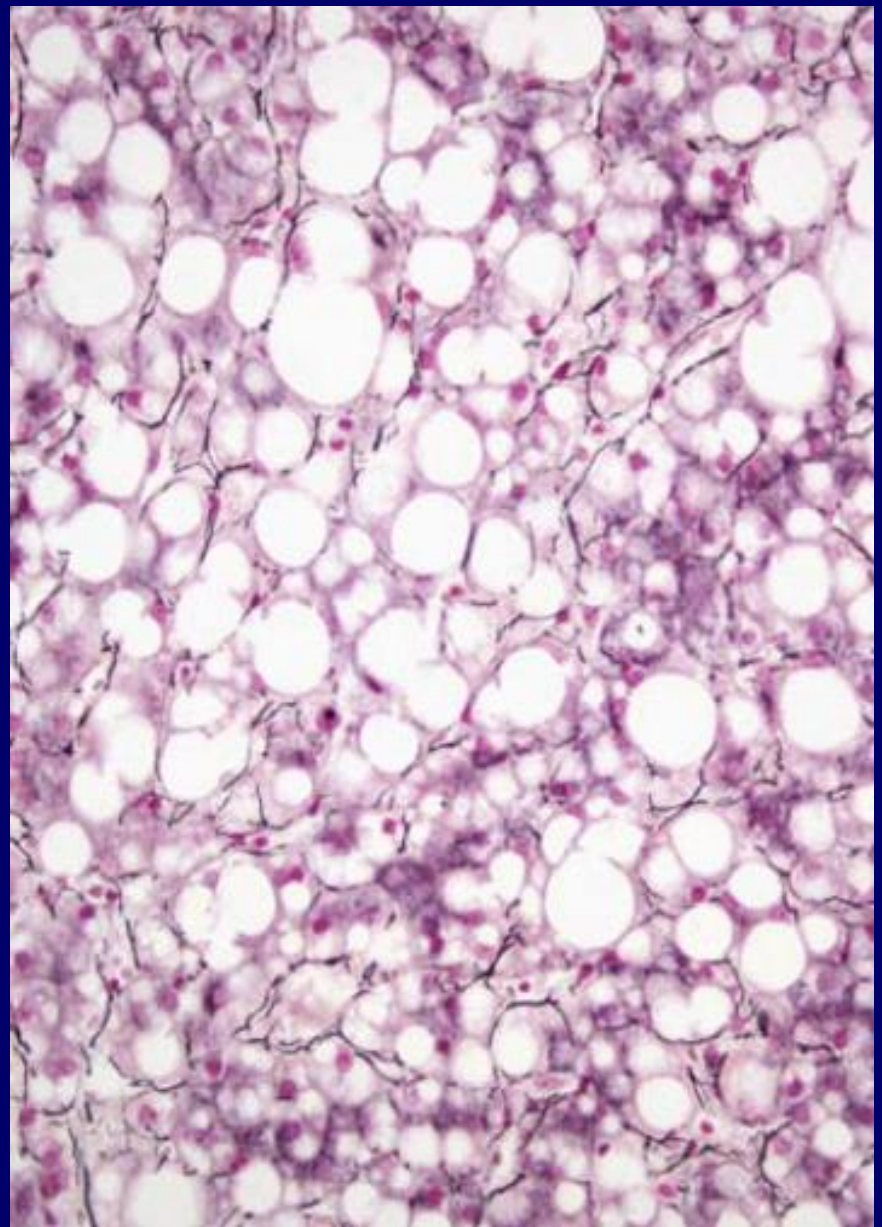

Centrizonal arterioles in SH

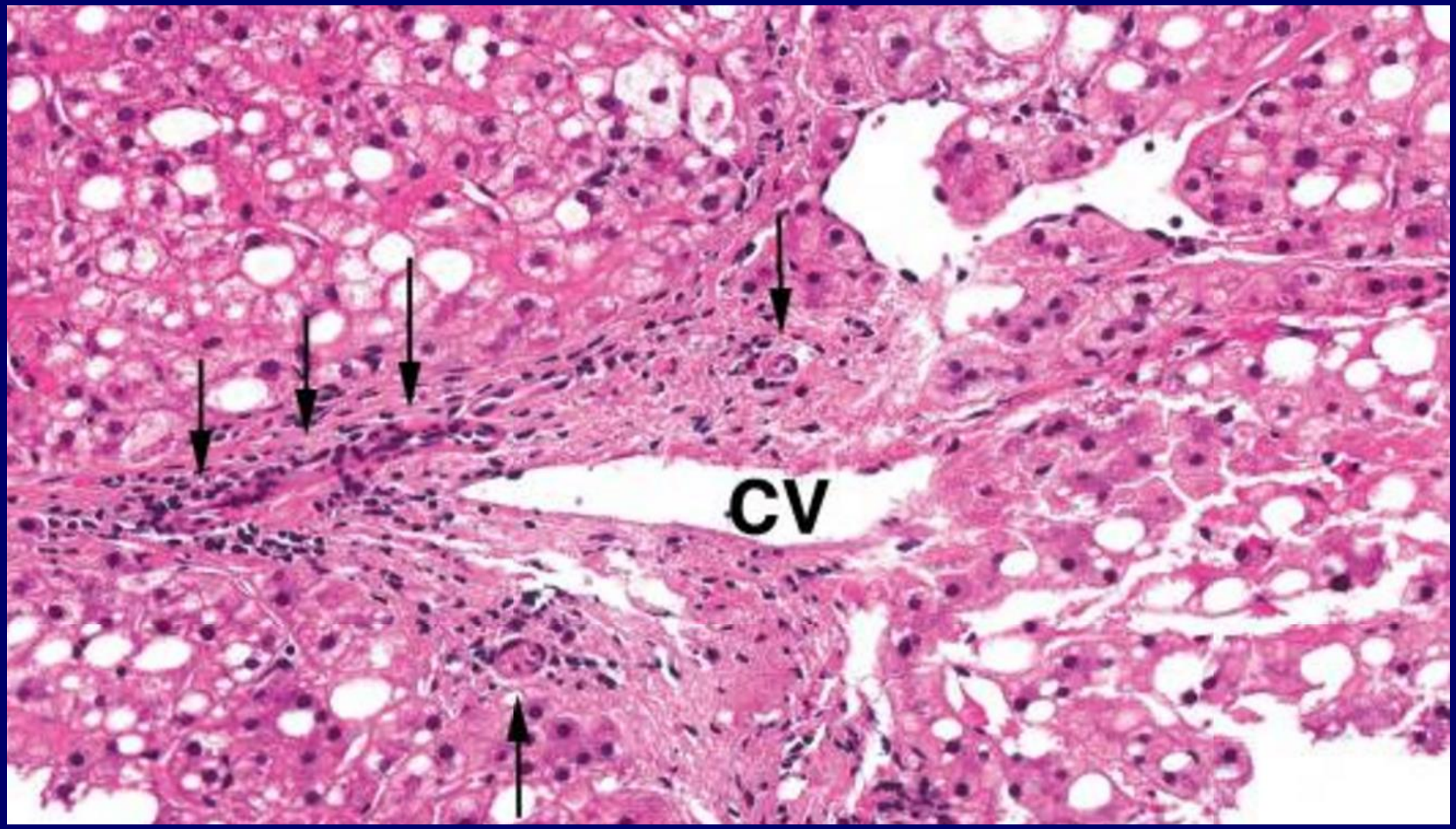

Gill, AJSP 2011

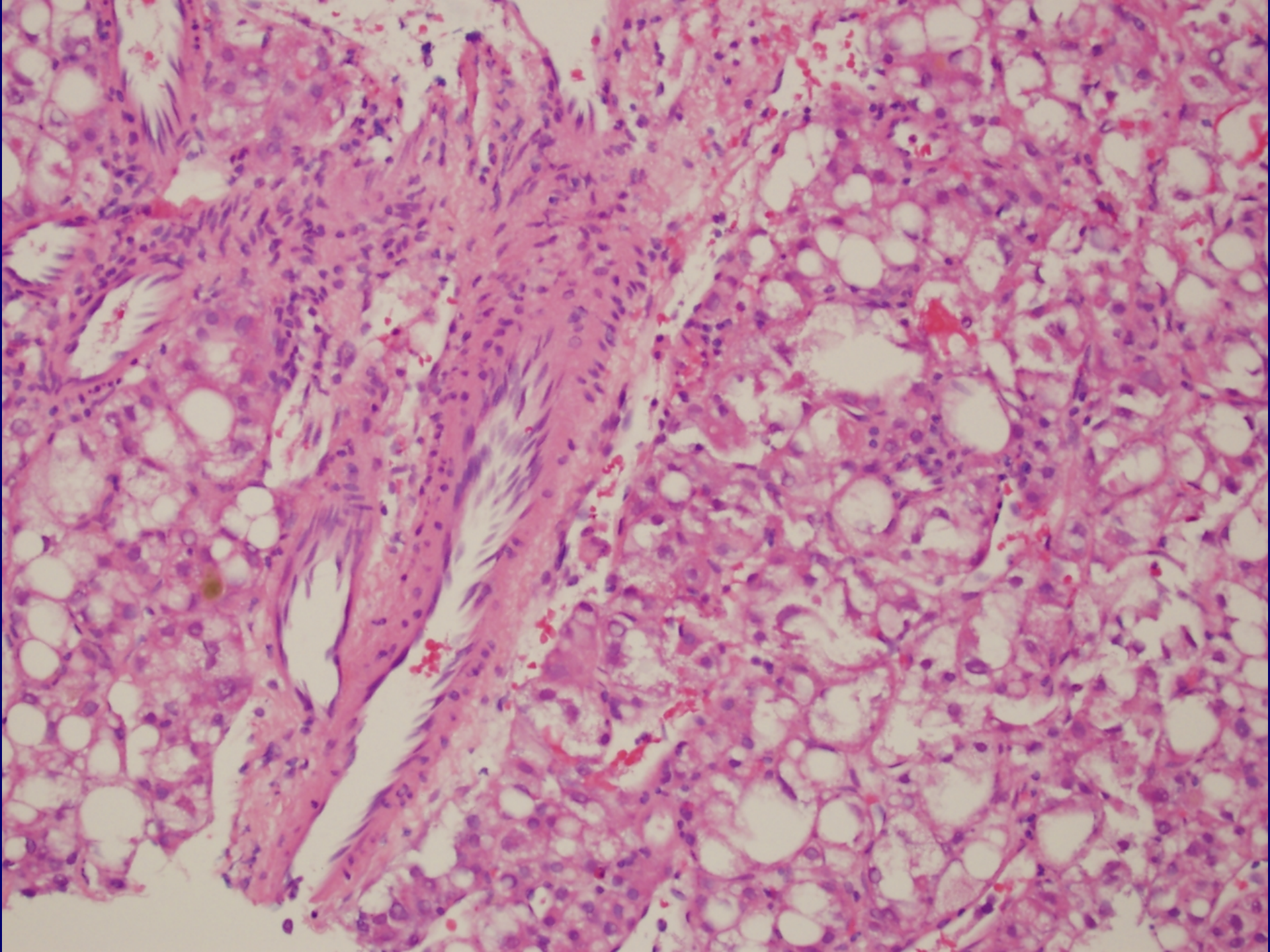

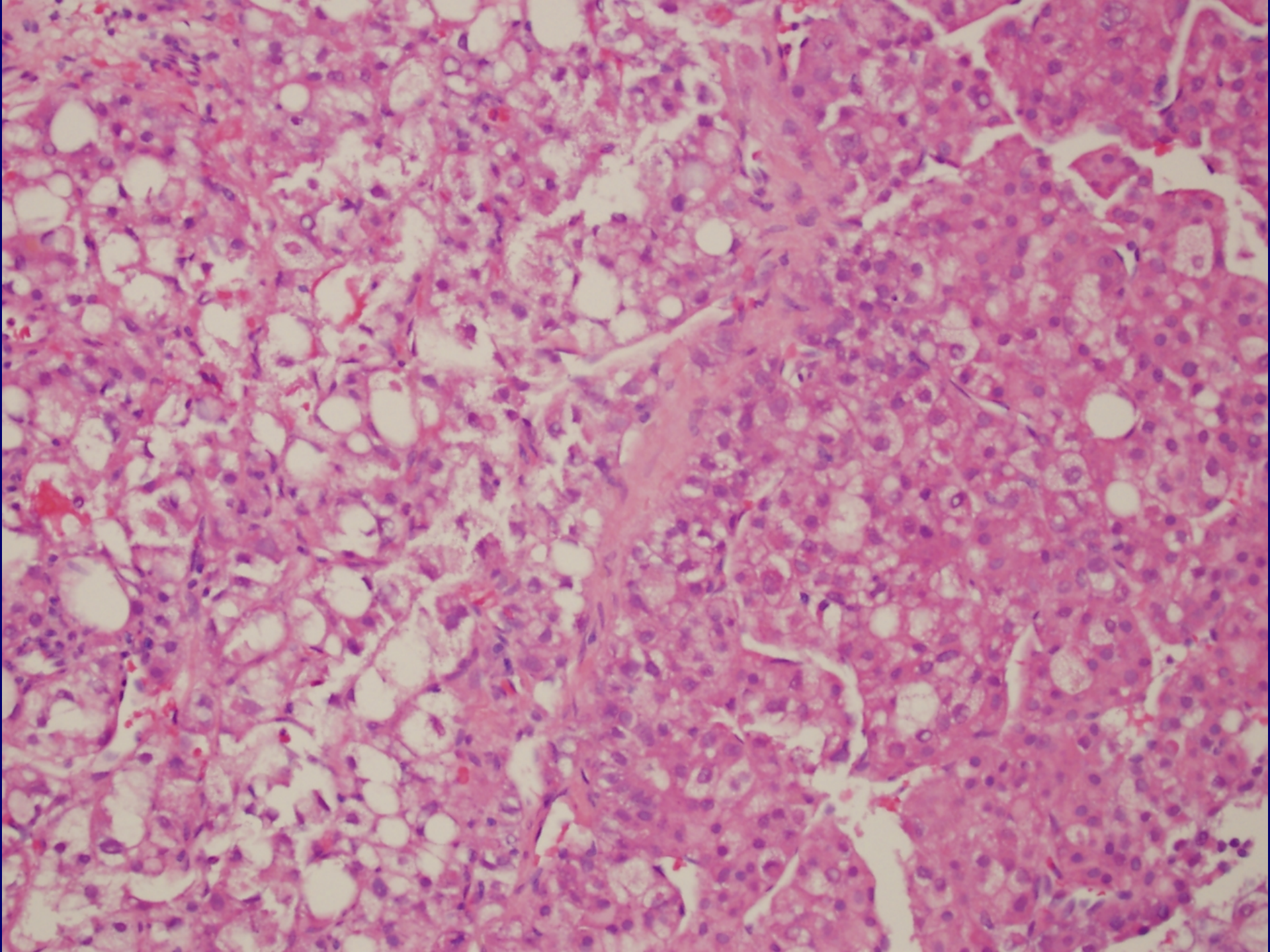

Central scar, no atypia

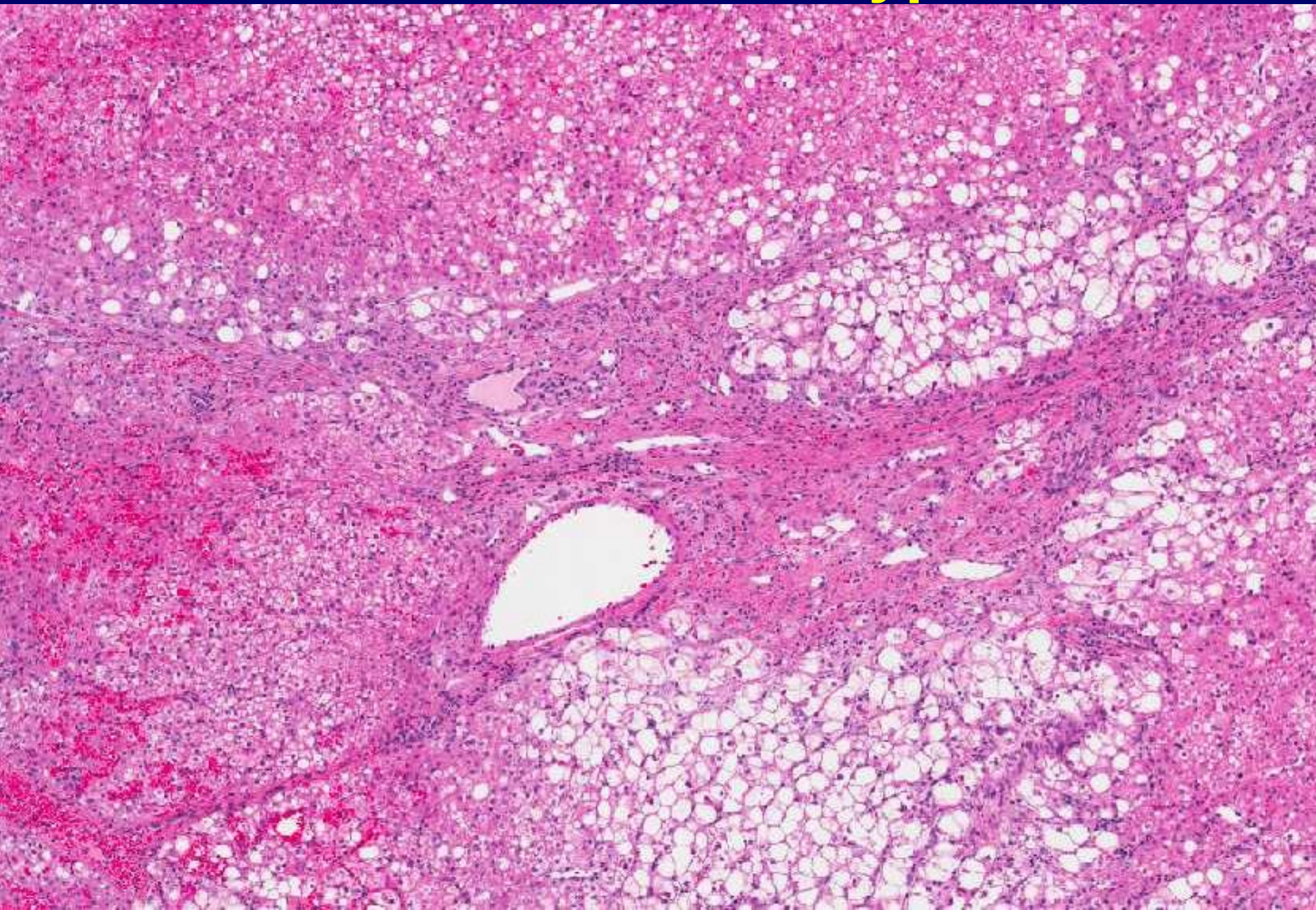

Glutamine synthetase: map-like staining
Diagnosis: FNH with steatohepatitic features

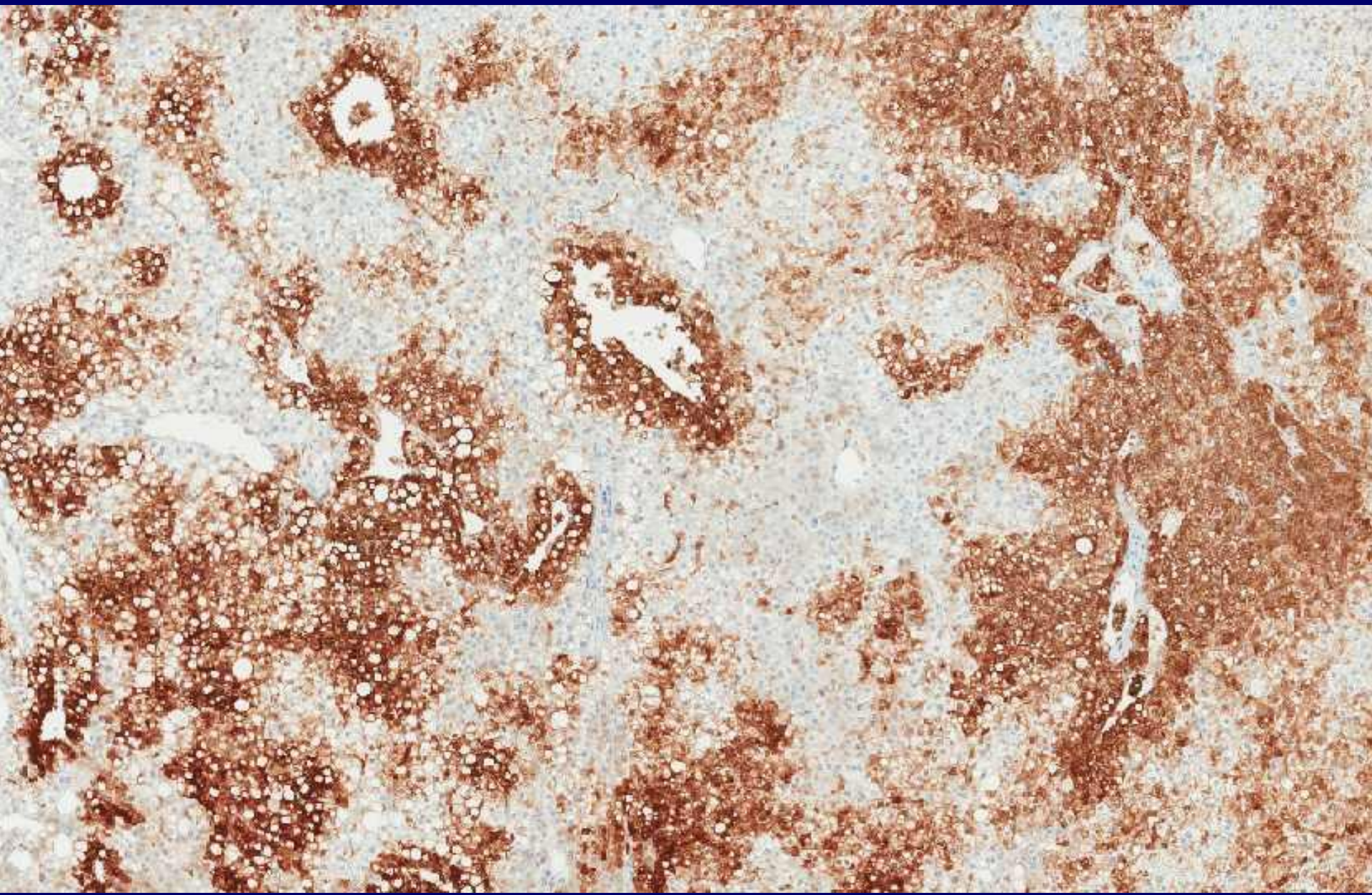

Steatohepatitic HCC
Common pitfalls

Mistaken for steatohepatitis

- Areas of conventional HCC
- Cytologic and architectural atypia
- Glypican-3 +, GS diffuse
- CD34: diffuse sinusoidal staining

Reticulin loss does not indicate HCC

Case 4: 78/M with fever and 3 cm mass, no cirrhosis

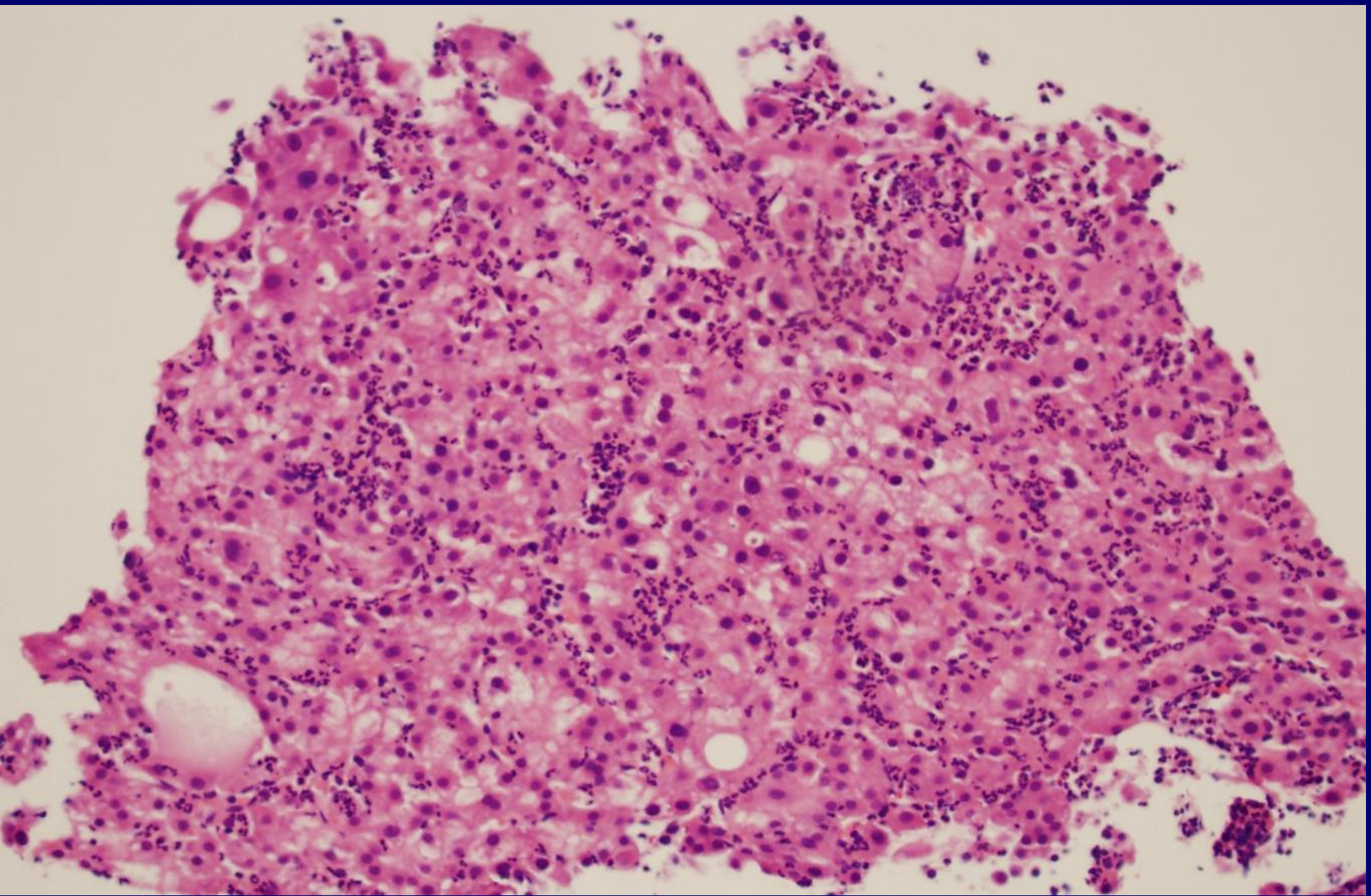

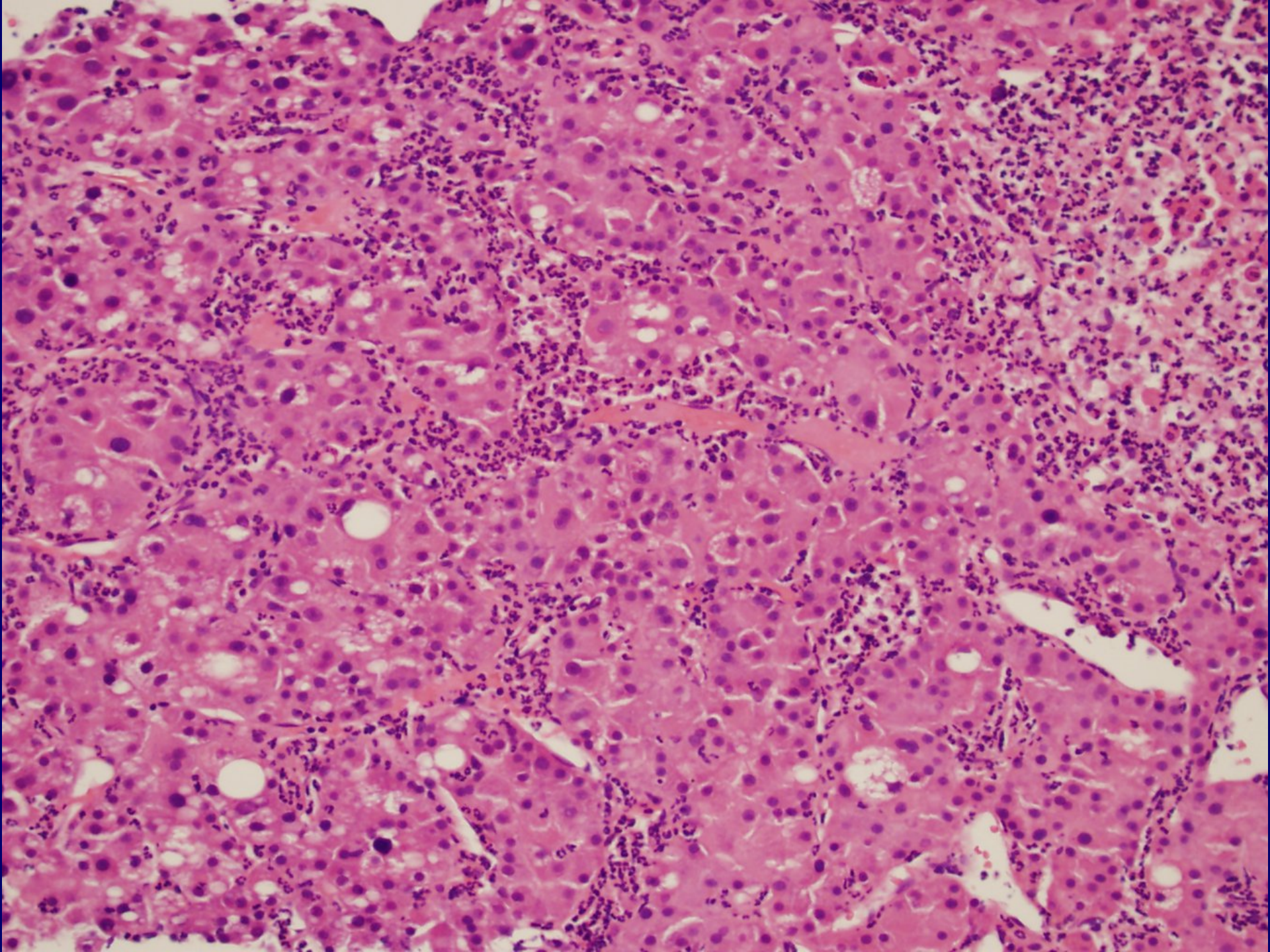

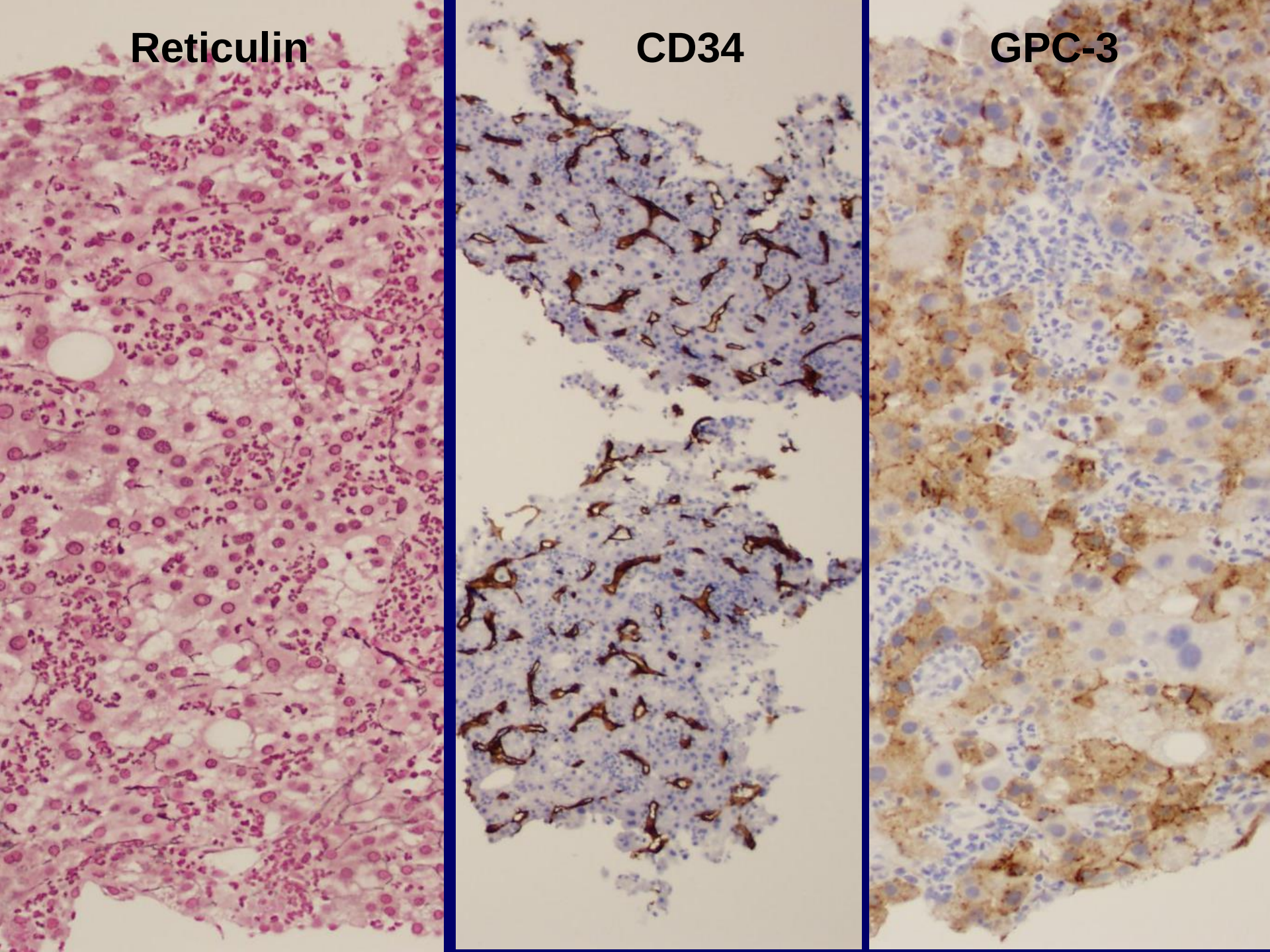
Reticulin
CD34
GPC-3

HCC: G-CSF secreting

Mistaken for an infectious process

- **Abundant neutrophils**
- **Fever, leukocytosis**

Lymphocyte-rich HCC

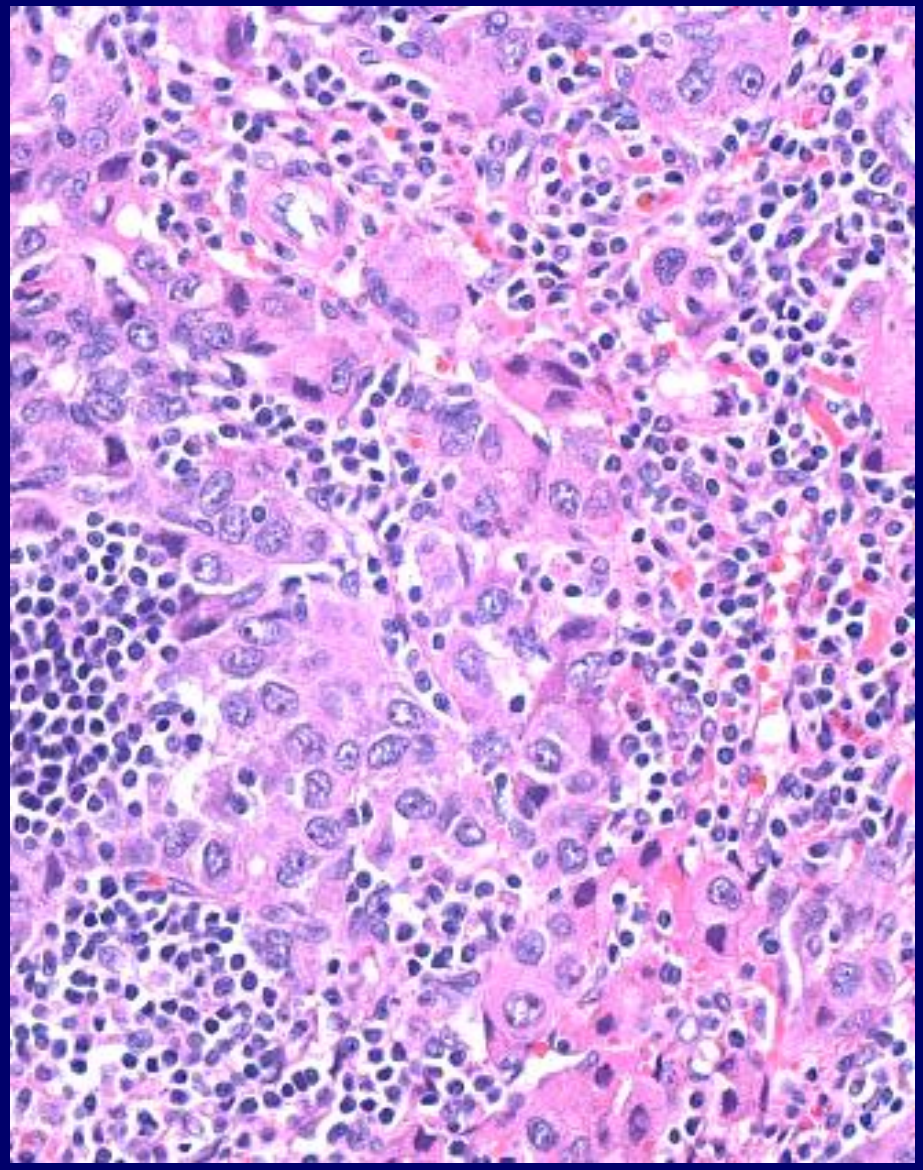

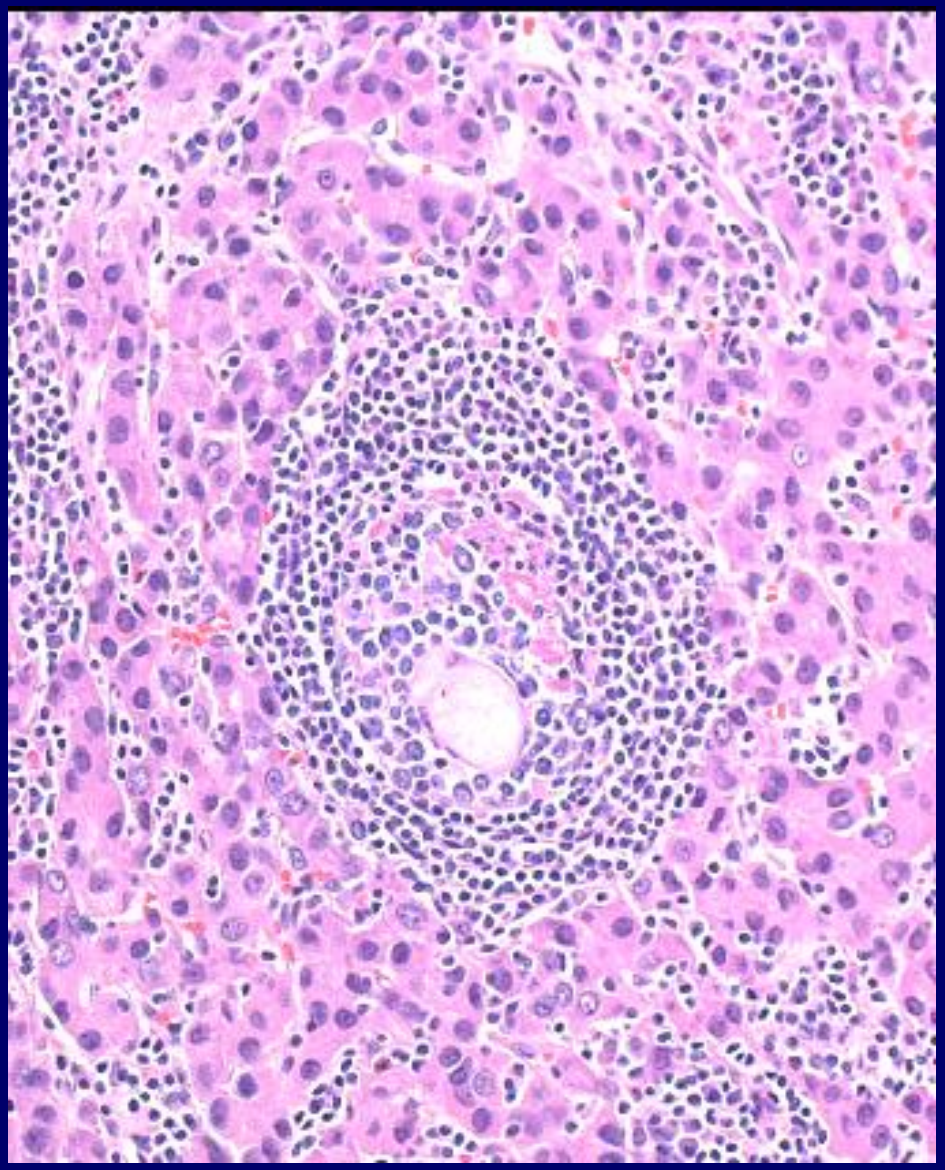

Images: Michael Torbenson, Mayo Clinic

65/M with fever and 4 cm liver mass

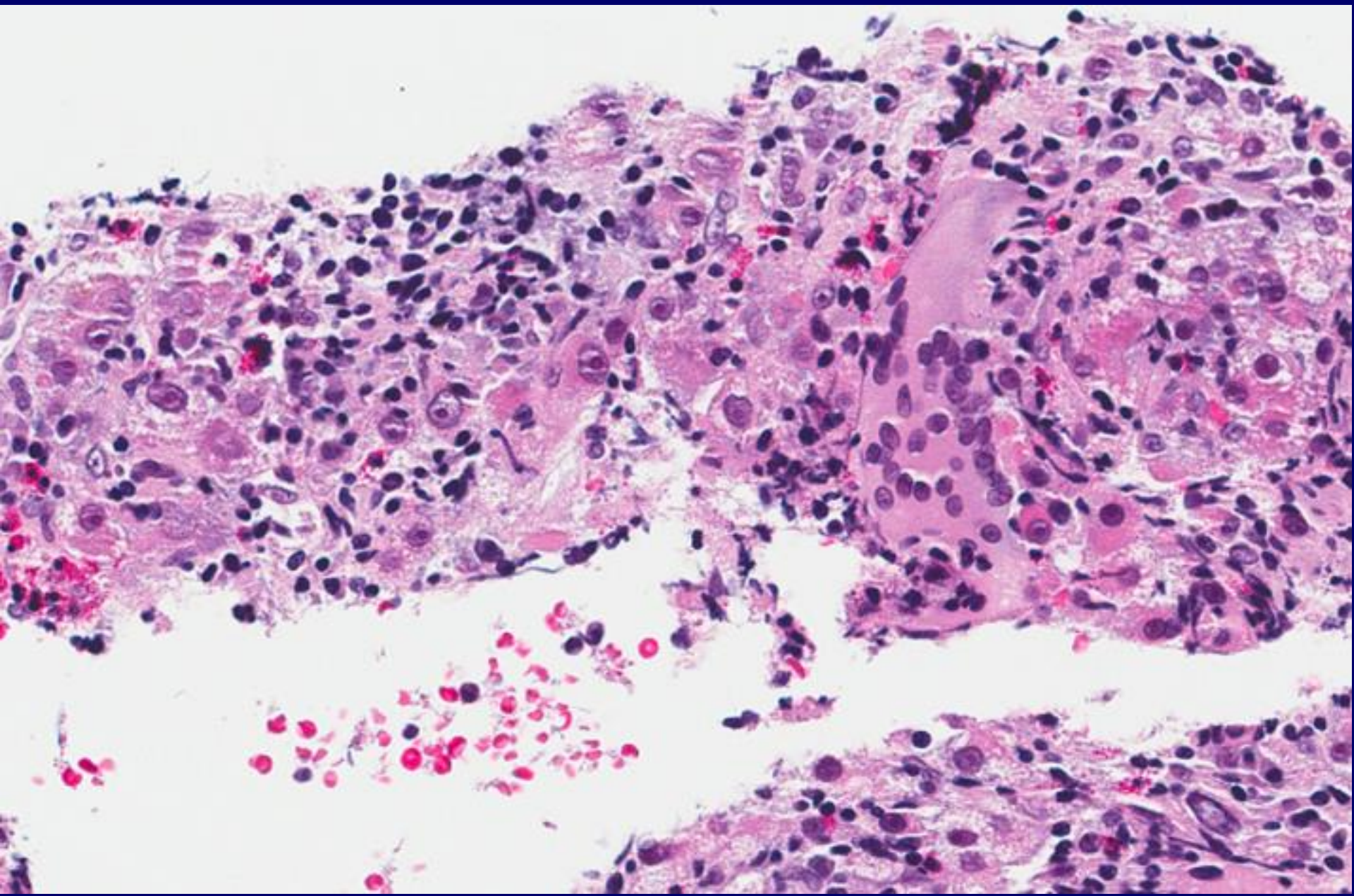

Marked inflammation, granulomas

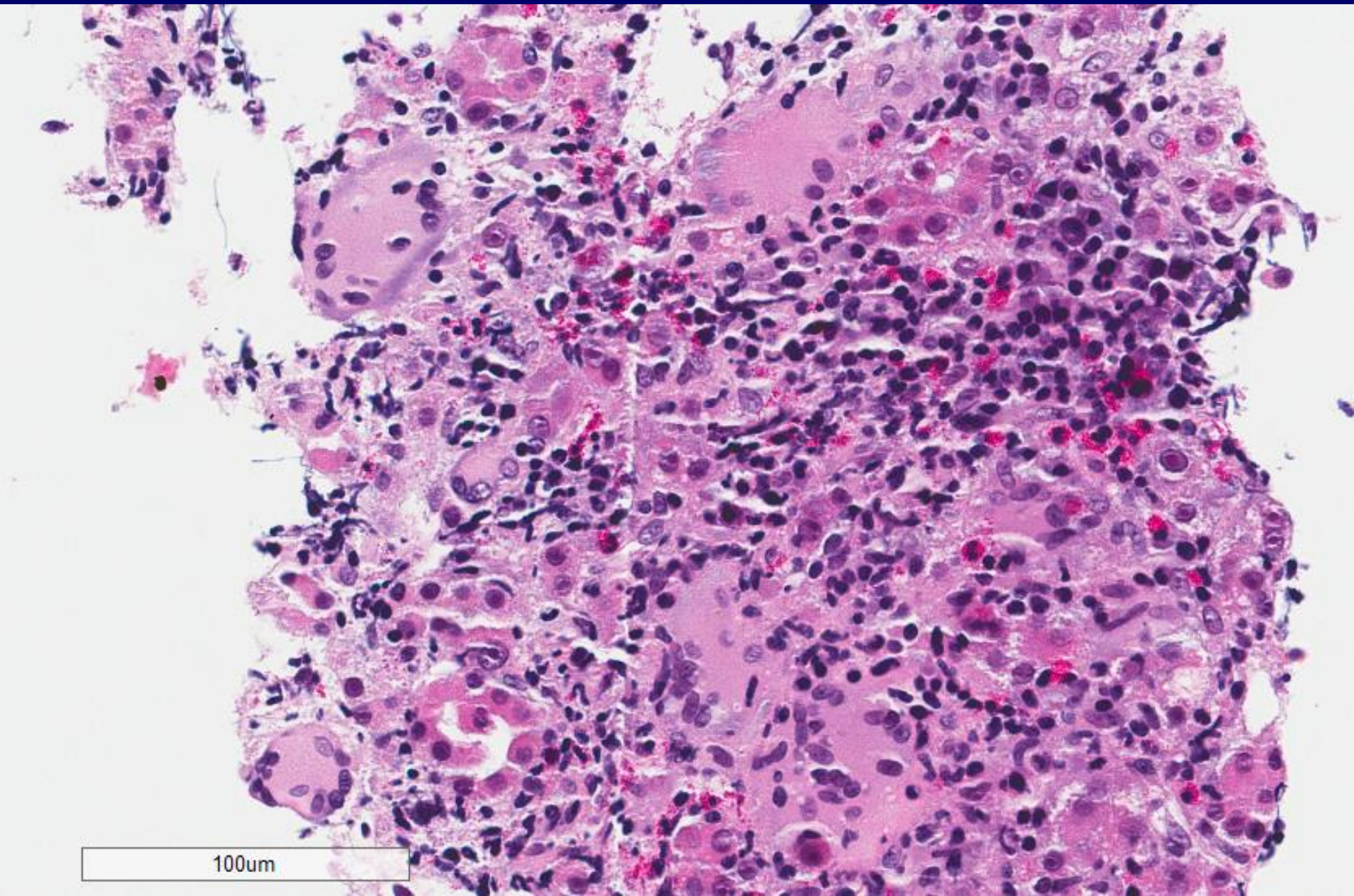

Inflammation, cells with prominent nucleoli

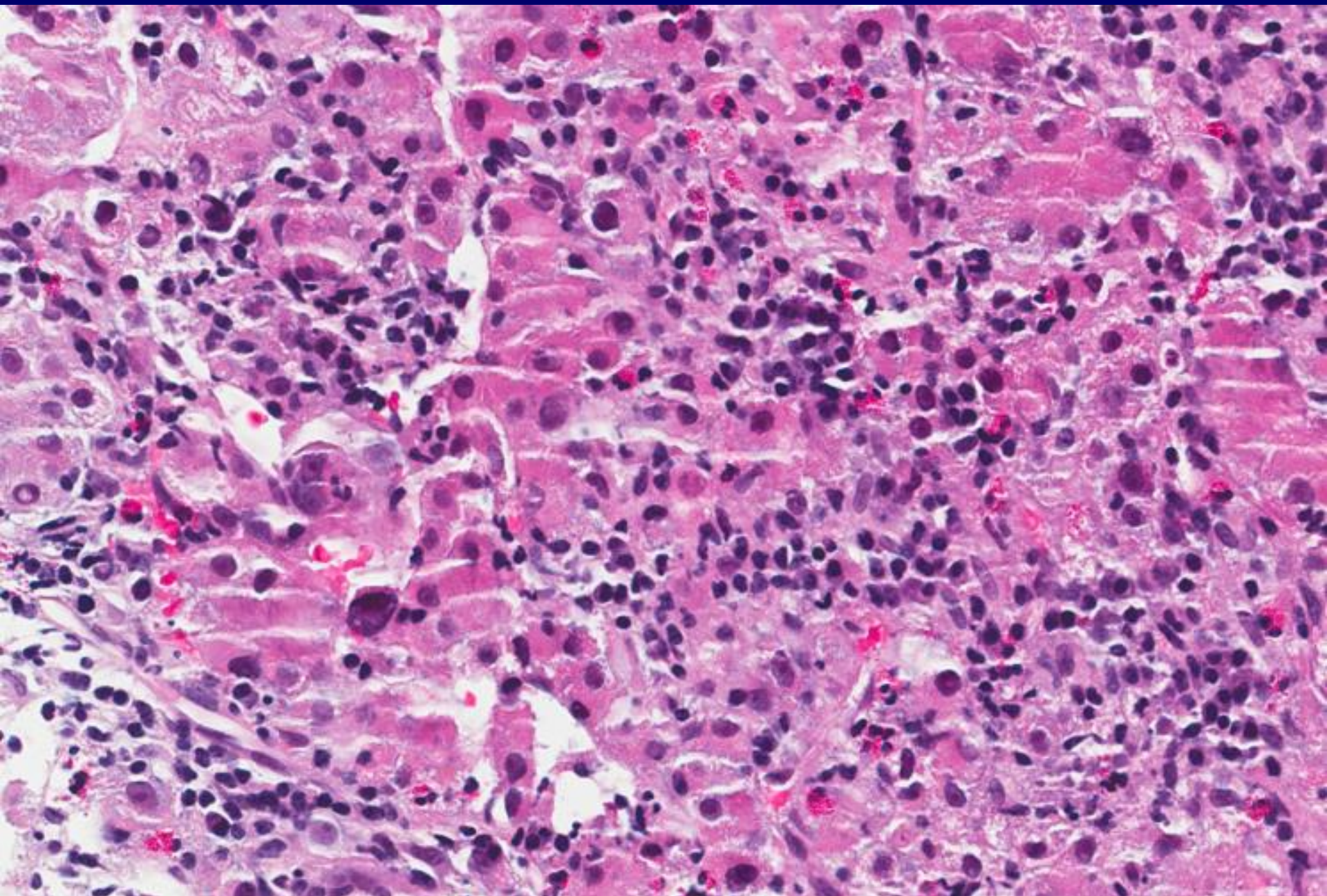

Arterioles without bile ducts

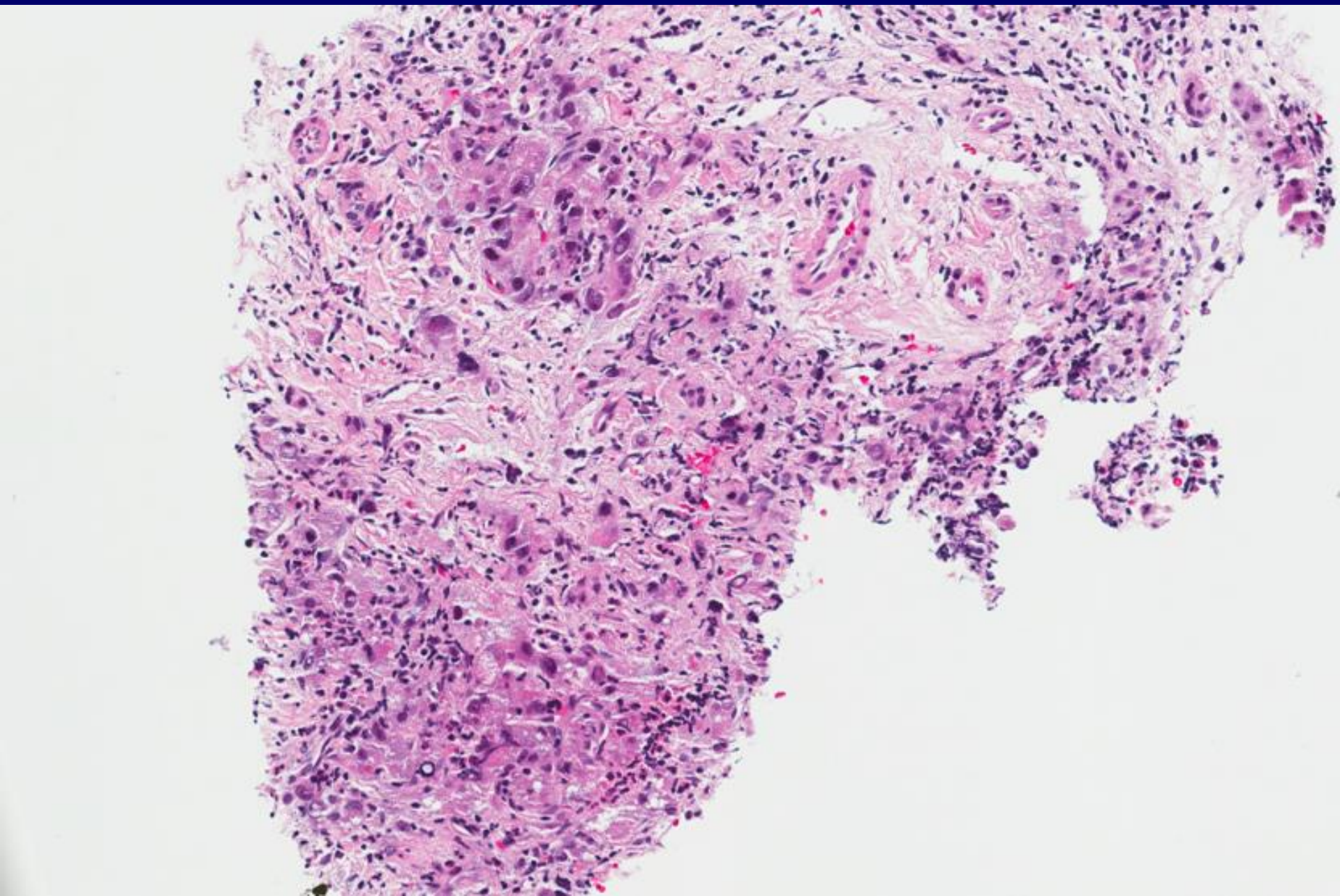

Diffuse glutamine synthetase
Indicates β-catenin activation

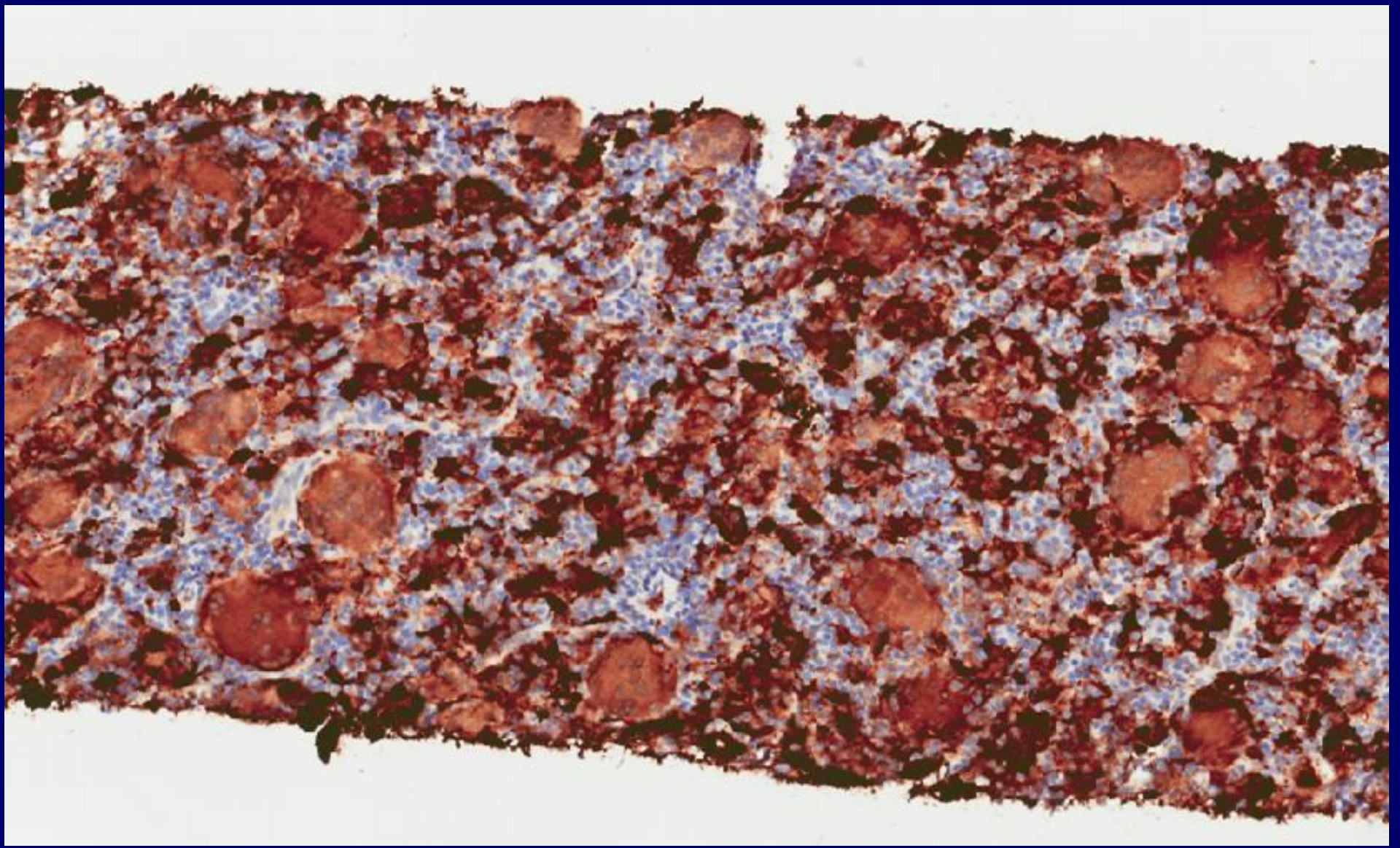

Sarcomatoid HCC

- Sarcomatoid component
  - Spindle, epithelioid, mixed
  - Heterologous differentiation
- HCC component
  - Necessary for diagnosis

Case 5: 70/M with 5 cm liver mass

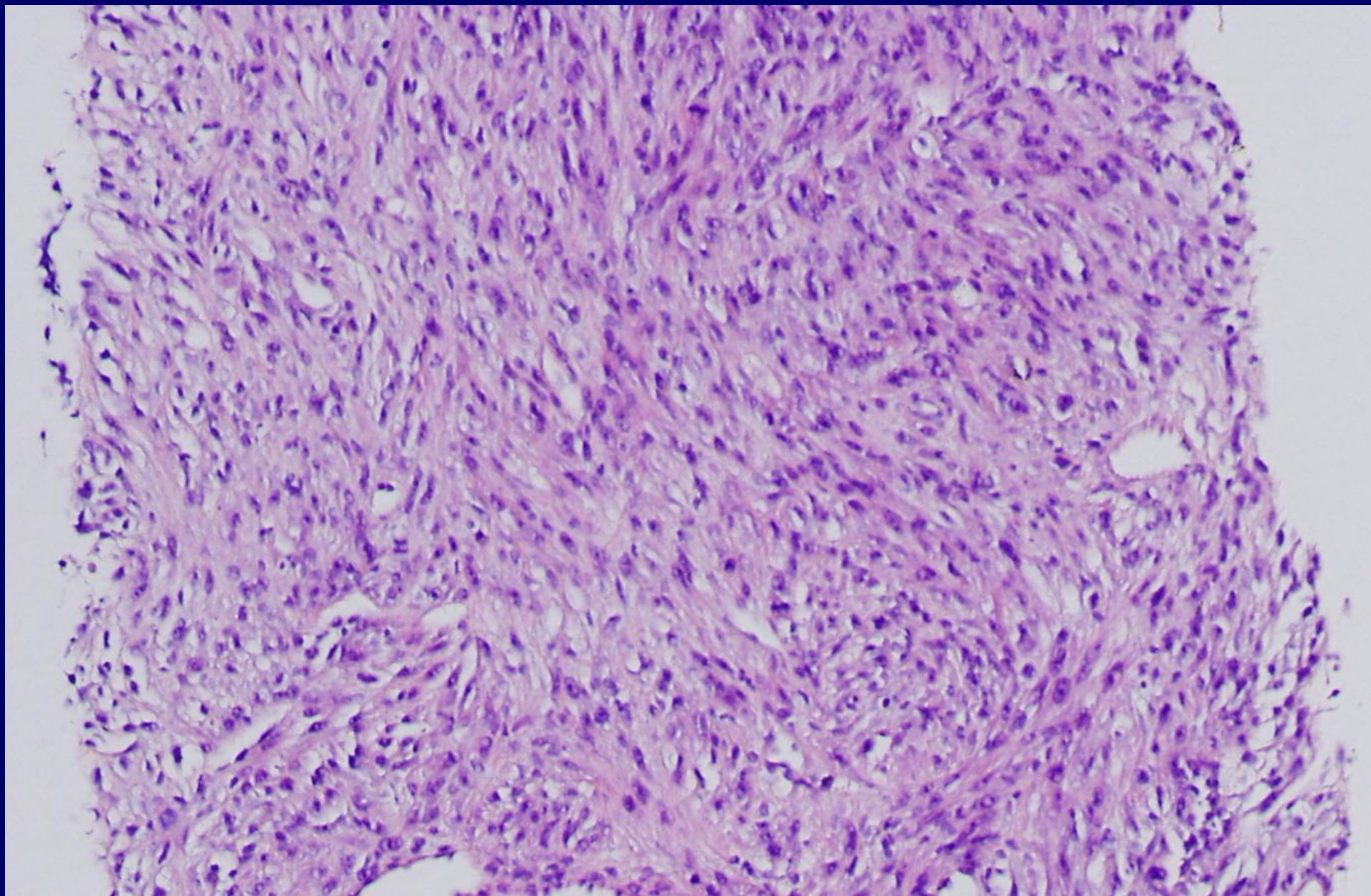

Sarcomatoid HCC

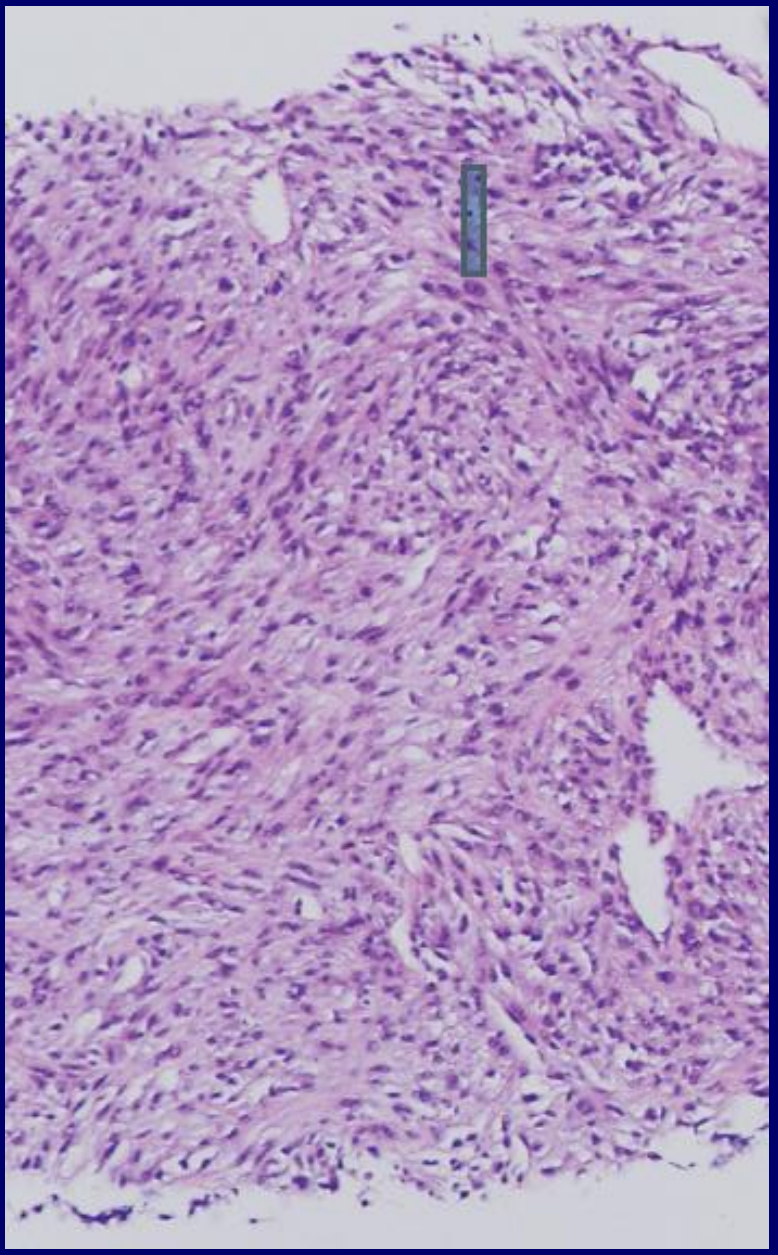

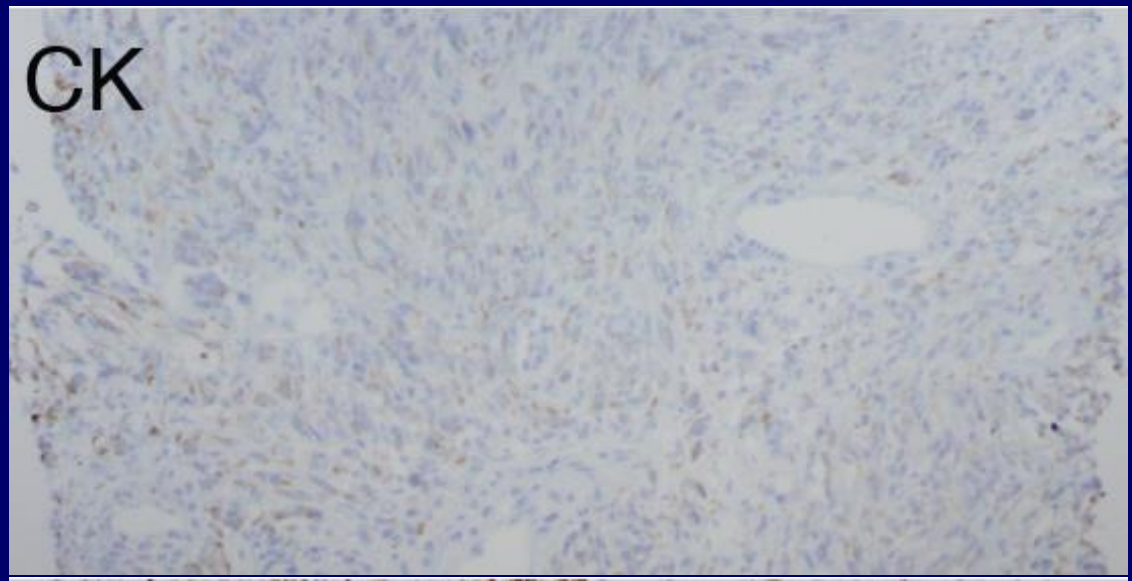

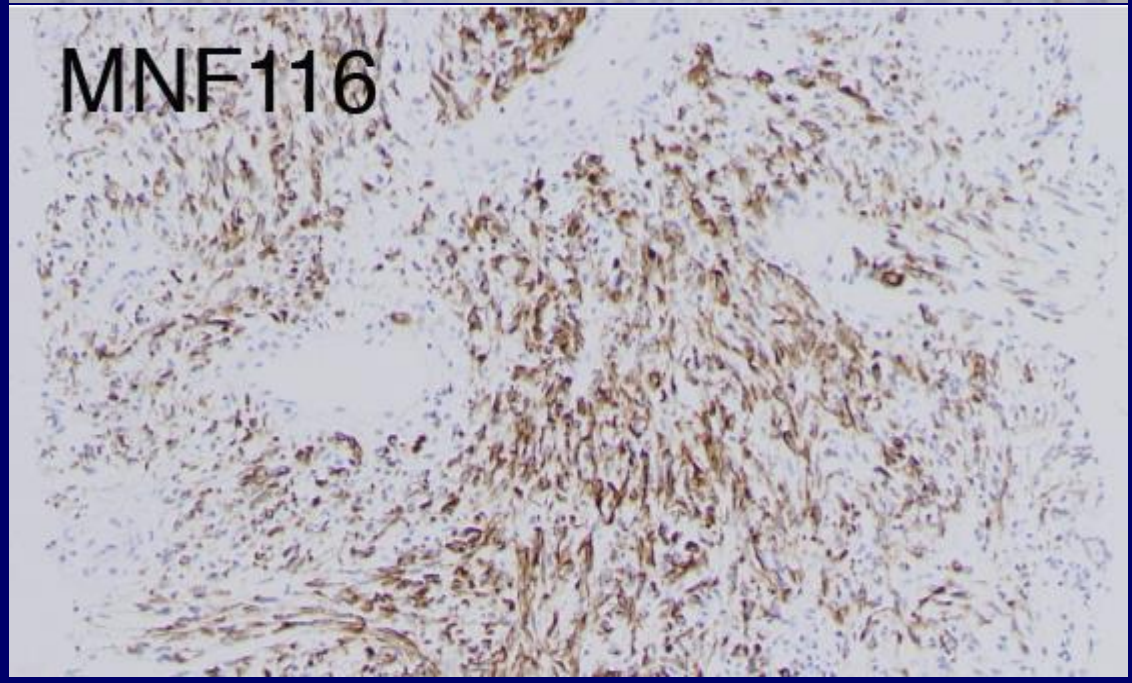

Nguyen/Kakar, USCAP 2013

Sarcomatoid HCC

- Panel of keratin antibodies
- HCC component necessary
- Other spindle cell tumors

DOG1, KIT: GIST

SMA, desmin: Smooth muscle tumors
Angiomyolipoma

Myogenin: RMS

S-100/SOX10: MPNST/melanoma

MDM2/CDK4: Dediff LPS

Combined HCC-CC

WHO definition

- A tumor containing intimately mixed elements of both HCC and CC

HCC-like area

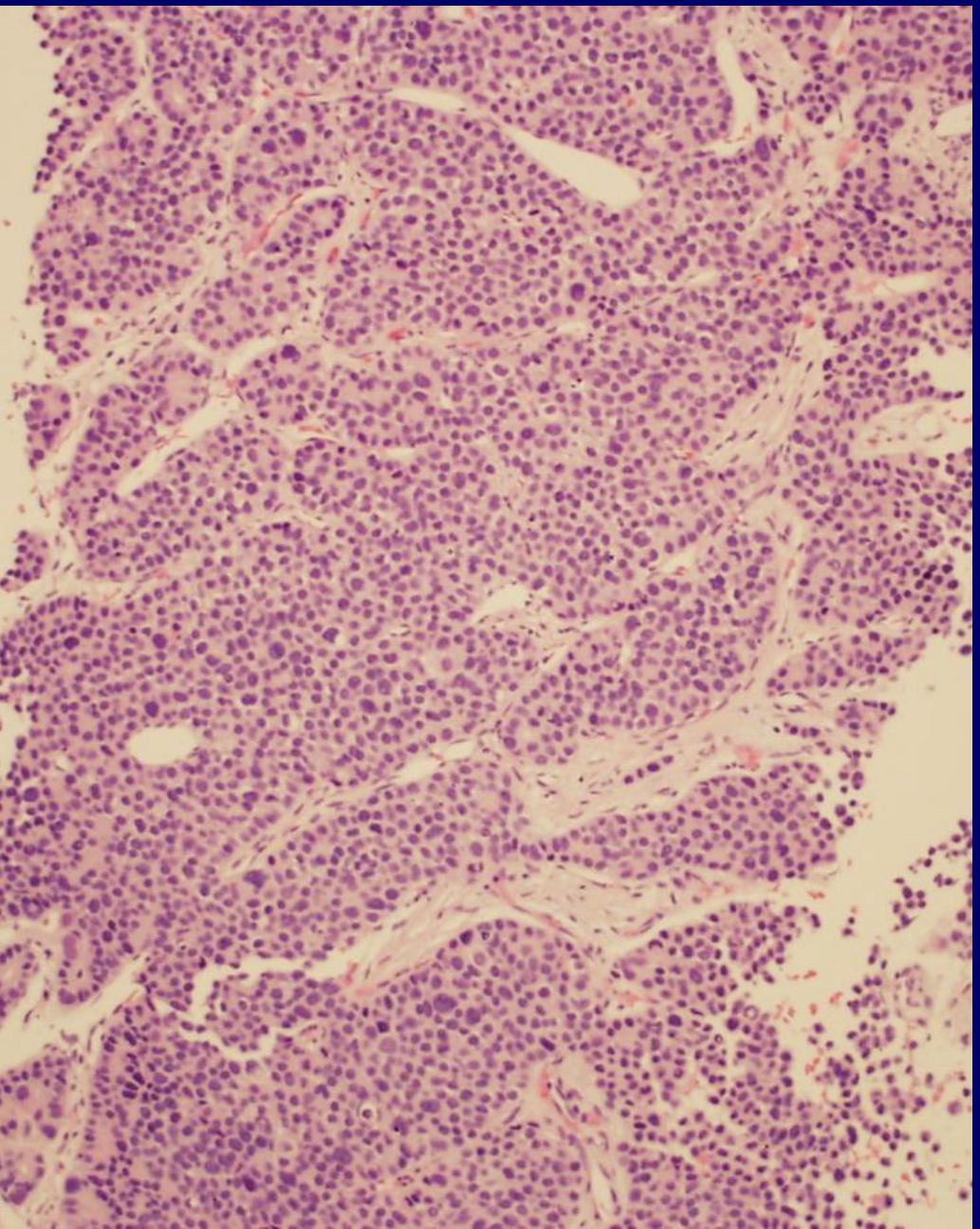

Well-formed glands

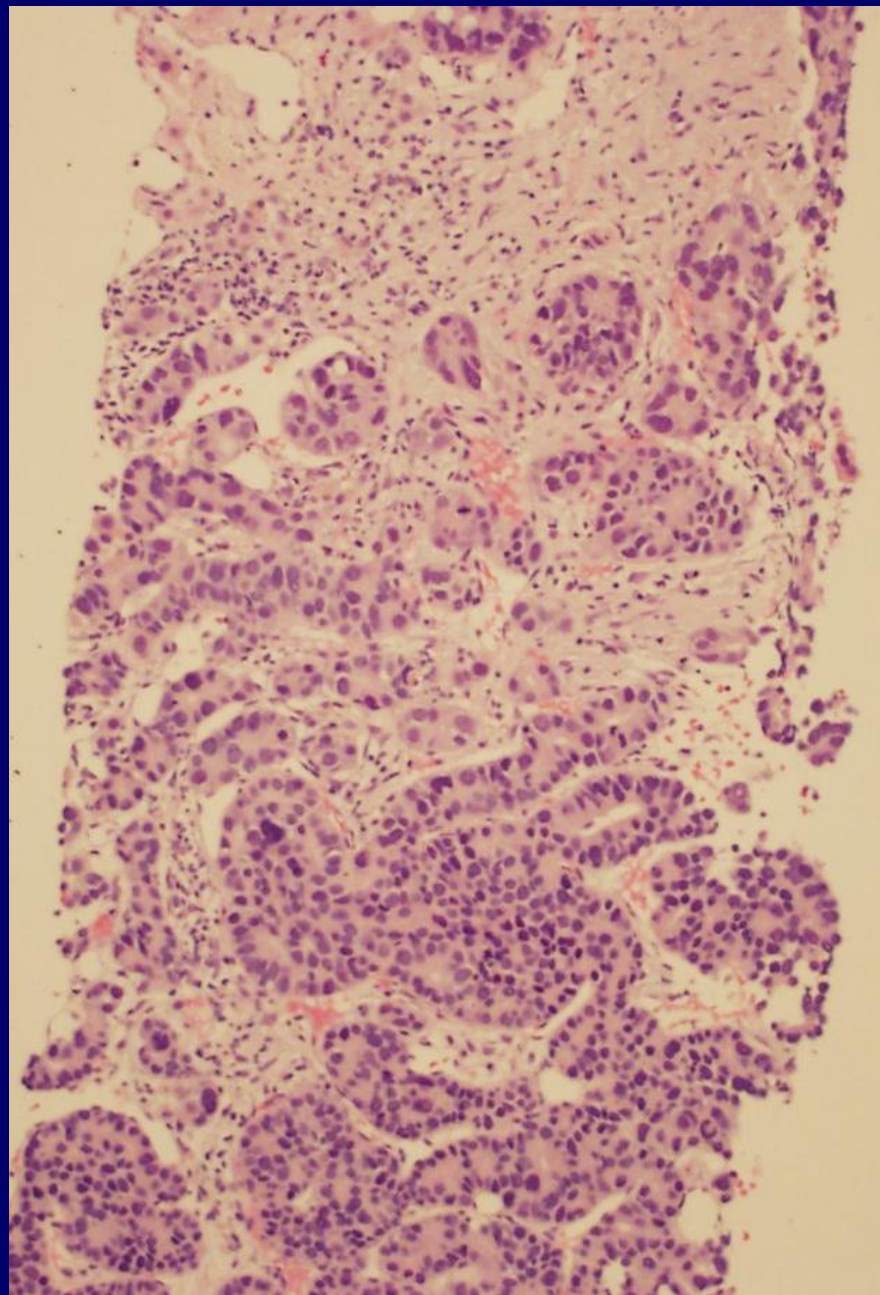

Arginase-1

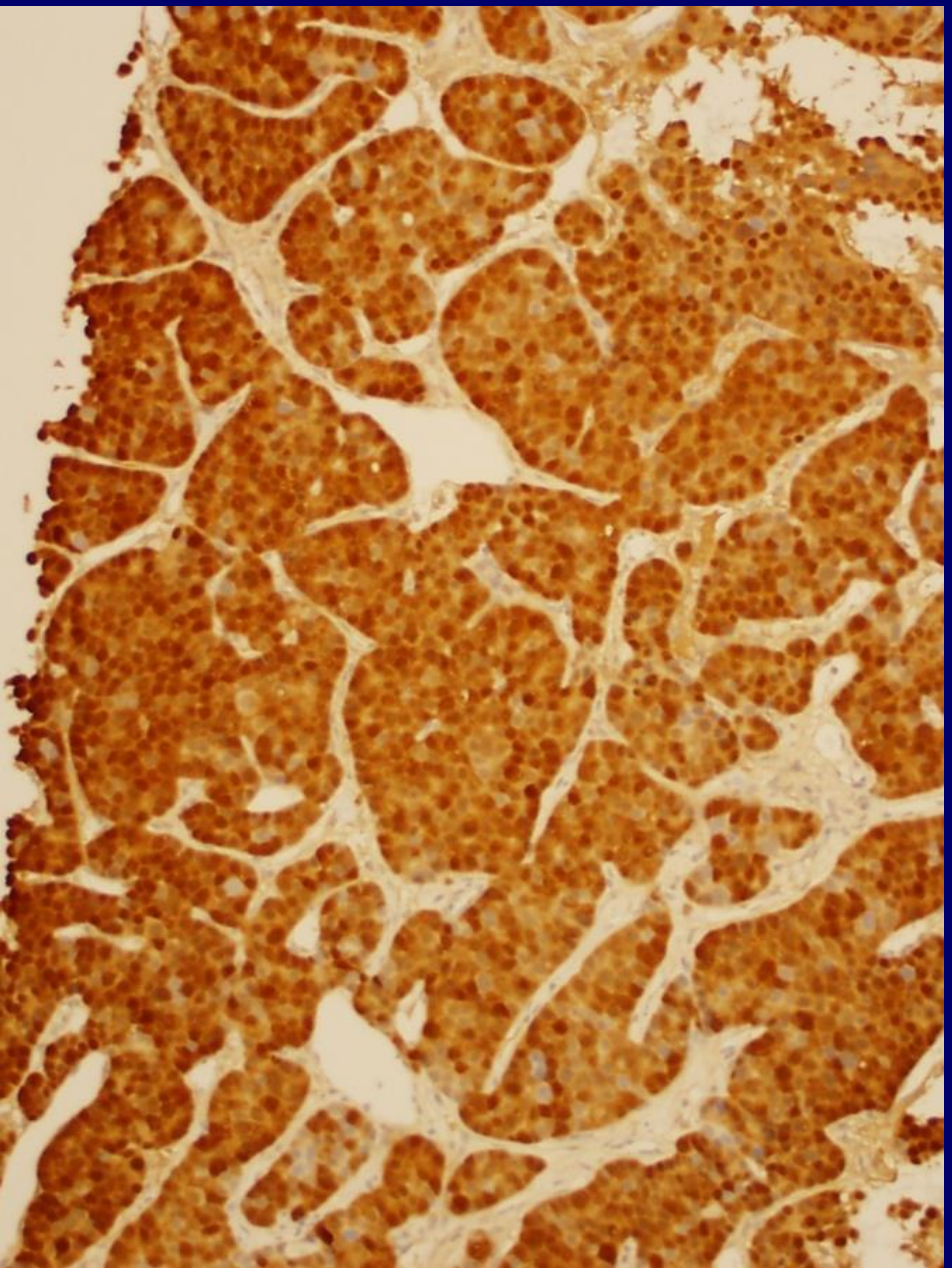

CK19

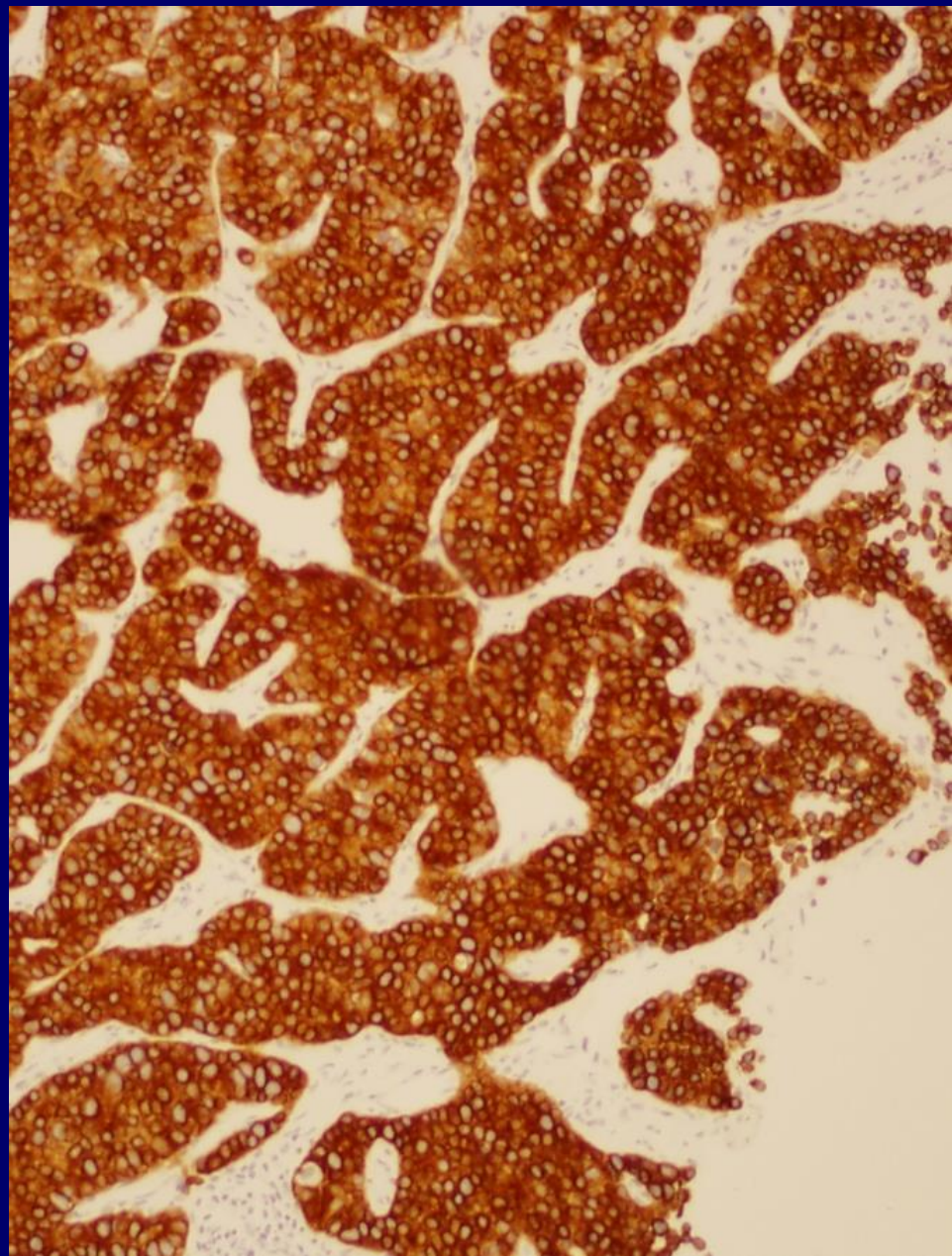

Arginase-1

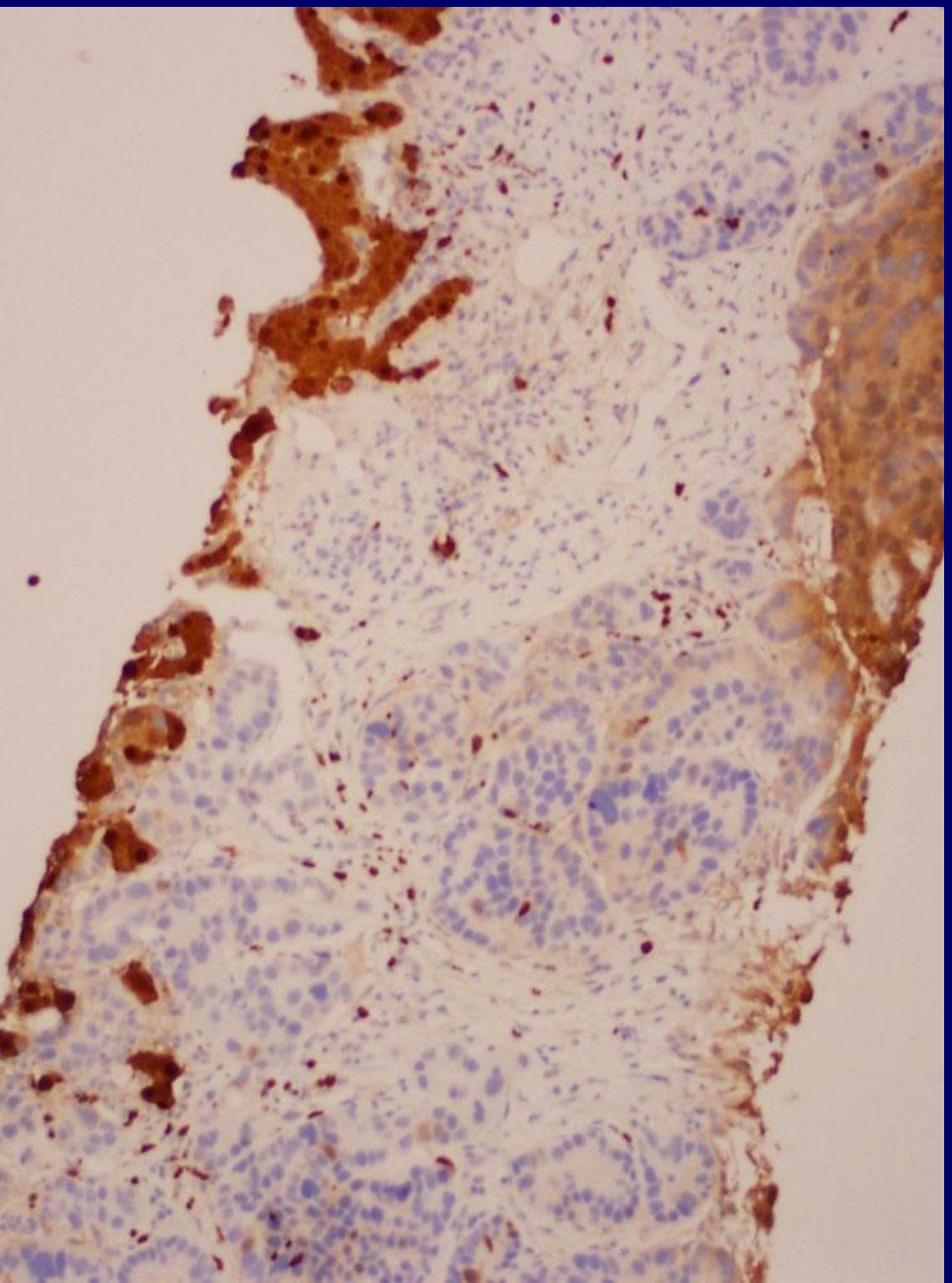

CK19

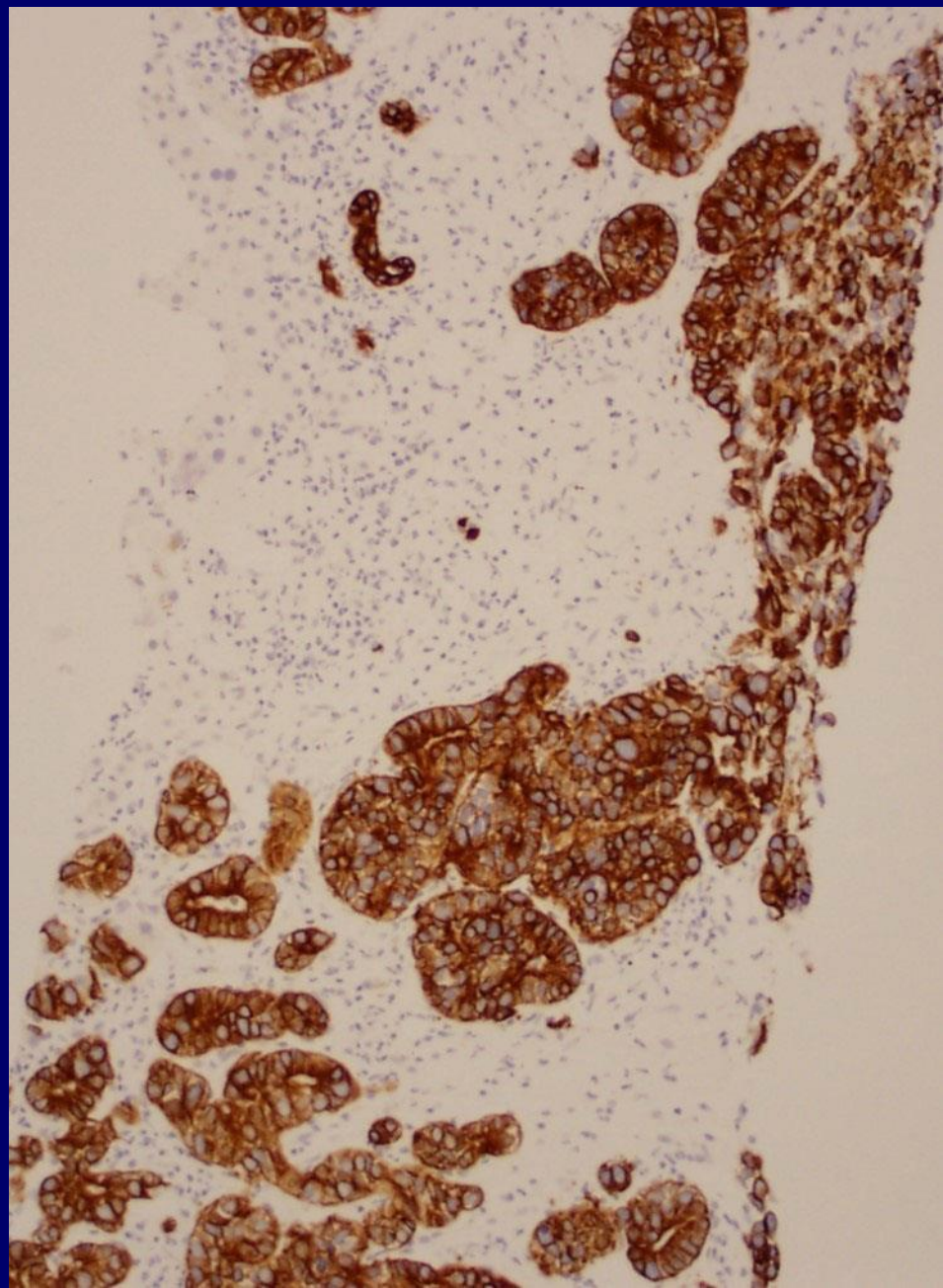

Combined HCC-CC

Problems in diagnosis

- HCC with pseudoglands vs cholangiocarcinoma
- CC with solid areas vs HCC

Combined HCC-CC

HCC

- Morphology, arginase-1
- Use additional markers: Hep Par 1, GPC-3, pCEA *(CD10, AFP)*
- CK19: can be positive

CC

- Discrete glands, mucin ±
- Negative arginase-1
- CK7, CK19 and/or MOC31

Cholangiocarcinoma

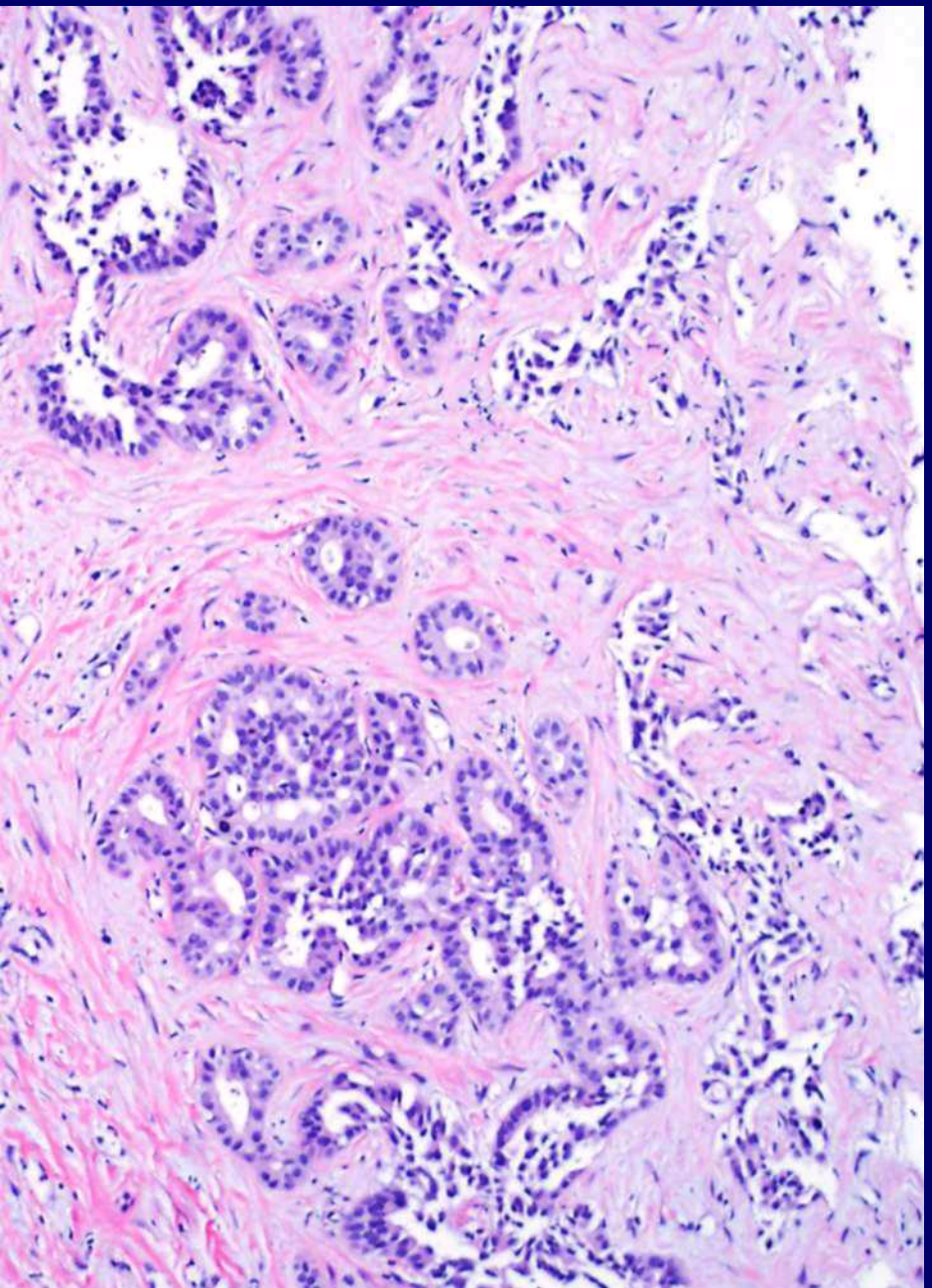

HCC-like area

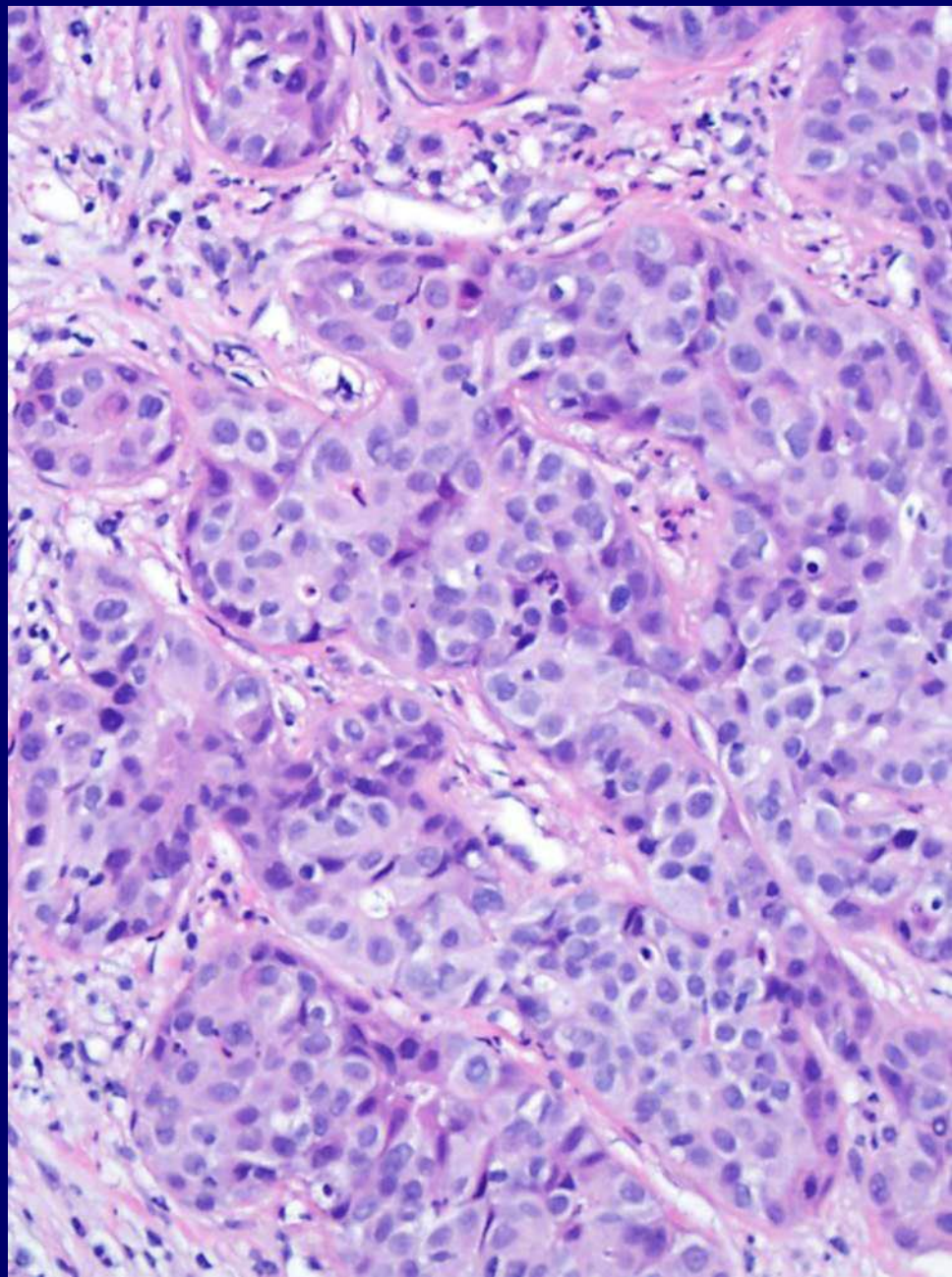

HCC-like area

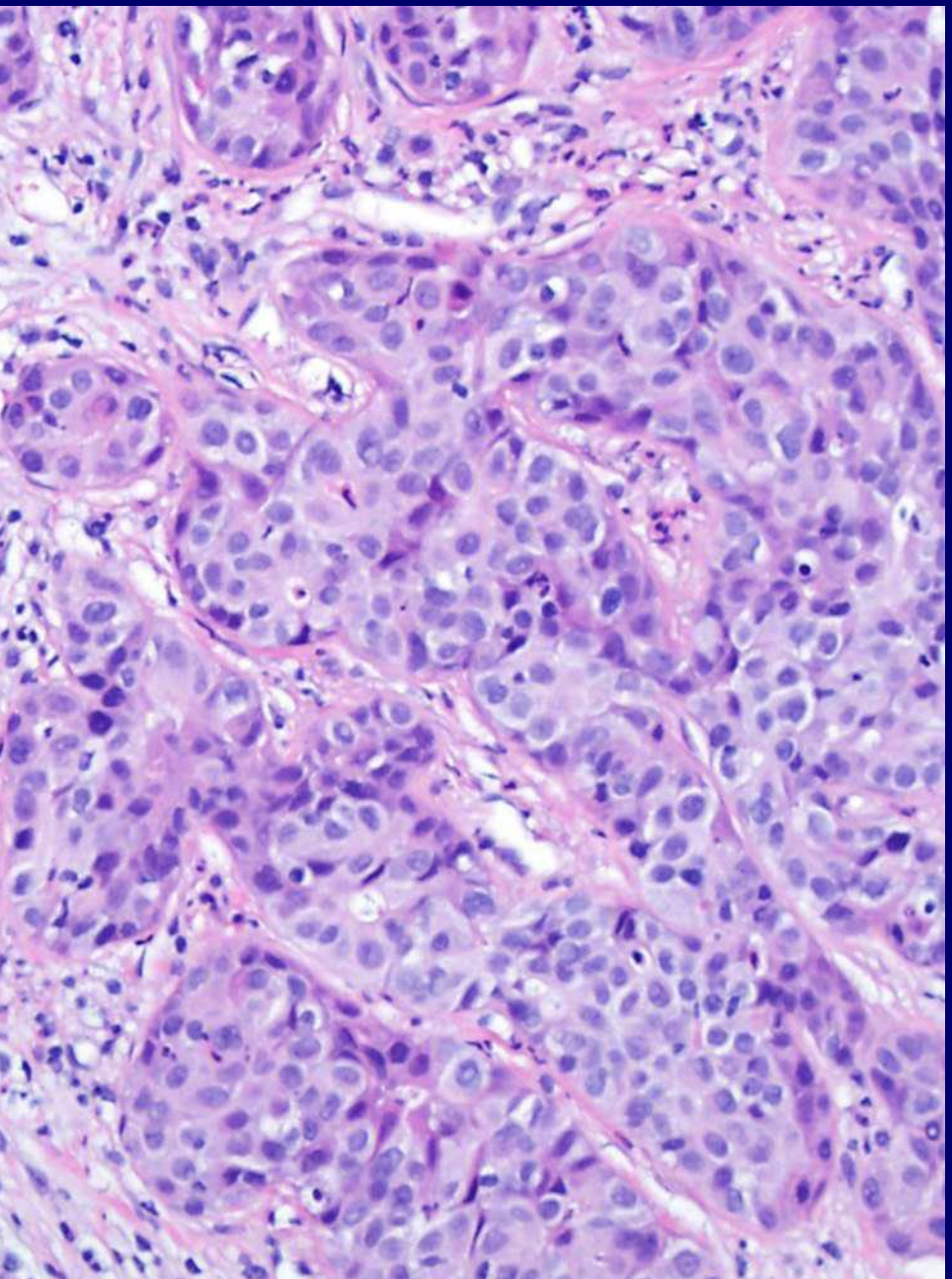

CK19+ (Arg neg)

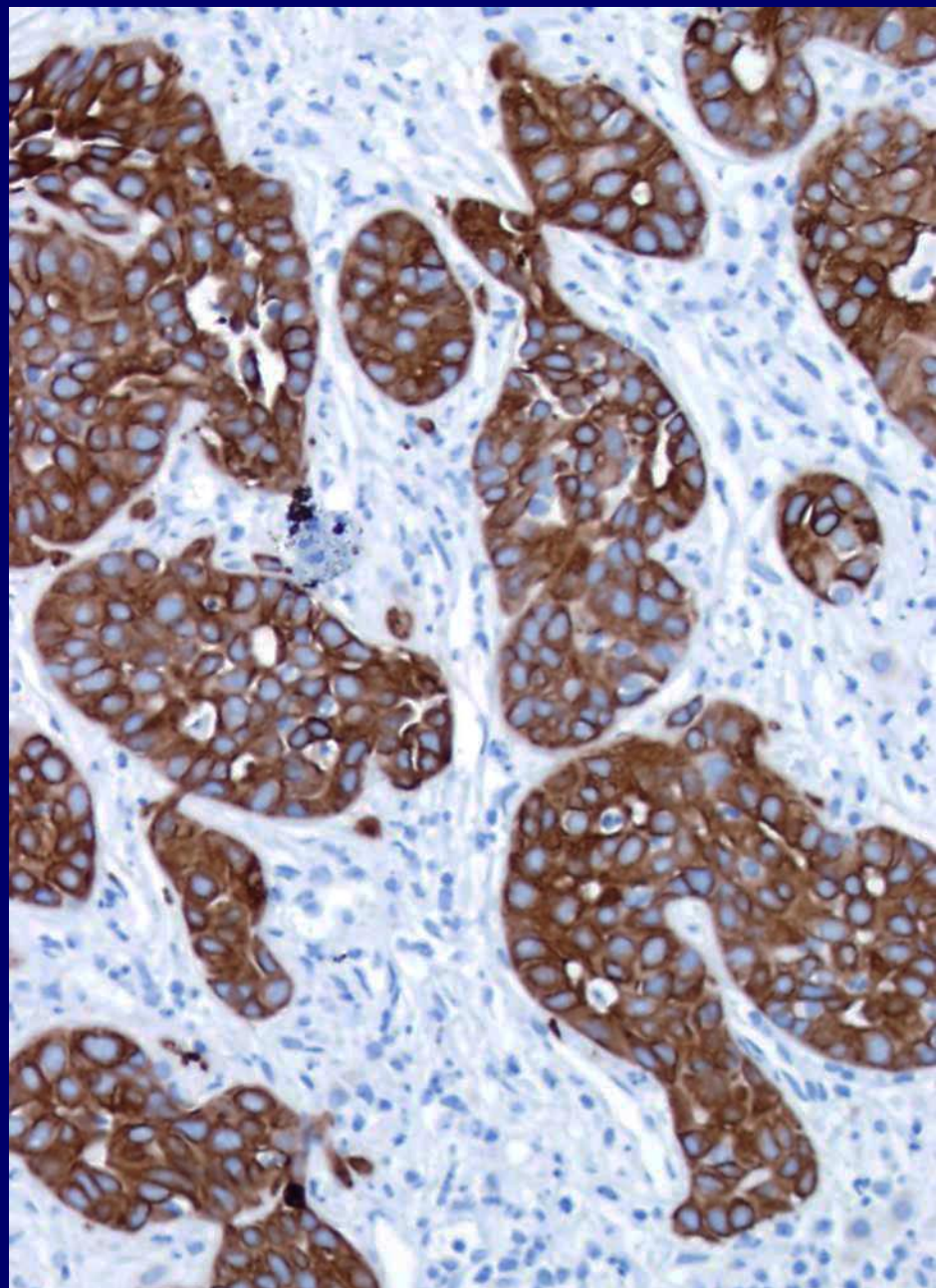

HCC or CC: clinical impact

HCC	Cholangiocarcinoma
Lymph nodes may not be removed	Lymph node dissection is routine

HCC	Cholangiocarcinoma
Sorafenib, transarterial chemoembolization	Gemcitabine-based or fluoropyramidine-based

HCC	Cholangiocarcinoma
Liver transplant: Milan/UCSF criteria	Likely denial

Case 6: 54/M, Hep C, no cirrhosis, 5 cm liver mass

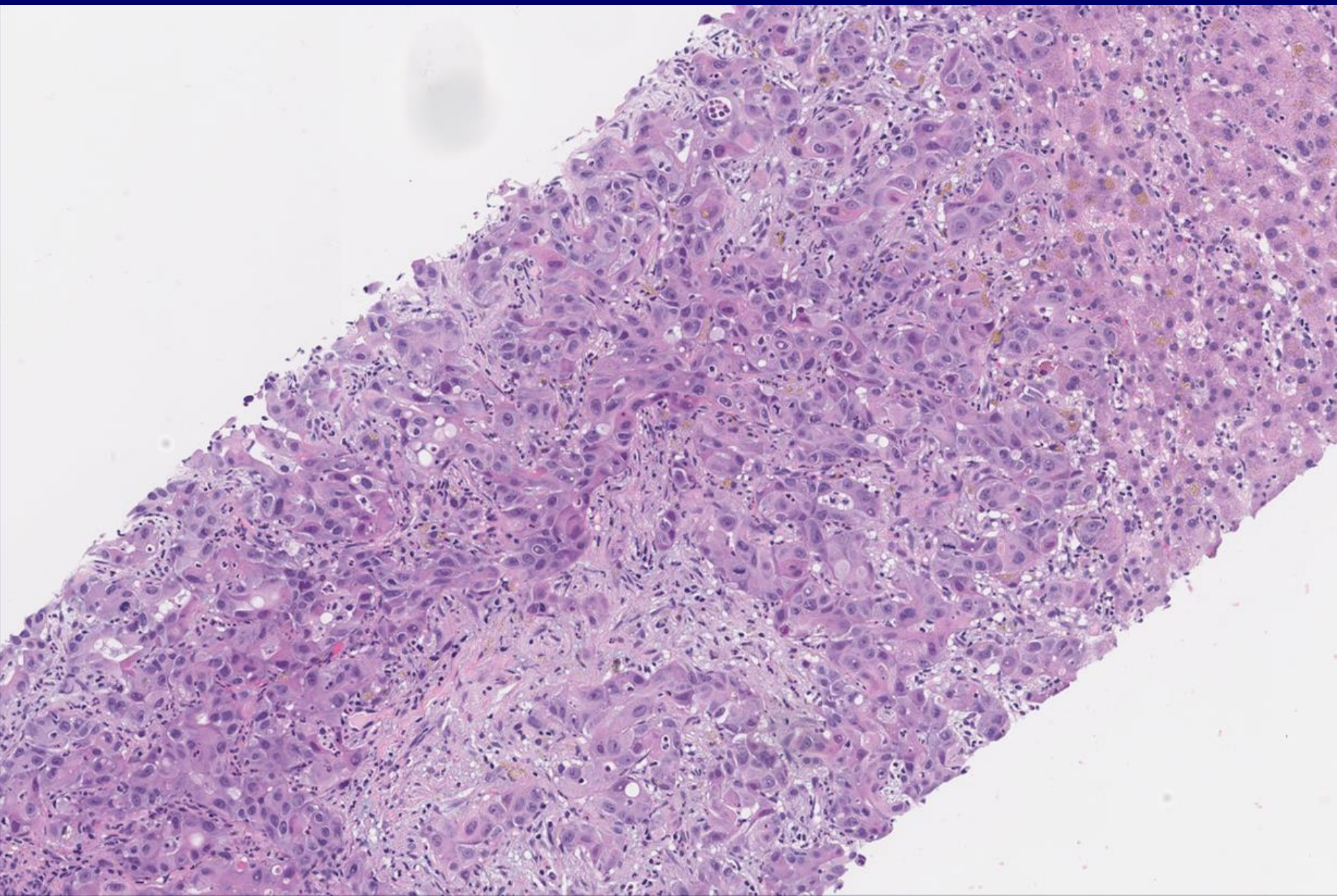

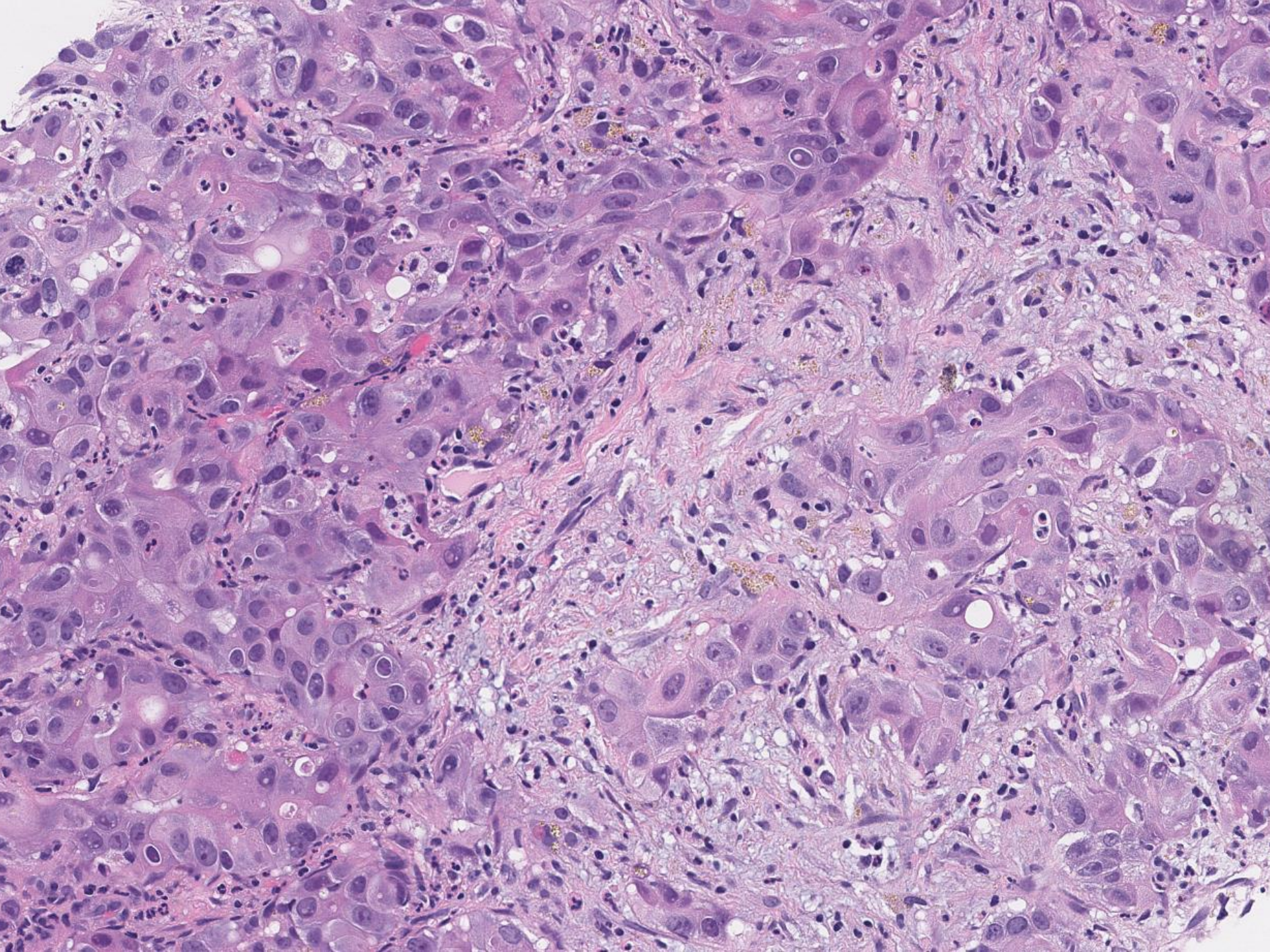

CK19

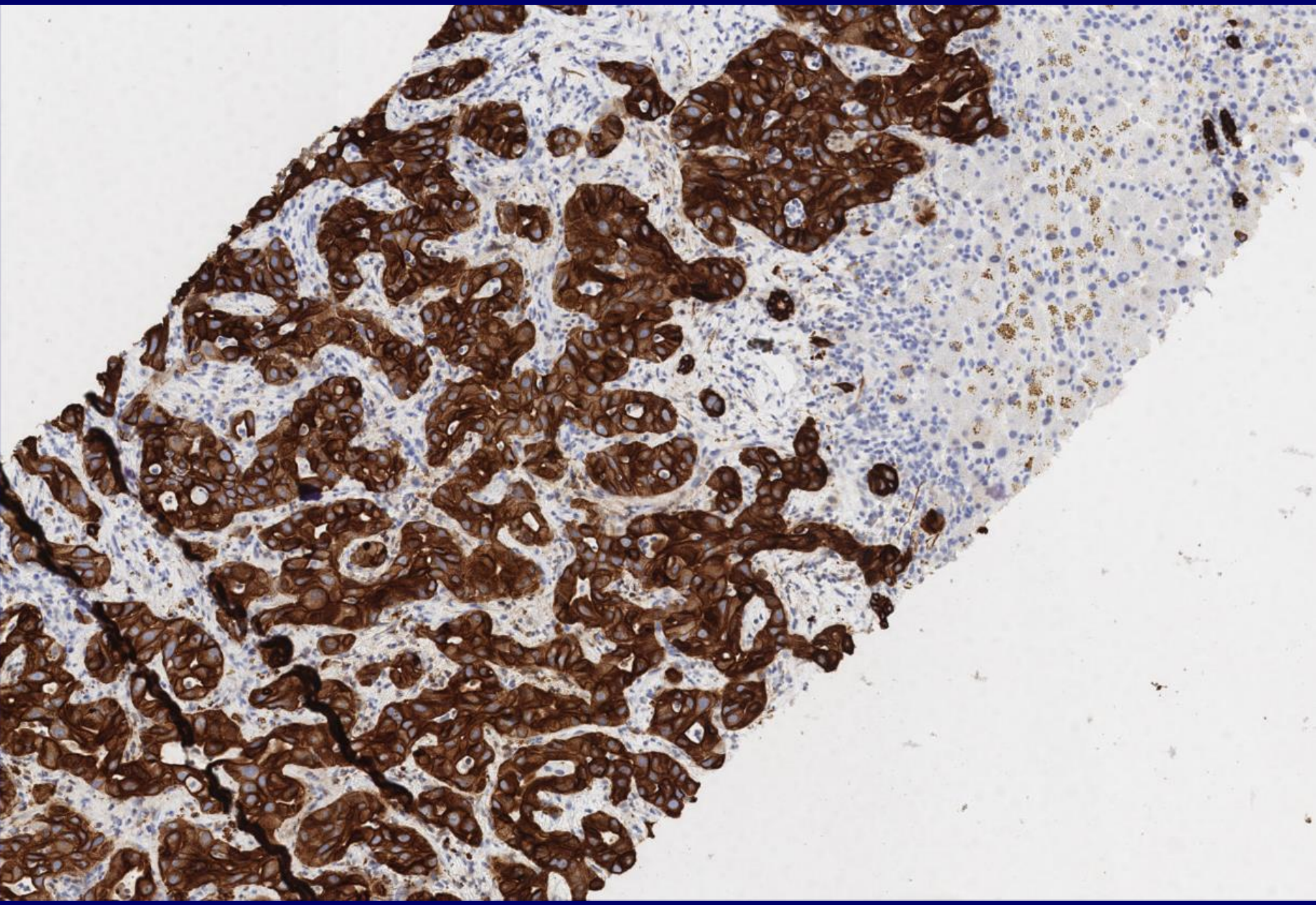

Hep Par 1

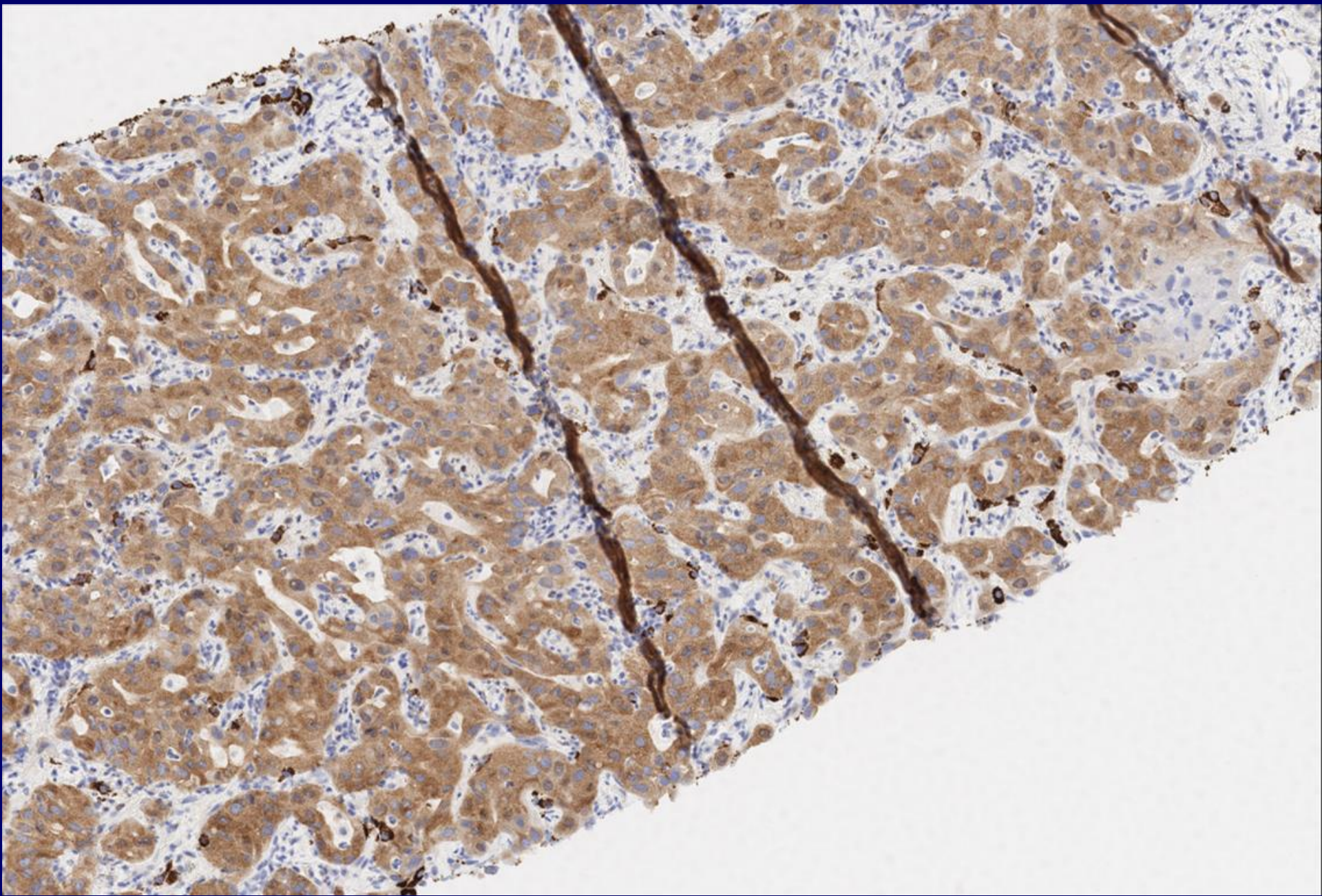

Diagnosis

Intrahepatic CC

- **Gland formation, mucin+, CK19+**

HCC

- **Solid areas, Hep Par 1+ve**
- **Arginase, GPC3, pCEA –ve**
- **Overall features do not support HCC**

BAP1 (BRCA1 associated protein): loss in tumor cells

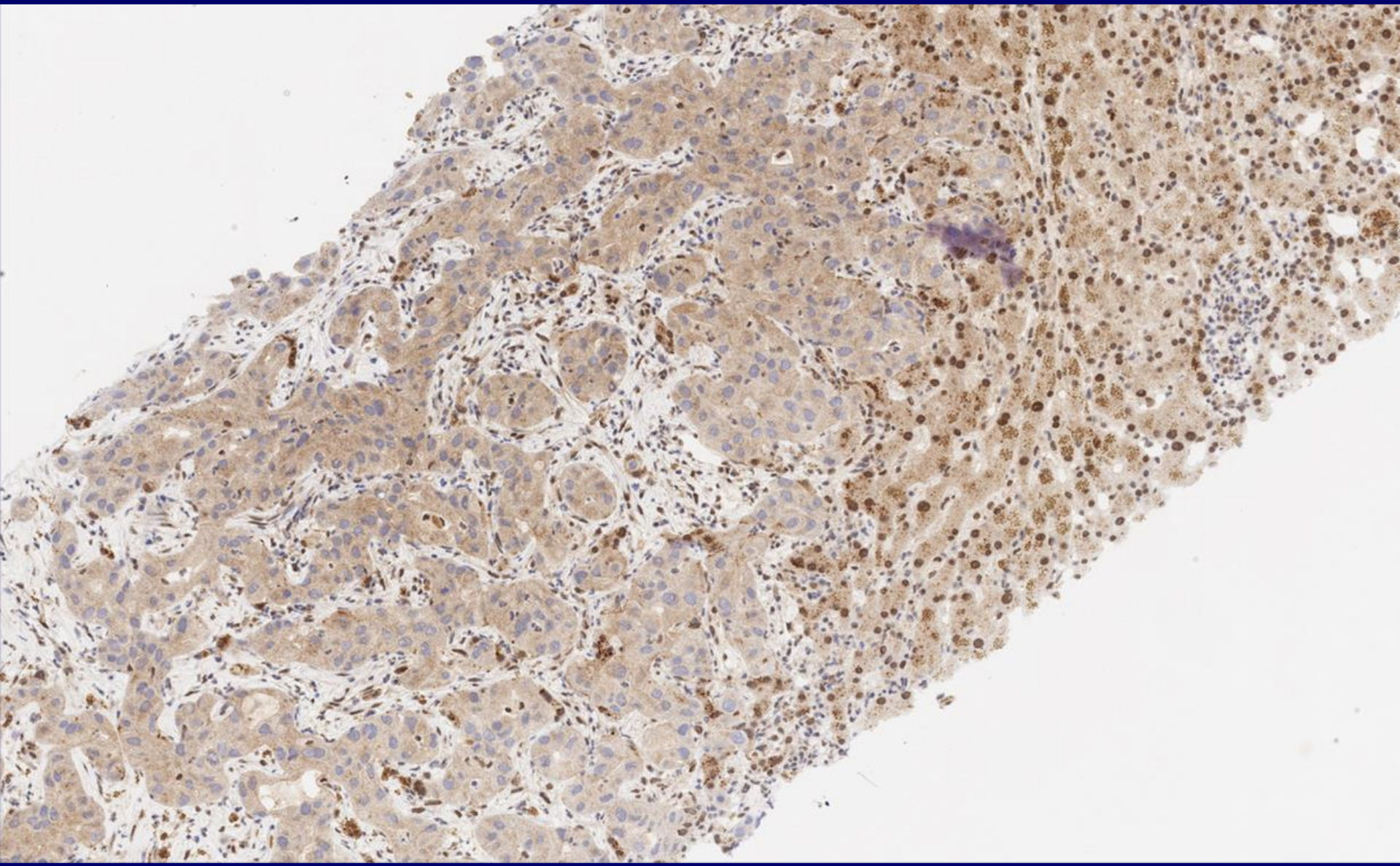

BAP1 loss

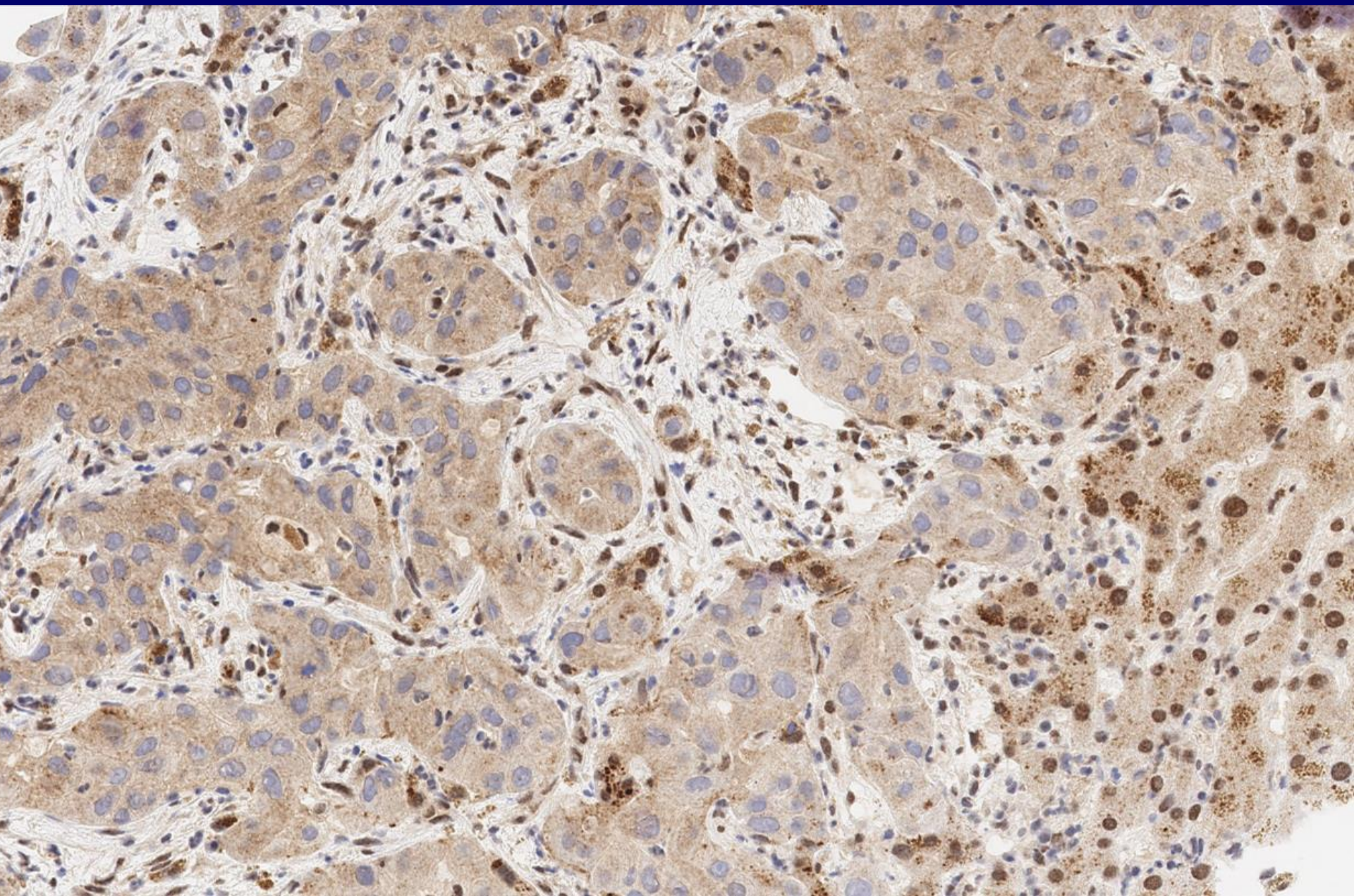

BAP1

- BRCA1-associated protein: tumor suppressor gene
- Loss of BAP1 or *BAP1* mutation (limited data):

Intrahepatic CC	26%
HCC	<5%
Biliary AC	10%
Pancreas	0
GastroEso	<5

Jhunjhunwala, Genome Biol 2014

Andrici, Medicine (Baltimore) 2016

Genetic changes: liver tumors

Hepatocellular carcinoma	Intrahepatic cholangiocarcinoma
CTTNB1 (β-catenin) mutation: 20-30% ***TERT* promoter** mutation: (40-60%) Amplification: MET, FGF19	Metabolic genes: ***IDH1***, *IDH2* mutations (25-30%) Chromatin remodeling: ***BAP1***, *ARID1A* Fusion events: ***FGFR2***, *ROS1*

Schulze, Nat Genetics, 2015
Zhou, Nat Commun, 2014
Moeini, Clin Cancer Res 2016

Case 7

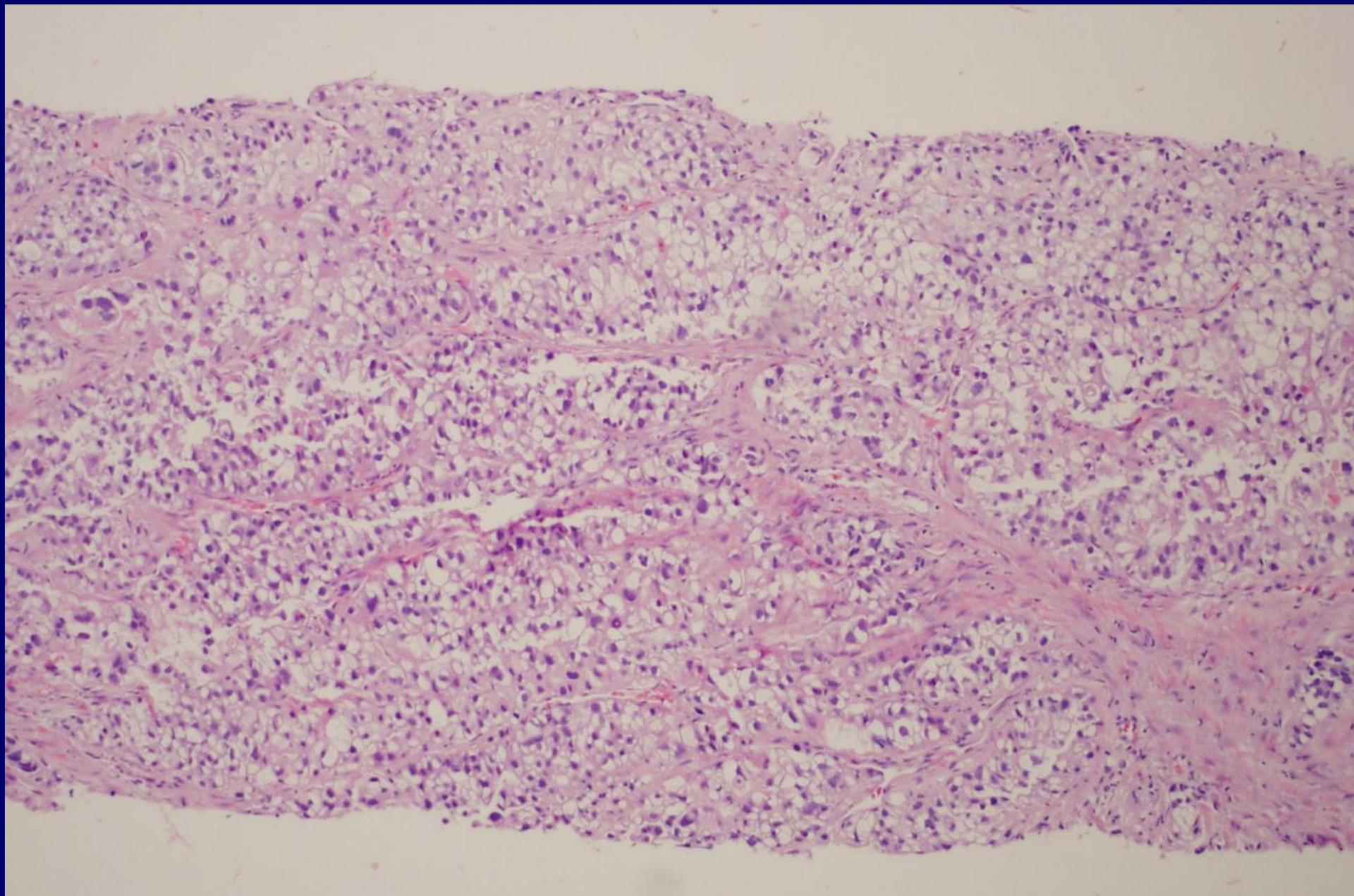

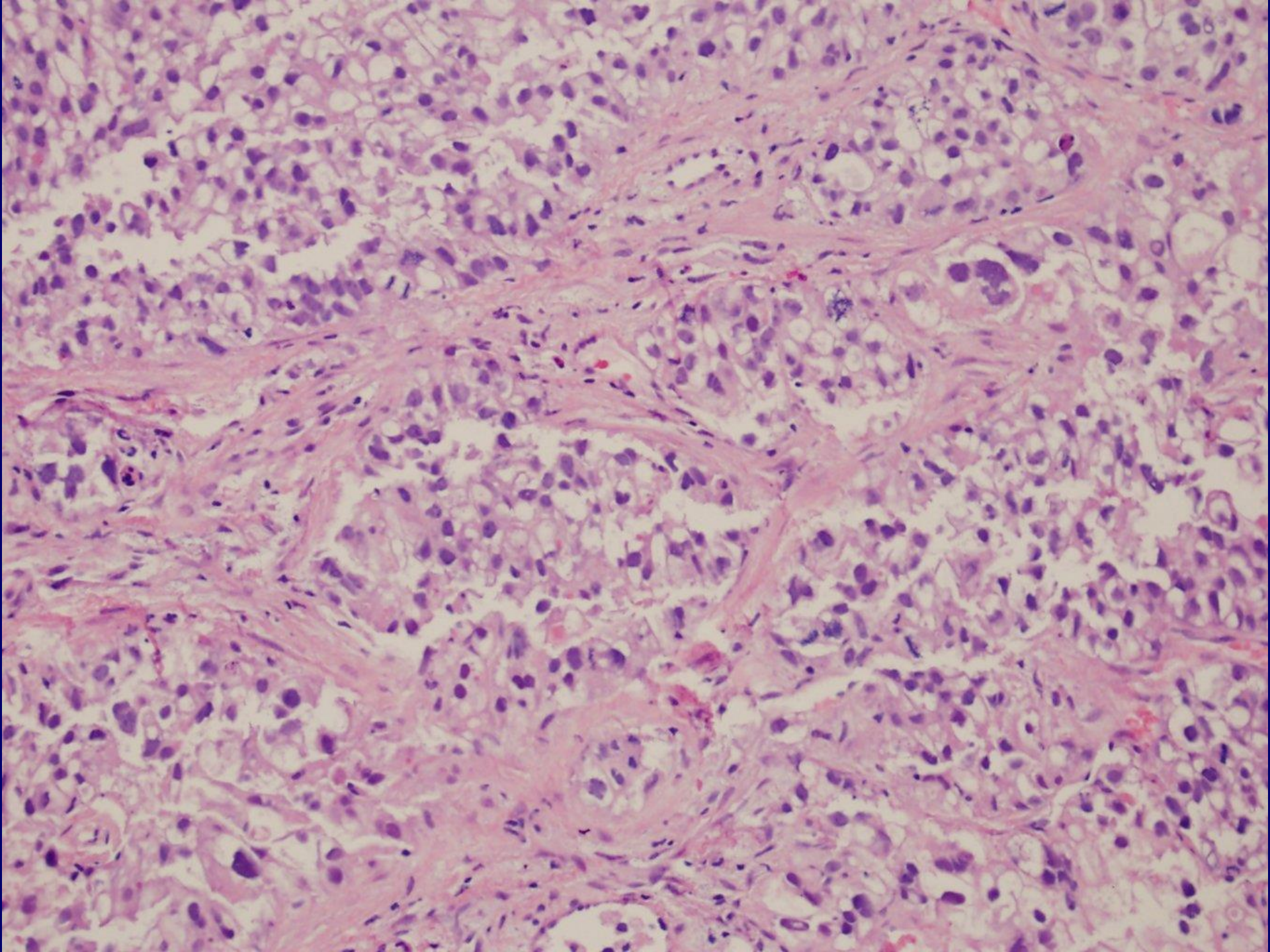

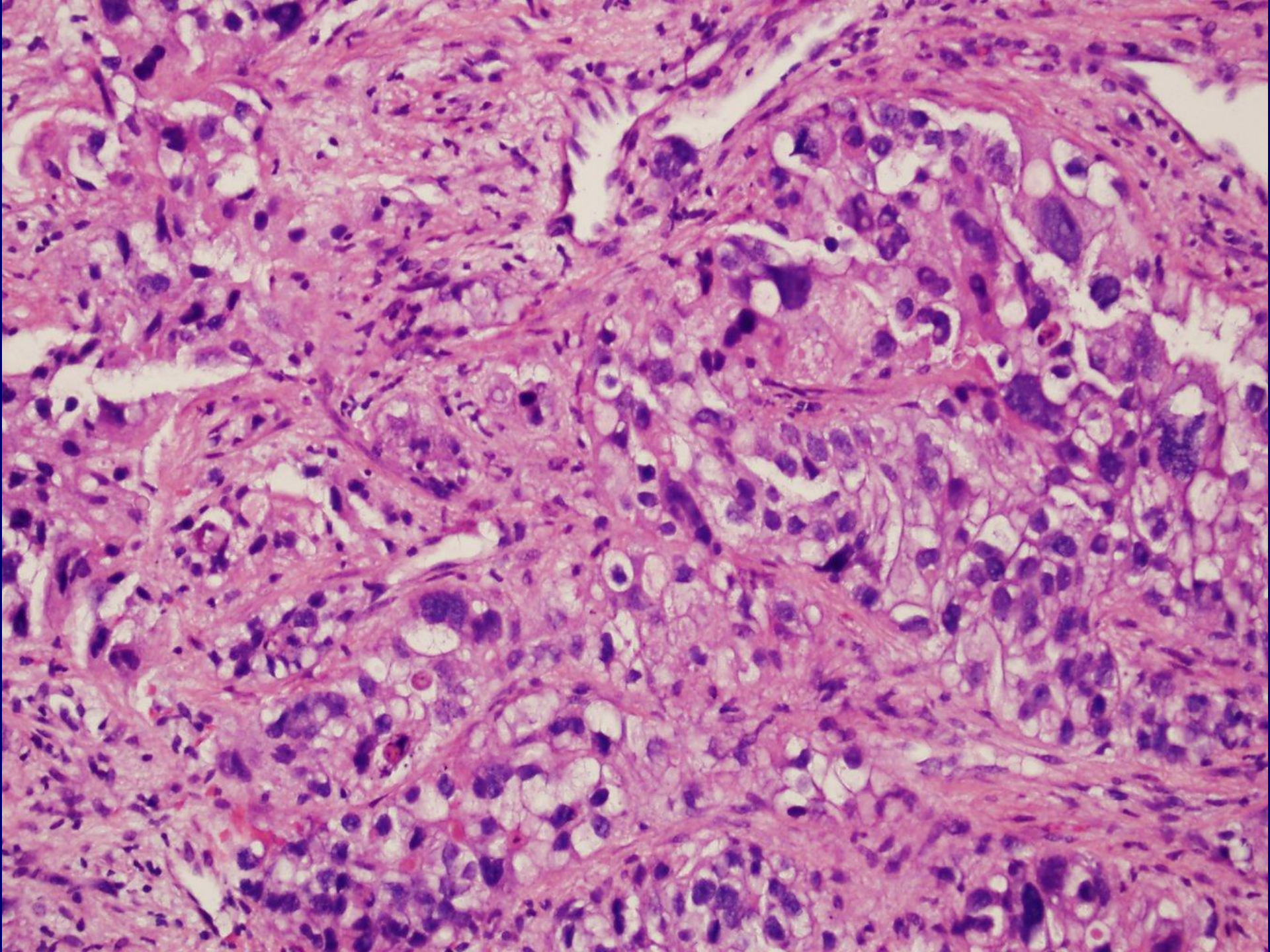

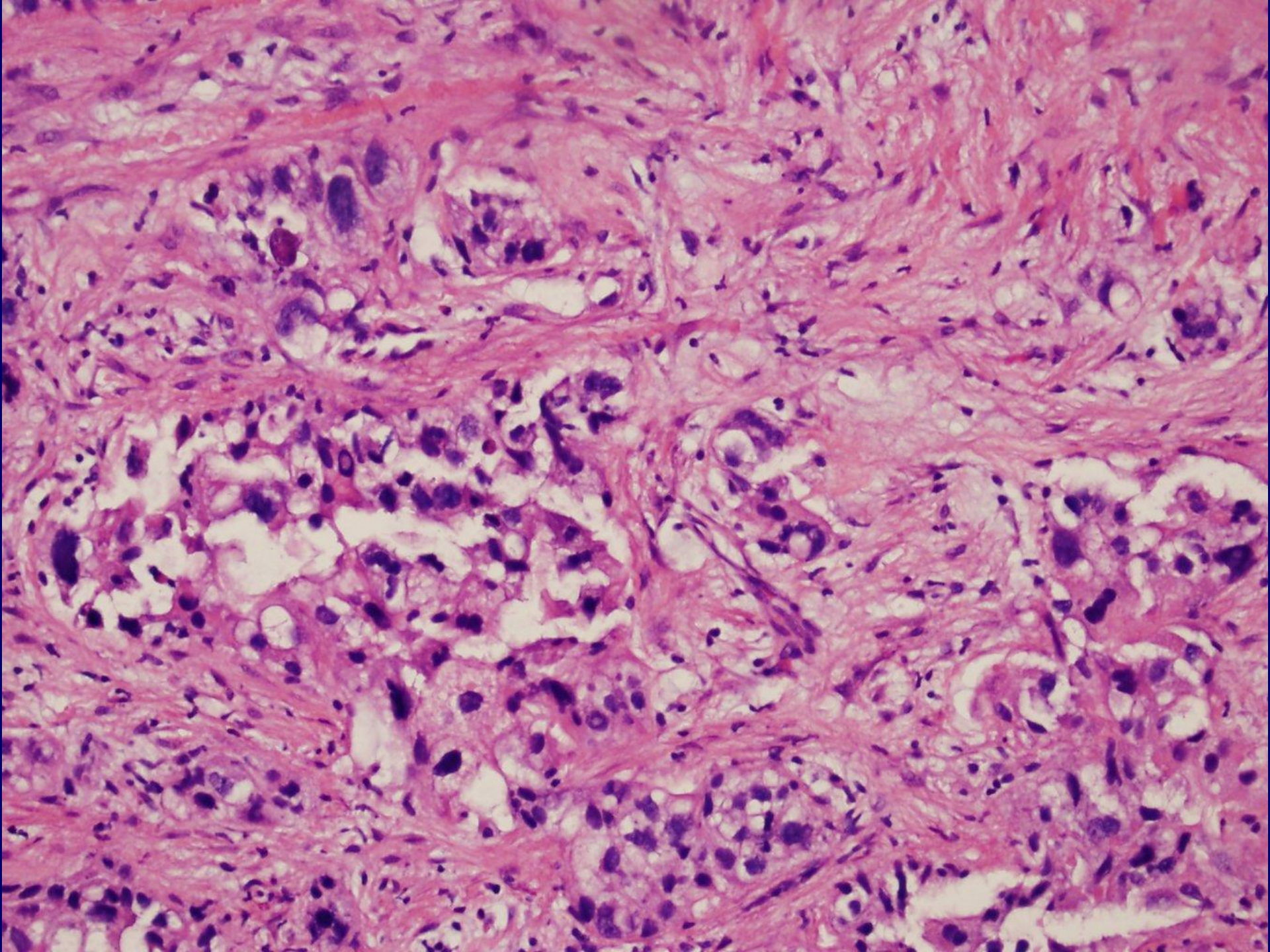

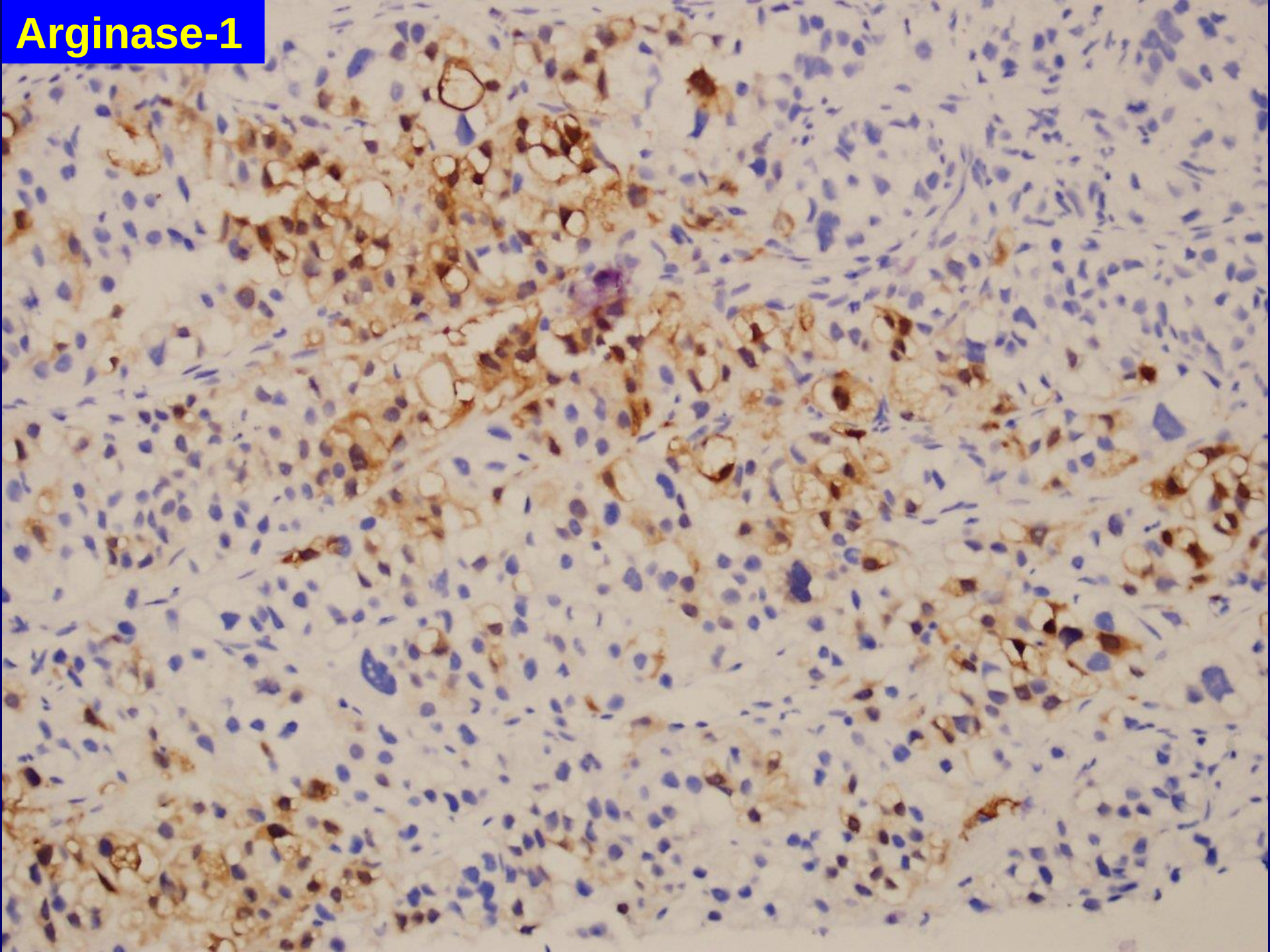
Arginase-1

Glypican-3

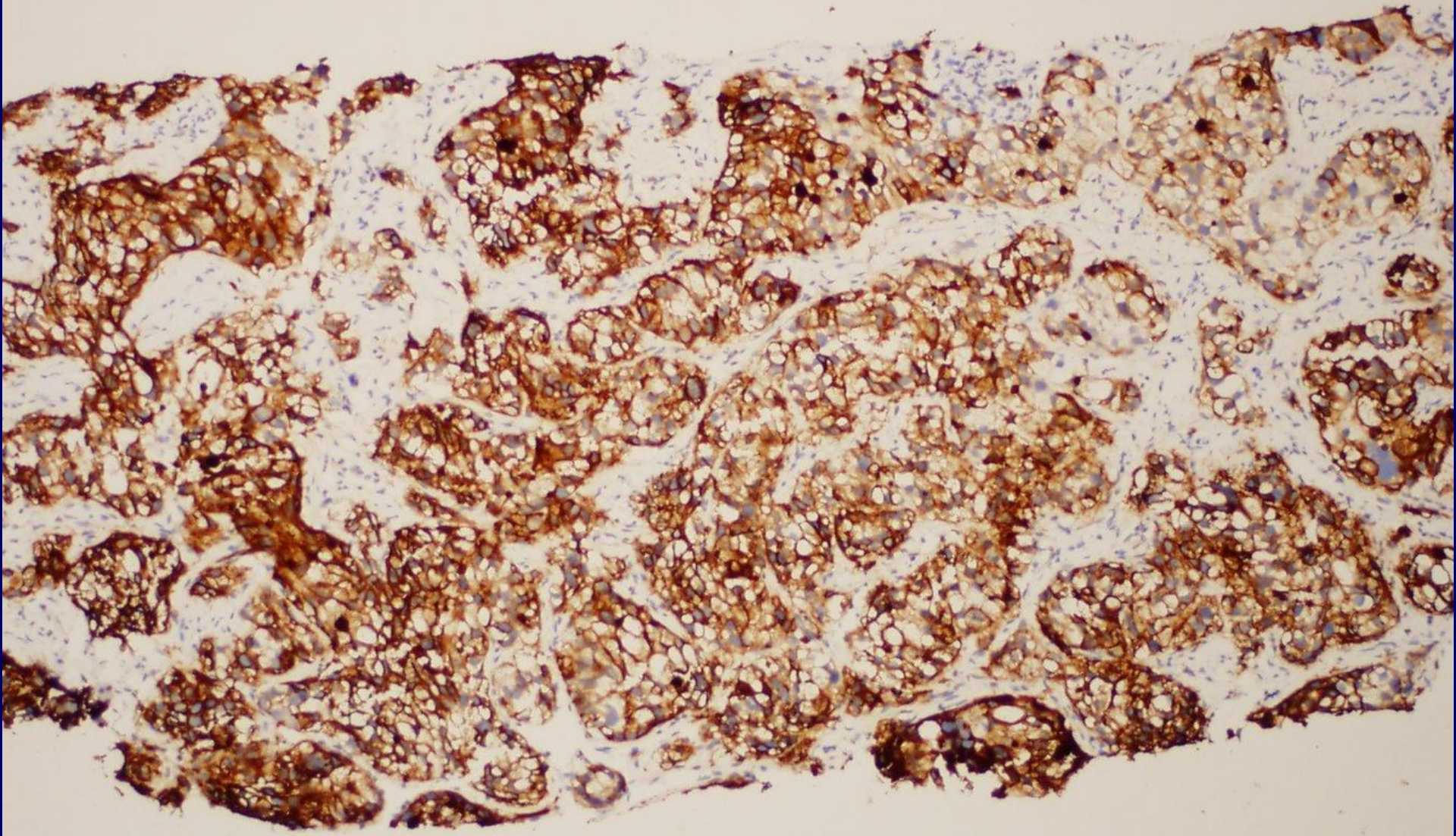

CK19

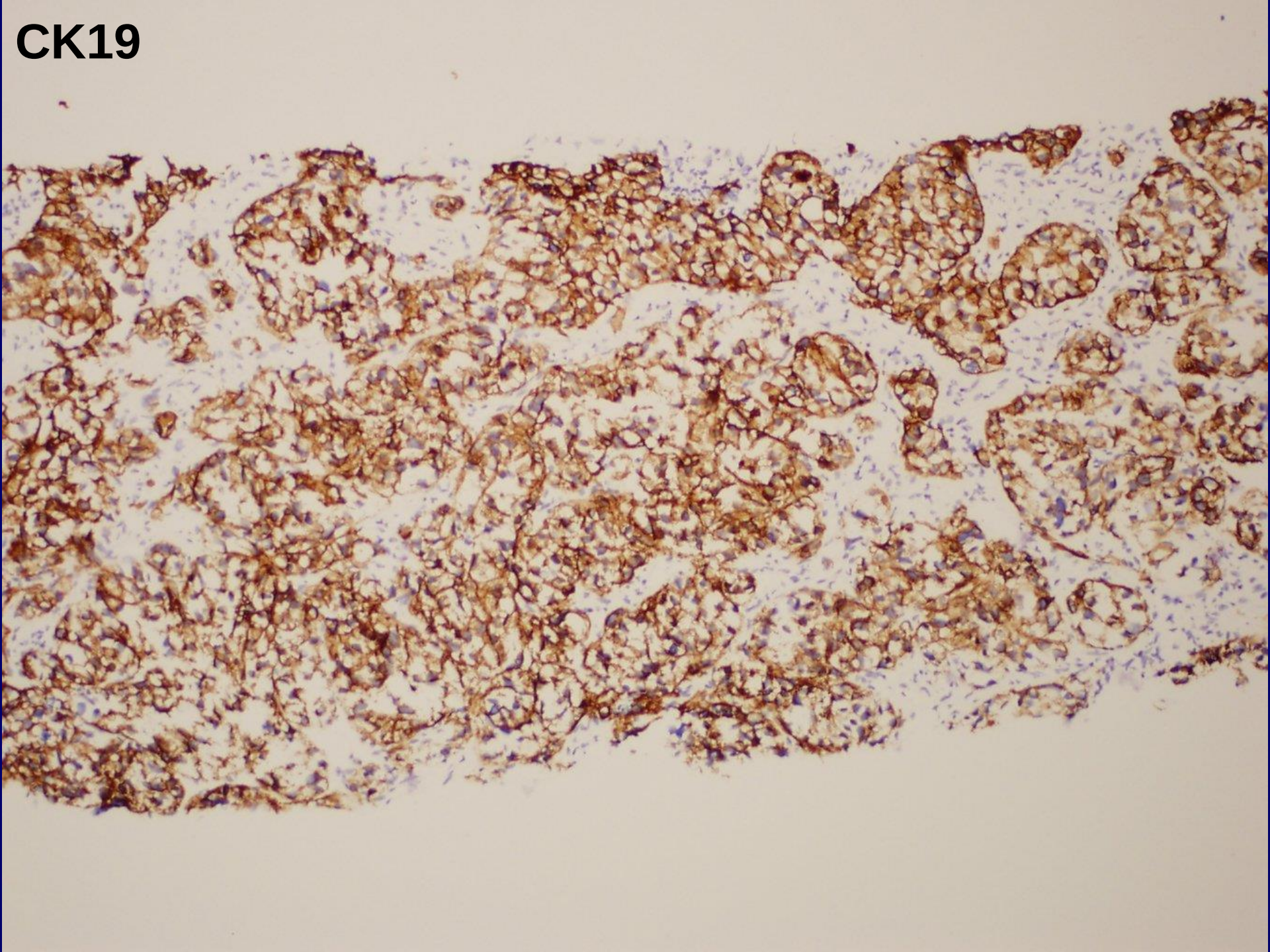

Mucicarmine

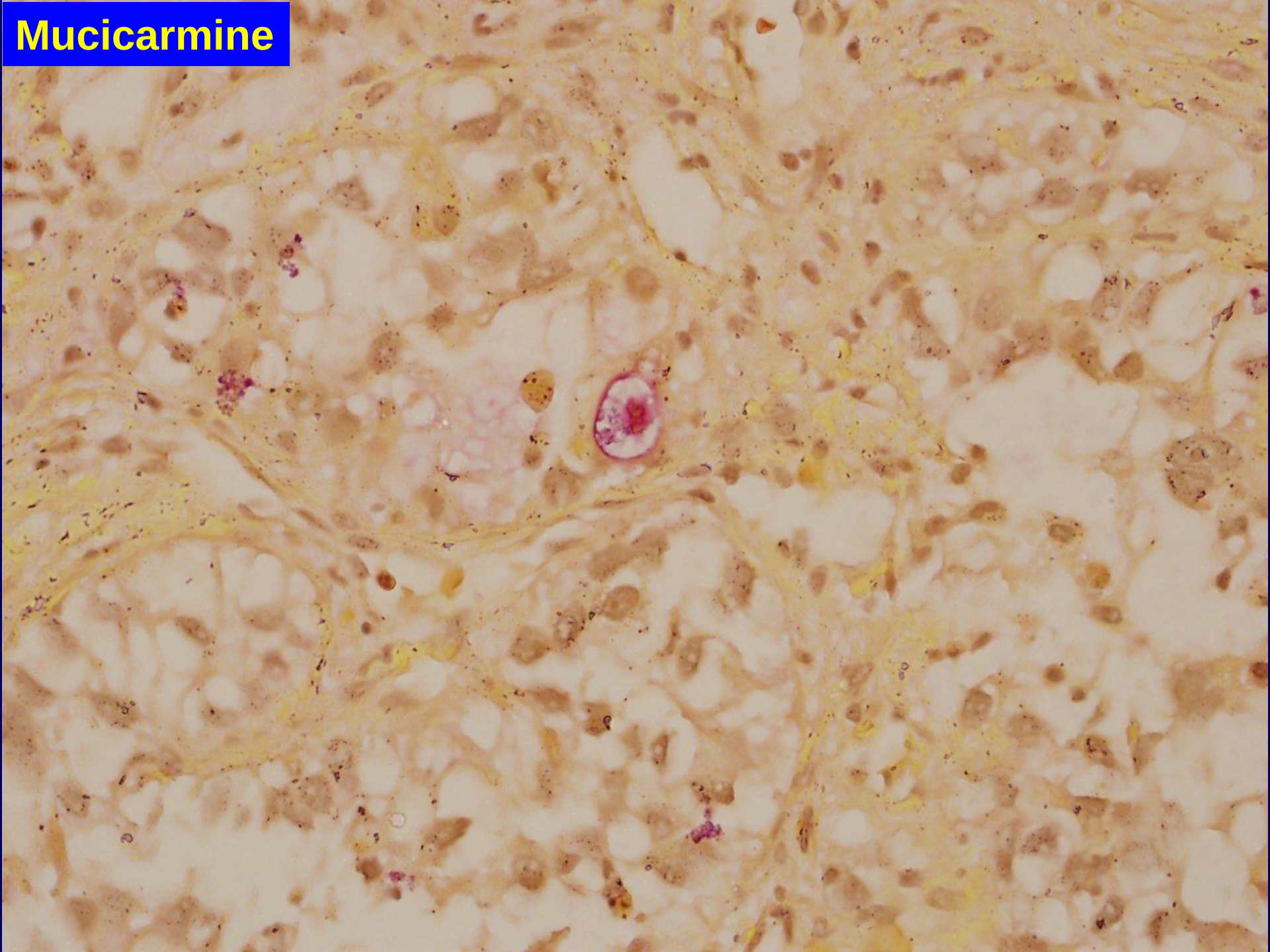

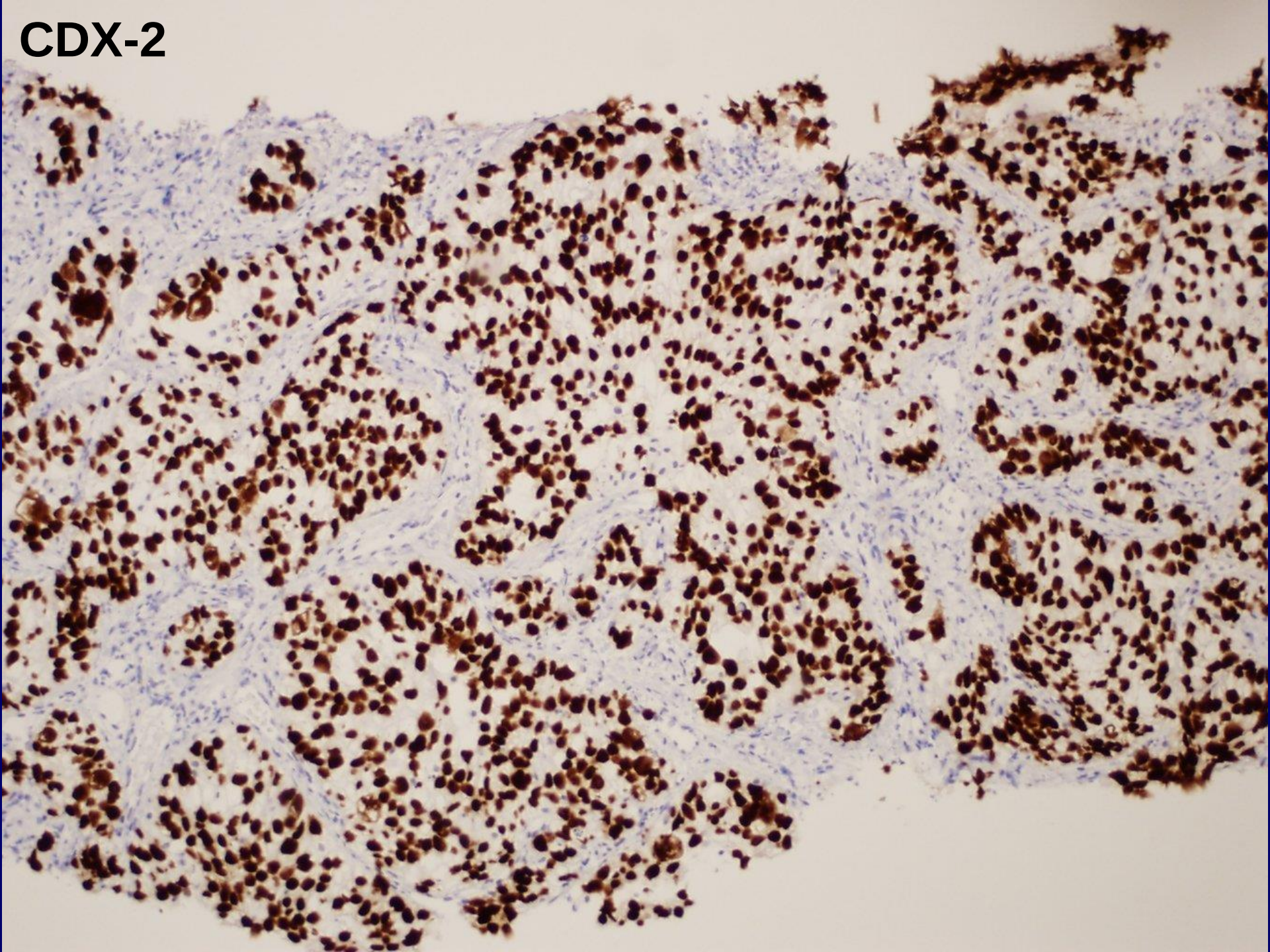
CDX-2

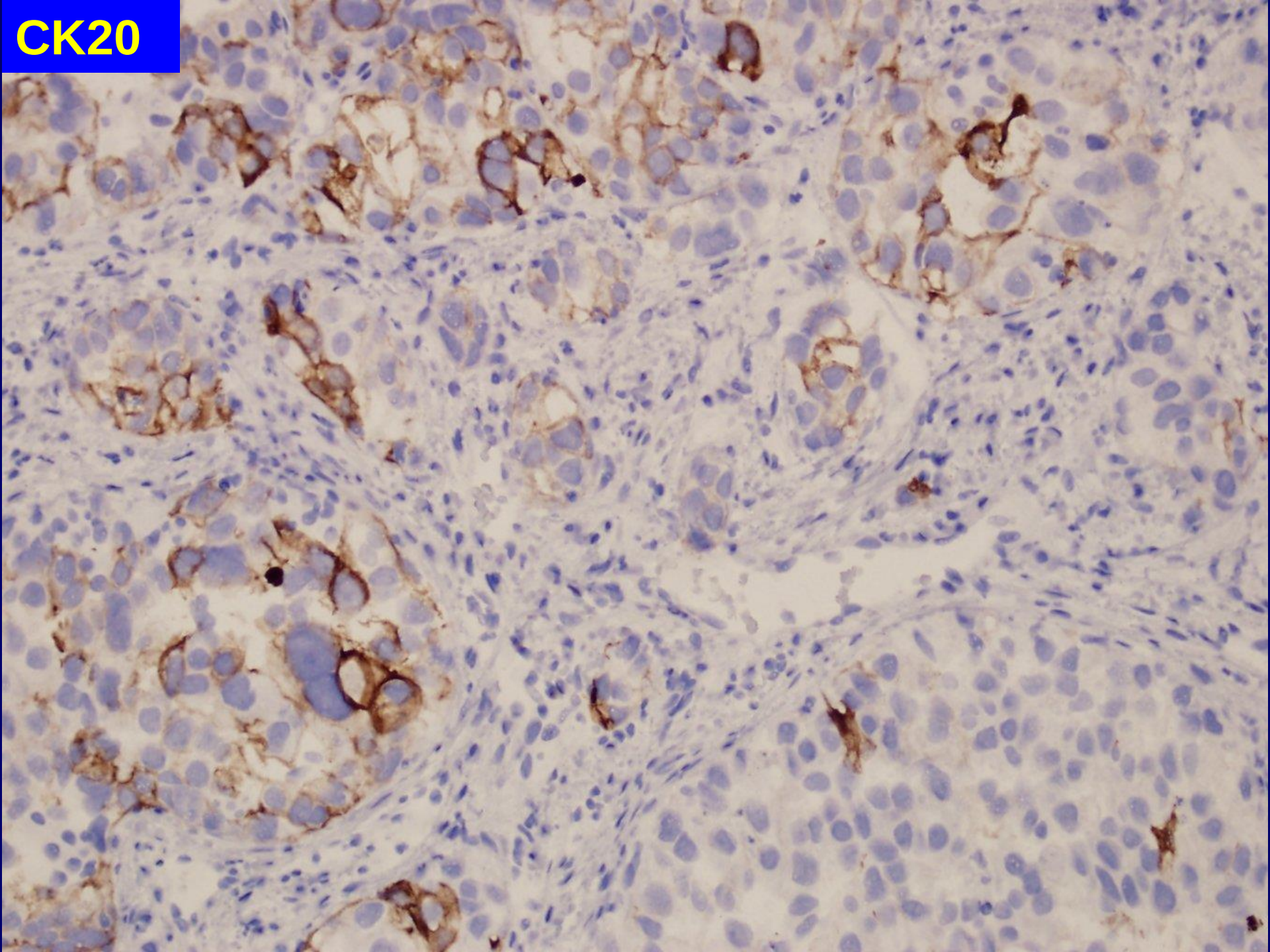
CK20

Hepatoid adenocarcinoma

- Stomach, pancreas, gallbladder
- Lung, intestine, urinary bladder

Components

- HCC component (hepatoid carcinoma)
- Adenocarcinoma component

Hepatoid adenocarcinoma

- Typically no liver mass
- No chronic liver disease
- Morphology, IHC: same as HCC

Primary vs. metastatic

- Clinical presentation
- Immunophenotype

HCC: Histologic variants

WHO 2010	Other variants
• Scirrhous • Fibrolamellar • Sarcomatoid • Lymphocyte-rich	• Steatohepatitic • GCSF-rich • *Cirrhosis-like* • *Clear cell* • *Macrotrabecular-massive*

- Use arginase-1
- Strict criteria for diagnosis of cholangiocarcinoma component

Case 8: 85/M with 5 cm liver mass

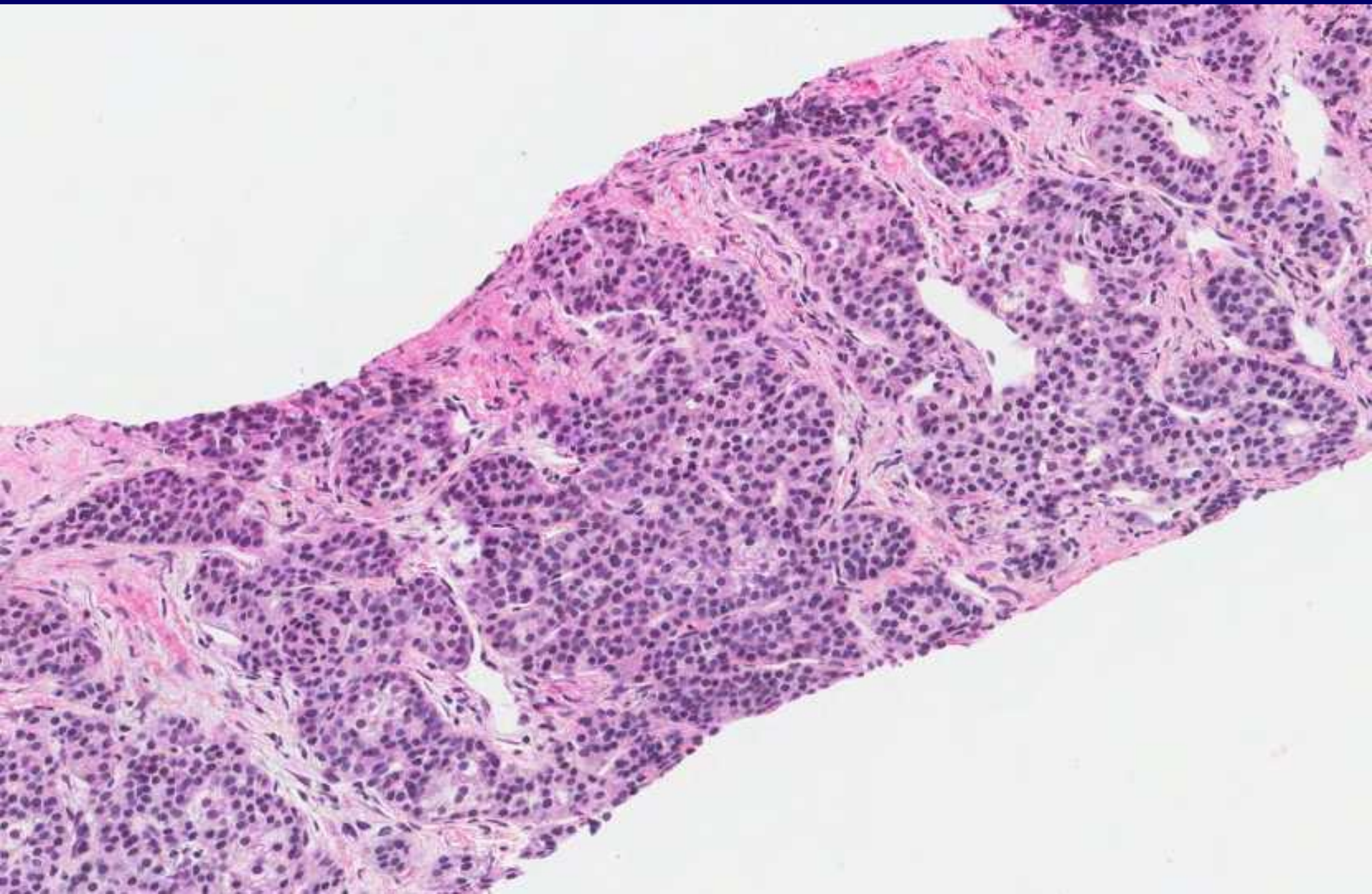

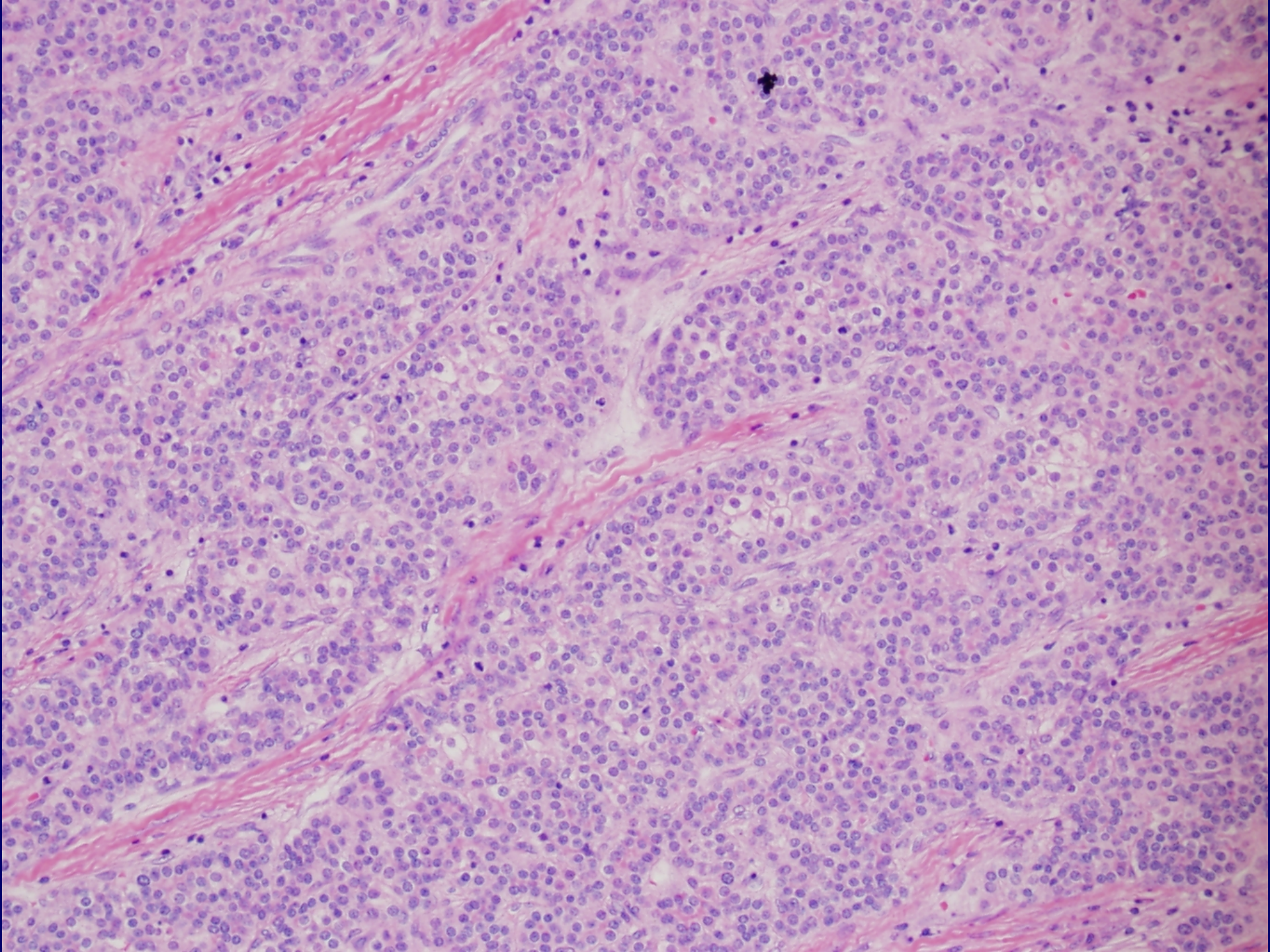

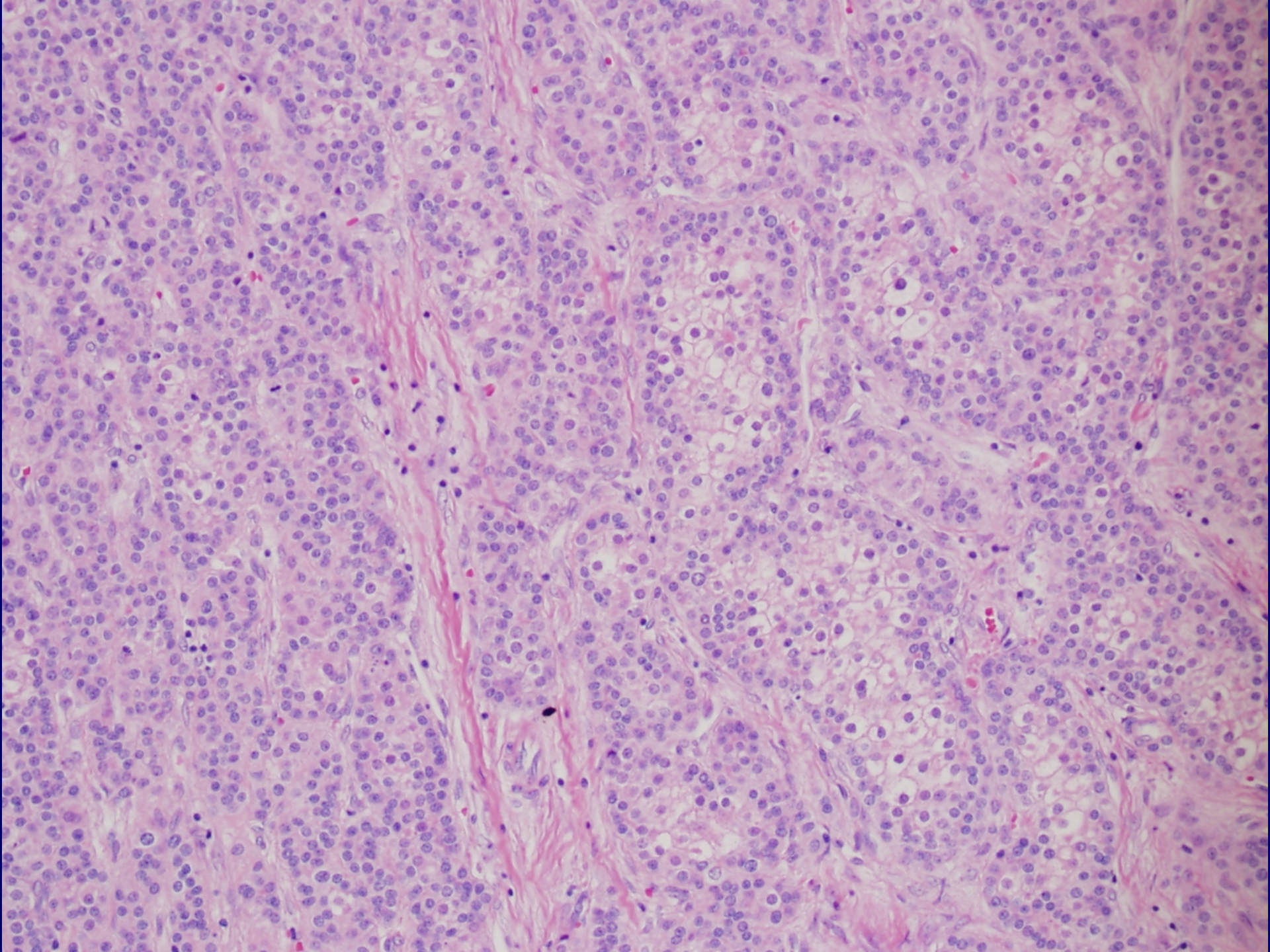

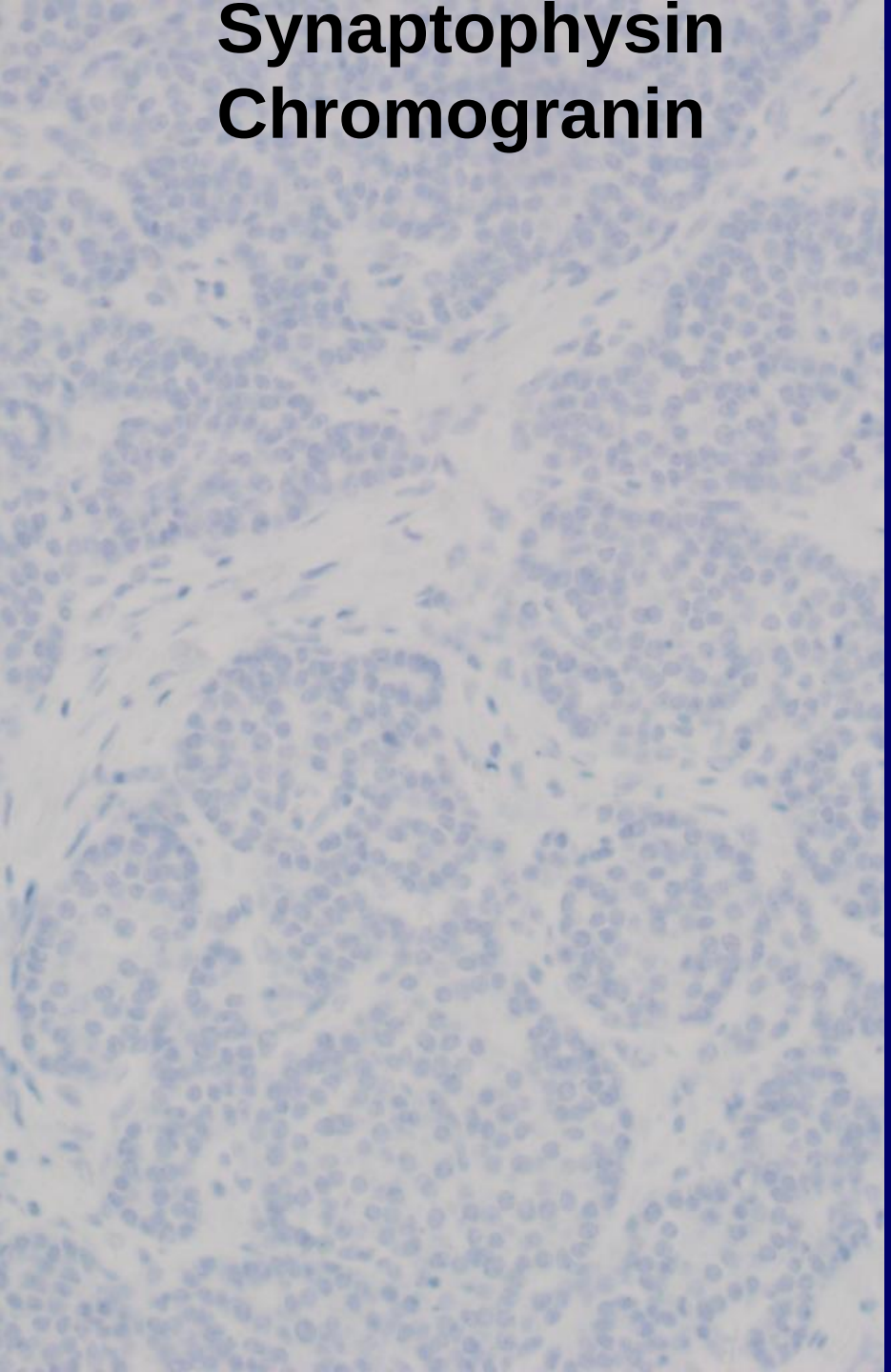
Synaptophysin
Chromogranin

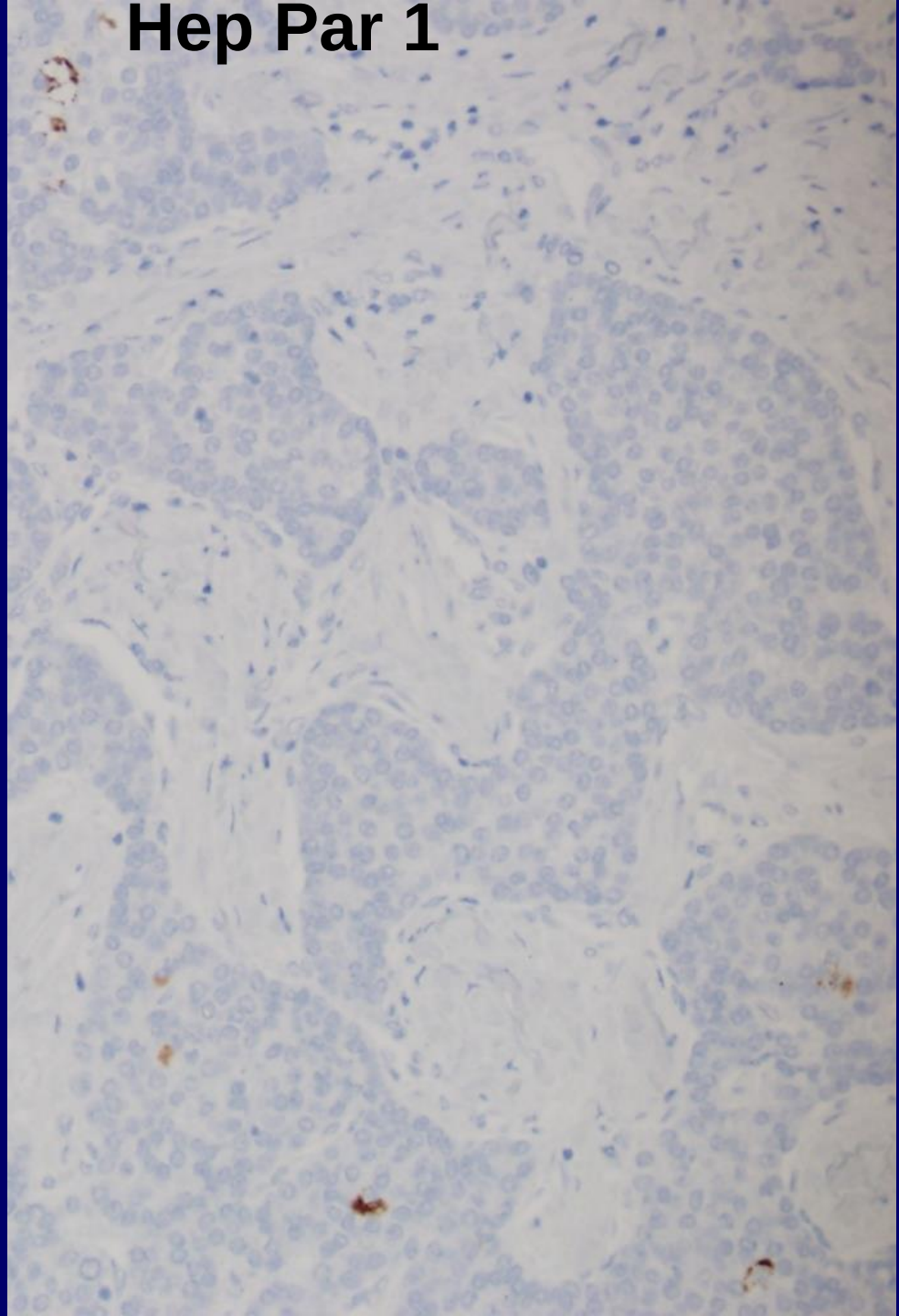
Hep Par 1

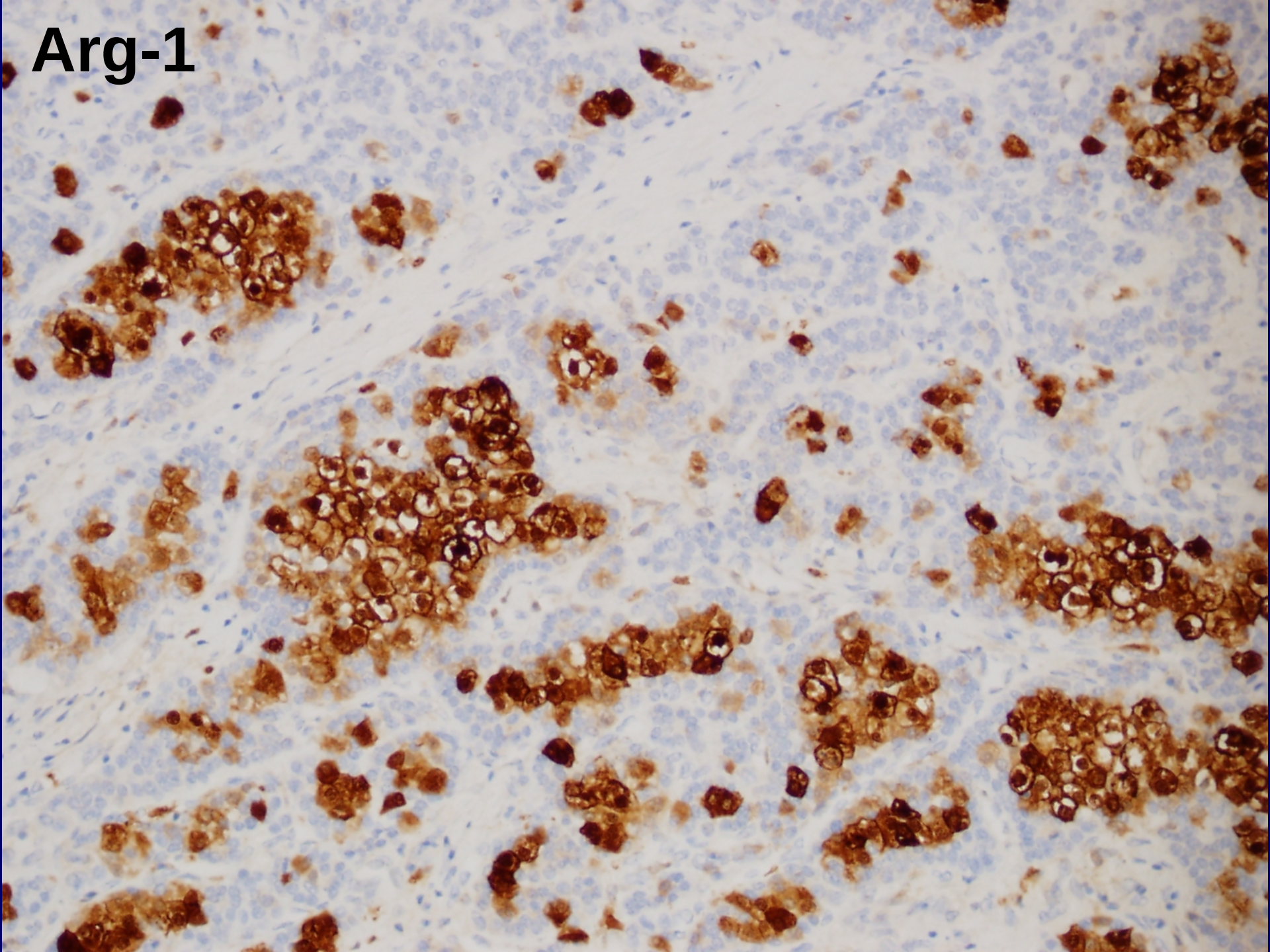
Arg-1

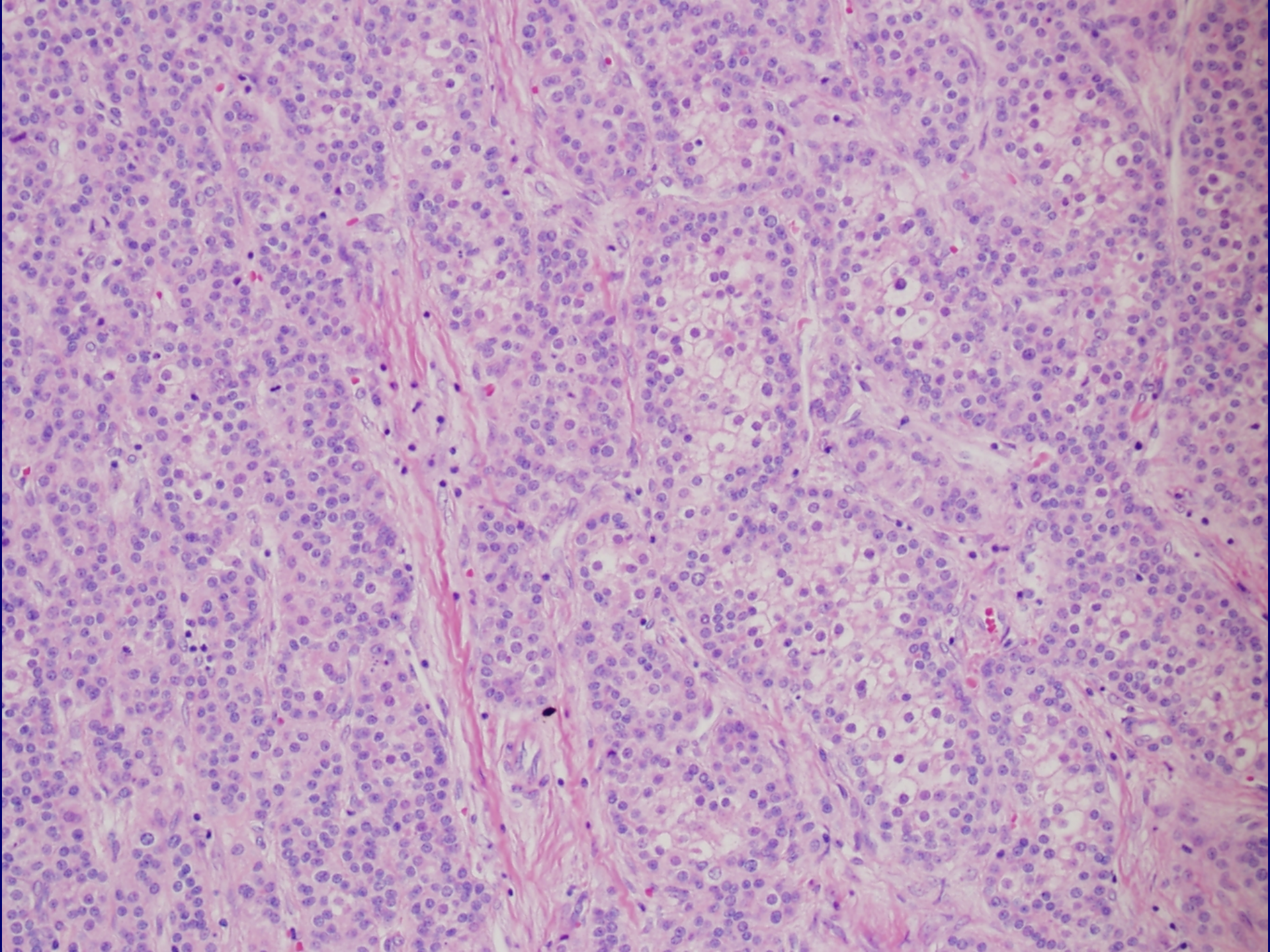

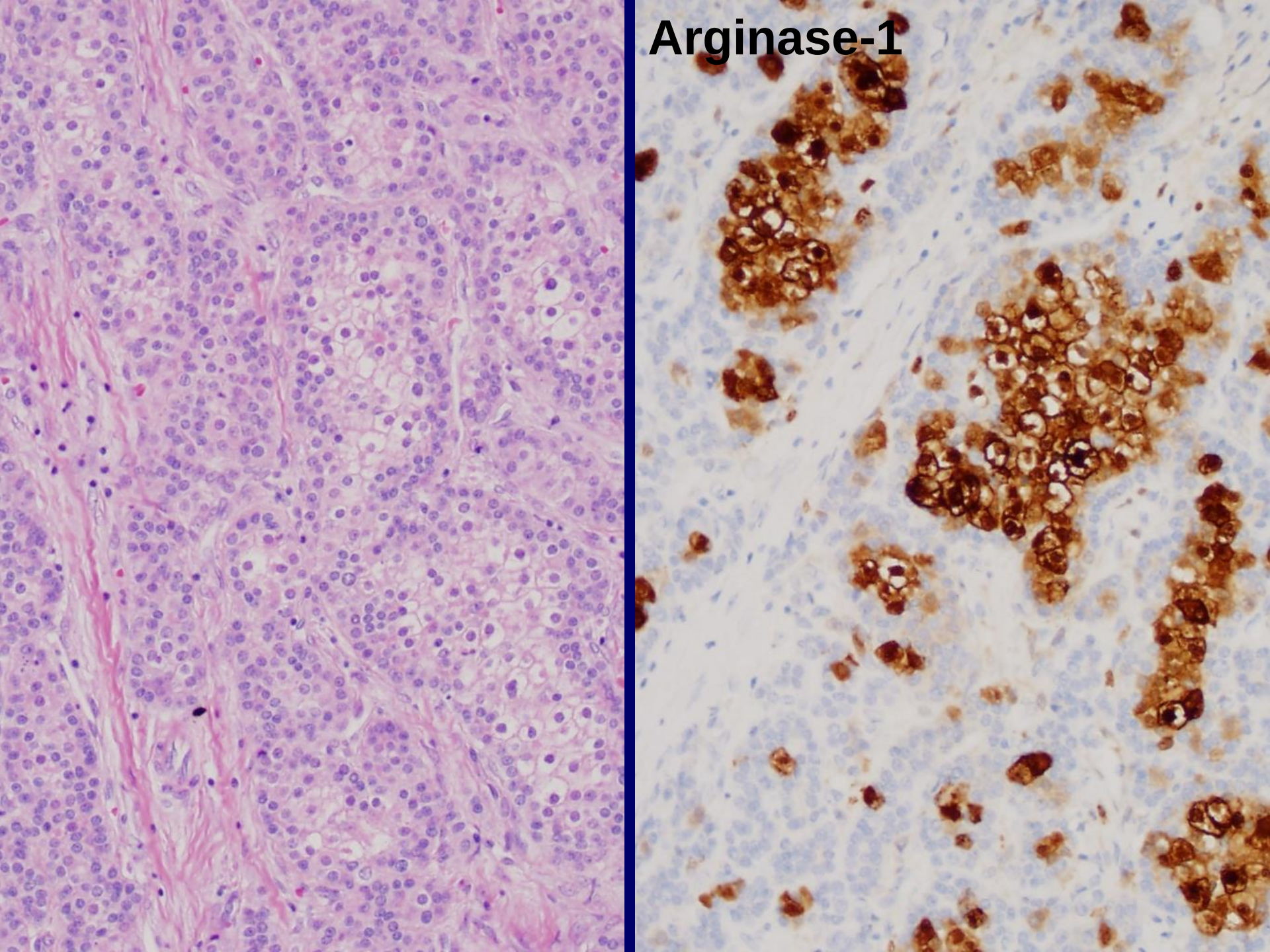
Arginase-1

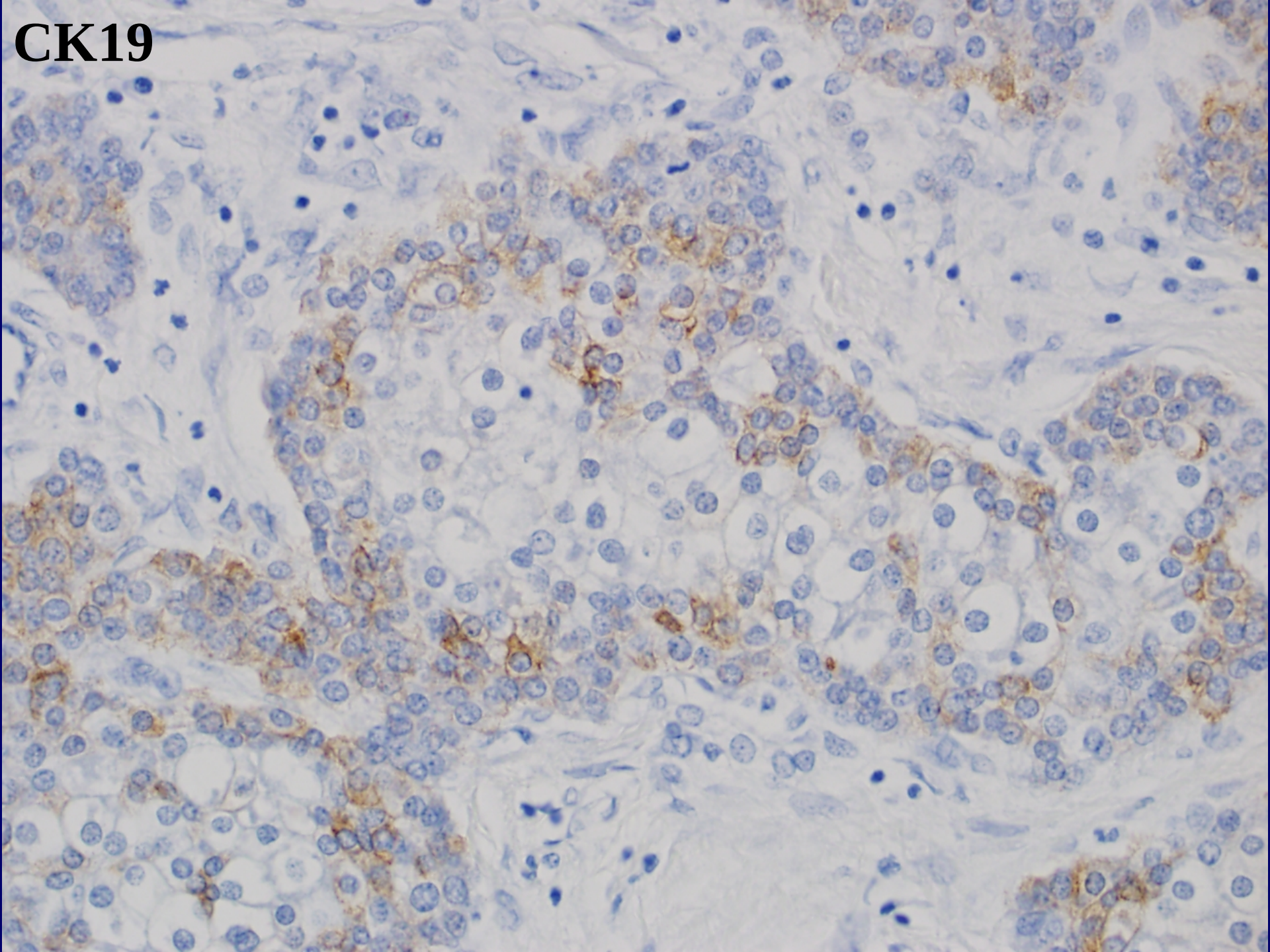
CK19

‘Stem cell’ features

- WHO 2010: Combined HCC-CC with stem cell features
- Update: No longer a recognized subtype
- HCC with ‘stem cell’ features
- Significance of ‘stem cell features’ unclear

HCC: Histologic variants

WHO 2010	Other variants
• Scirrhous • Fibrolamellar • Sarcomatoid • Lymphocyte-rich	• Steatohepatitic • GCSF-rich • *Cirrhosis-like* • *Clear cell* • *Macrotrabecular-massive*

- Use arginase-1
- Strict criteria for diagnosis of cholangiocarcinoma component

Cirrhosis-like

- Multiple tumor nodules that mimic cirrhotic nodules on imaging
- Not a true histologic variant

HCC: cirrhosis-like appearance

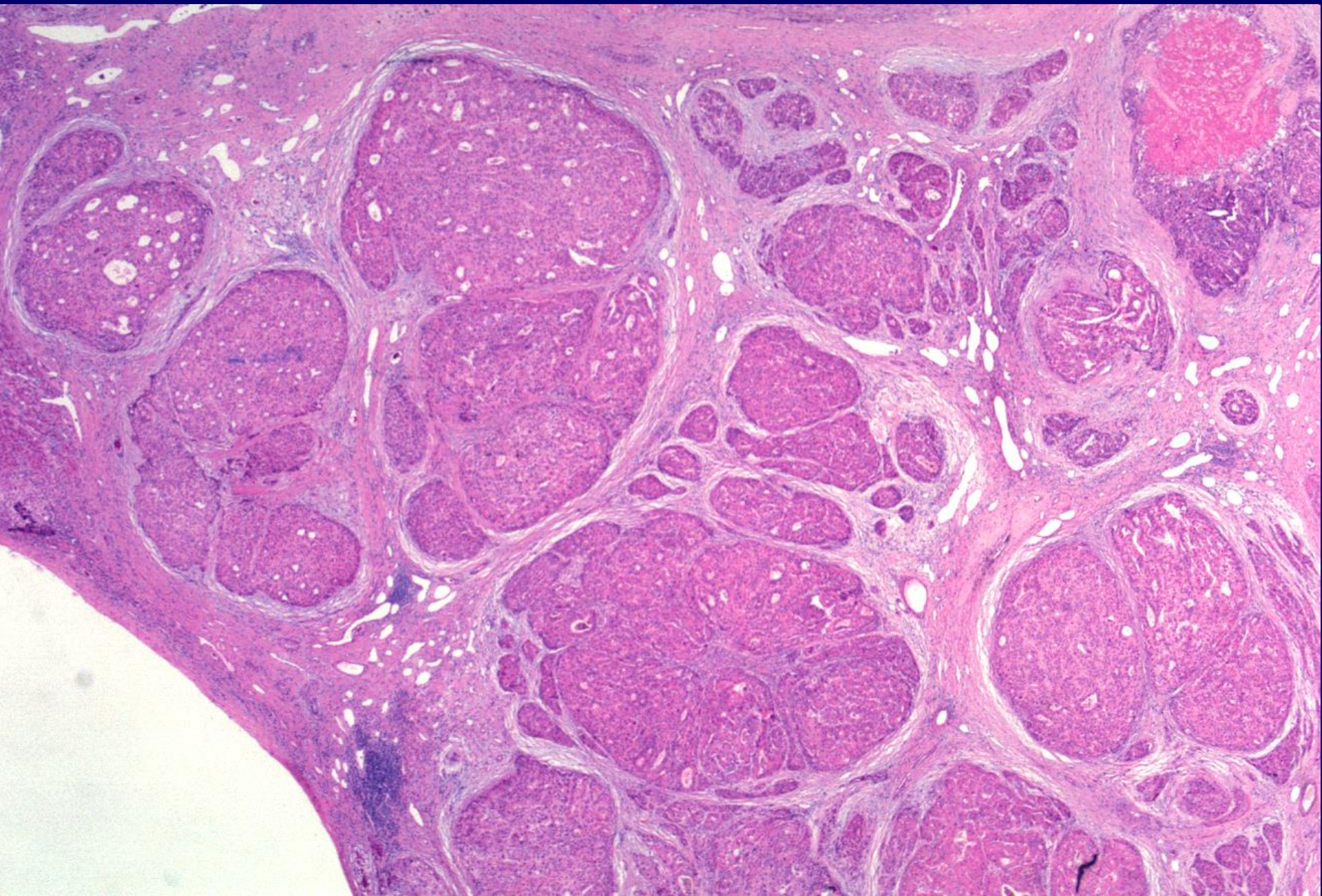

HCC or renal cell carcinoma

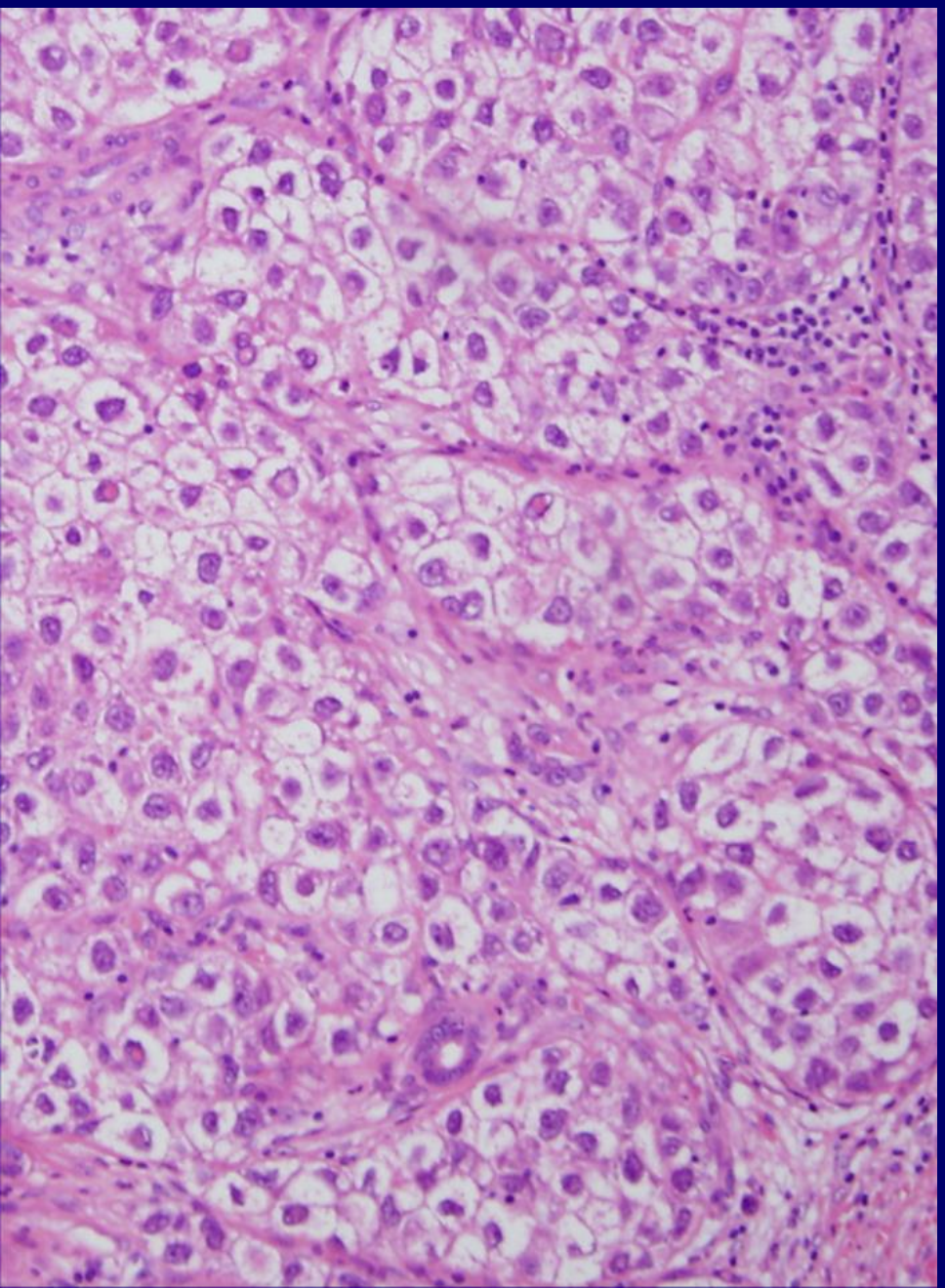

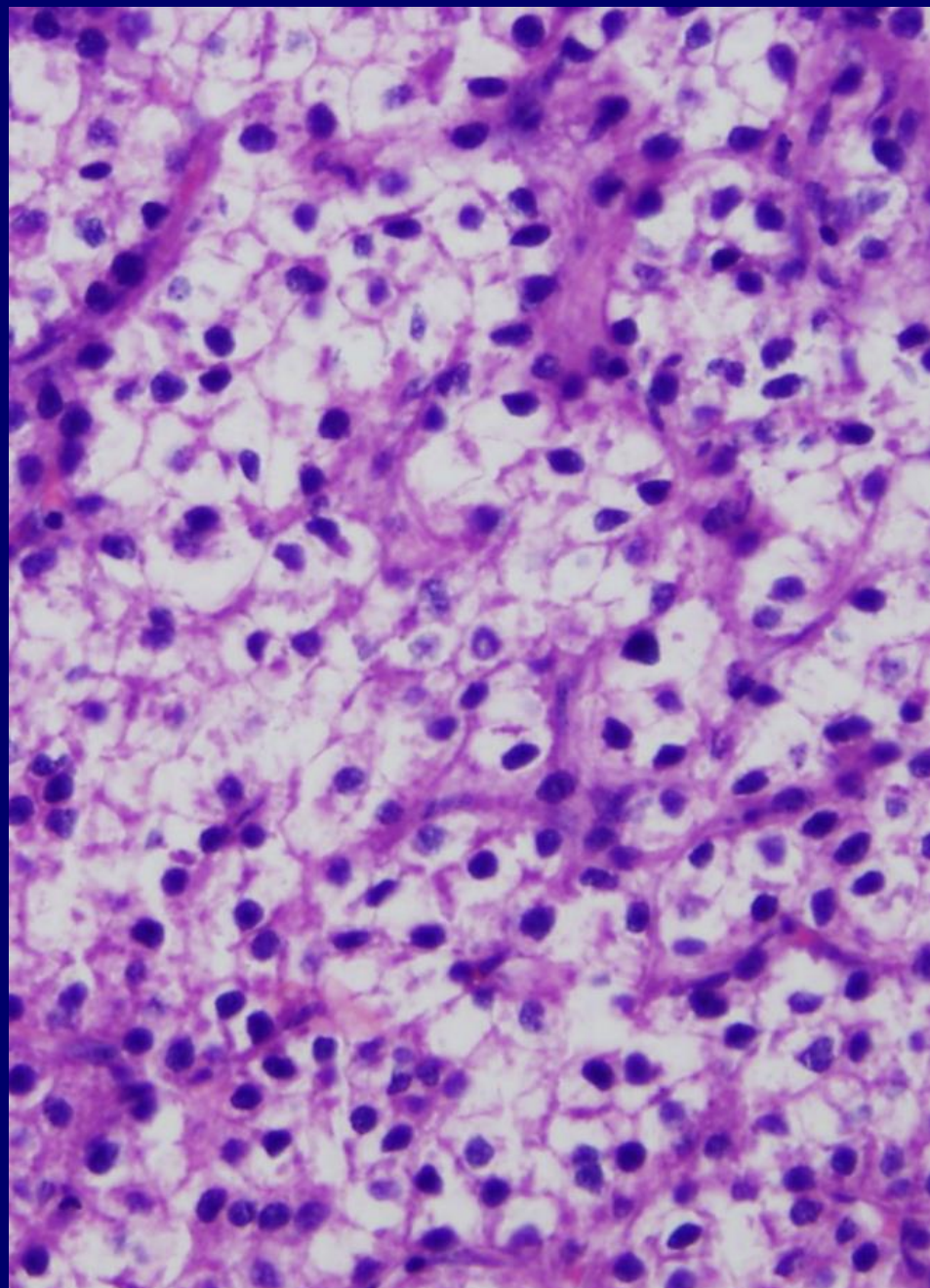

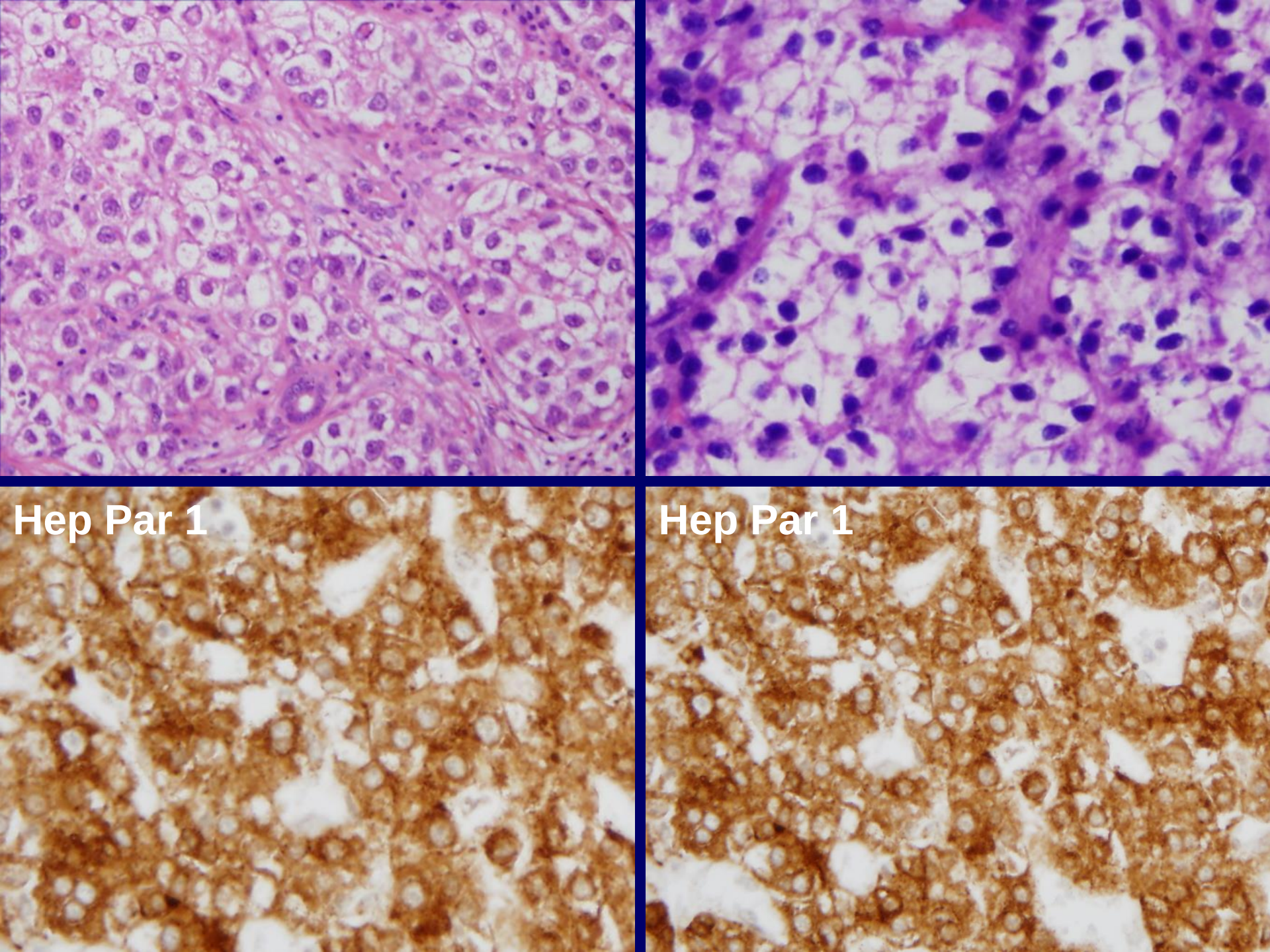
Hep Par 1
Hep Par 1

Two-stain approach for clear cell tumors

Arg-1 and PAX-2/PAX-8

Marker	HCC	Clear cell RCC
Arg-1 GPC-3 Hep Par 1	Positive	Negative
PAX-2 or PAX-8	Negative	Positive
RCC marker, EMA, vimentin	Negative	Positive
CD10	Canalicular	Membranous

PAX-2 nuclear: metastatic RCC

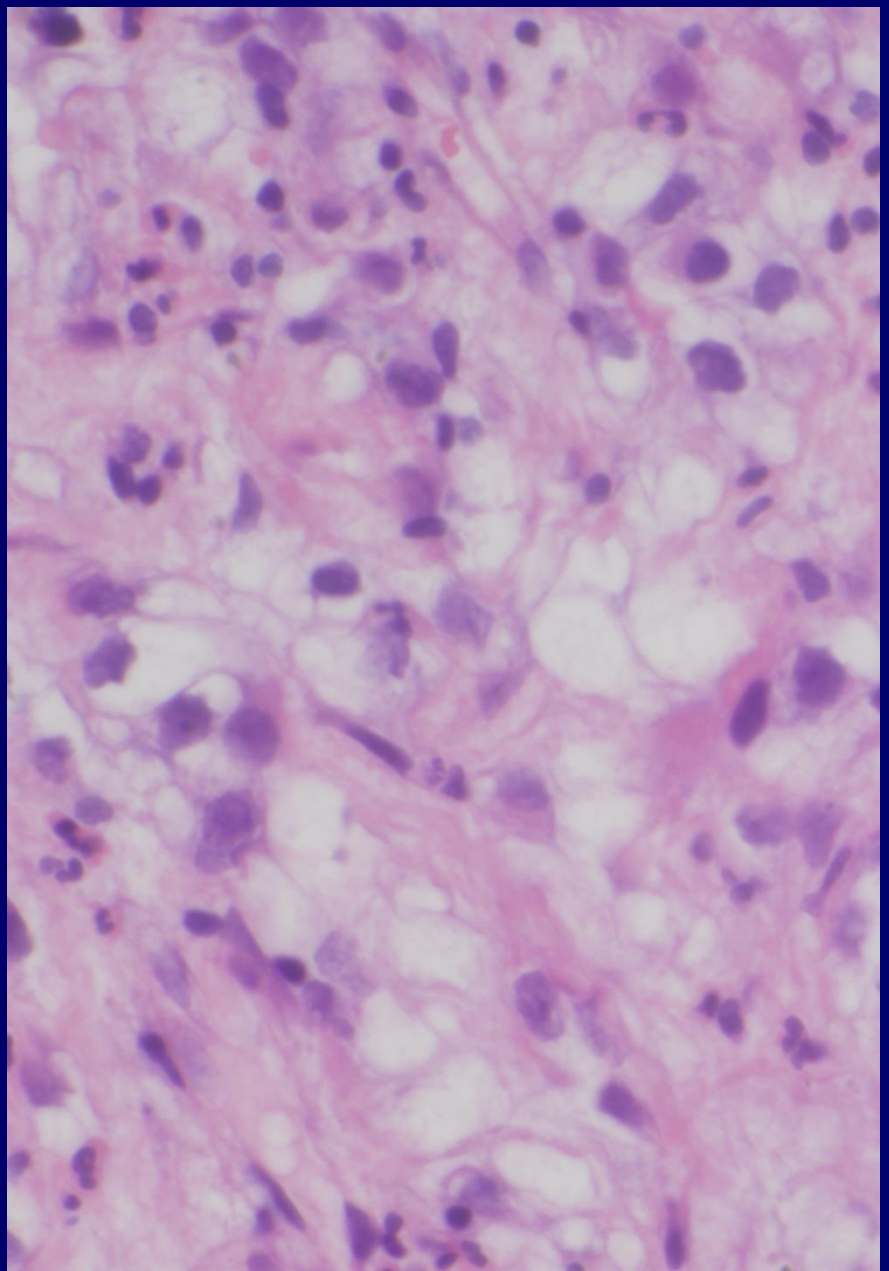

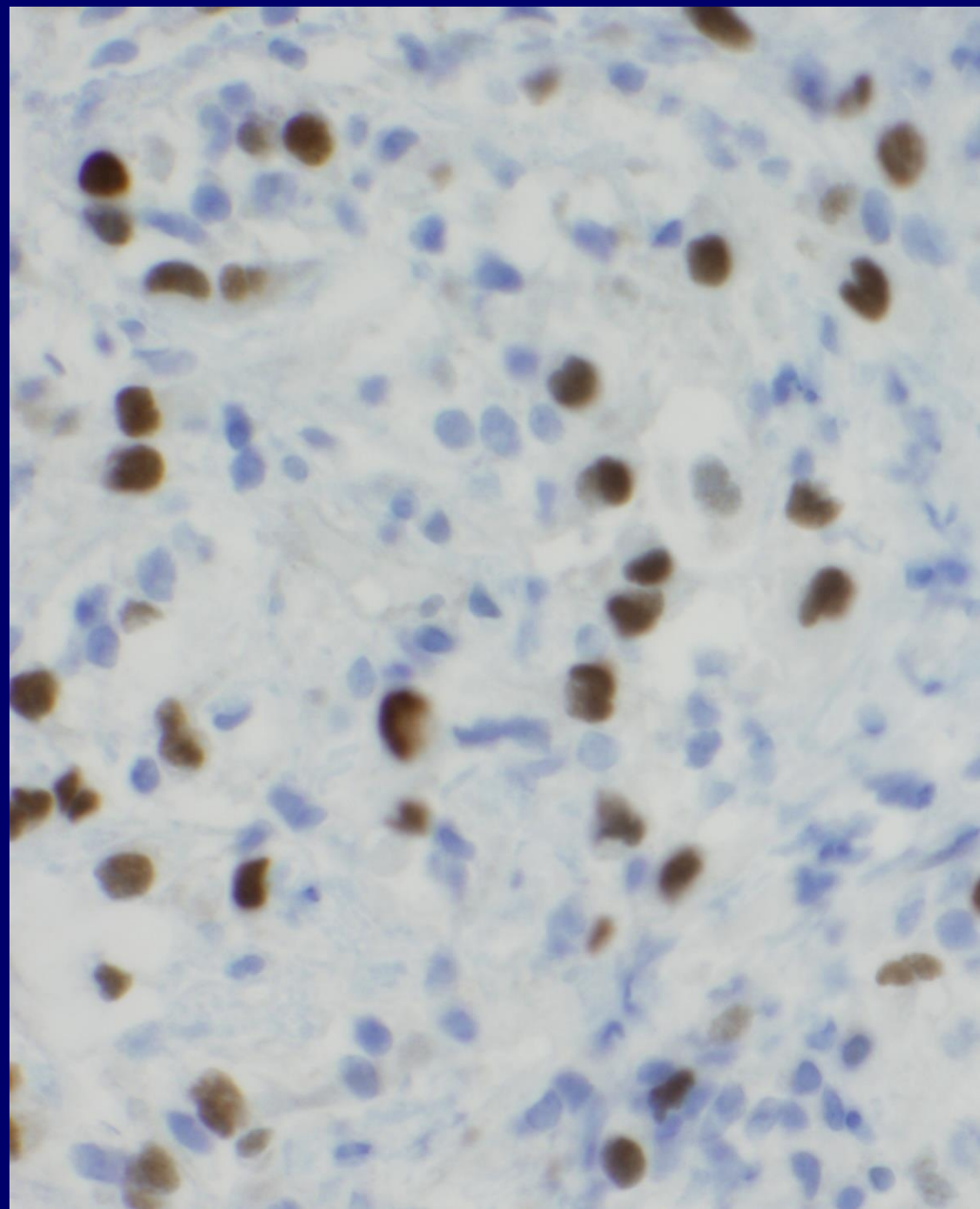

HCC: Histologic variants

WHO 2010	Other variants
• Scirrhous • Fibrolamellar • Sarcomatoid • Lymphocyte-rich	• Steatohepatitic • GCSF-rich • *Cirrhosis-like* • *Clear cell* • *Macrotrabecular-massive*

- Use arginase-1
- Strict criteria for diagnosis of cholangiocarcinoma component

HCC to CC spectrum: a new classification?

HCC	CK19-
HCC	CK19+
Scirrhous HCC	CK19±
HCC-stem cells	CK19+
HCC-CC stem cell features	CK19+
HCC-CC, classical	CK19+
CC	CK19+

vWD-HCC: stromal invasion

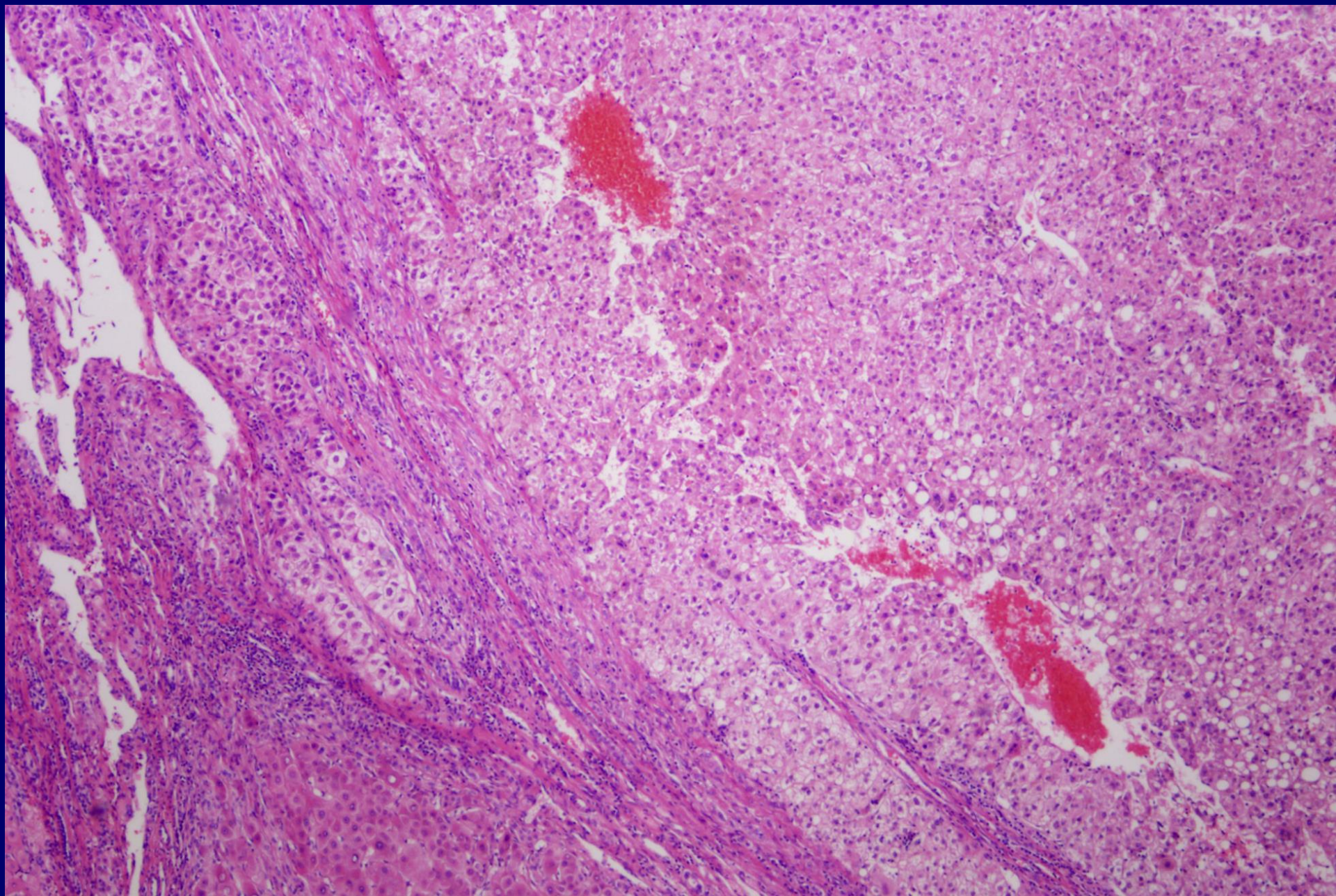

Stromal invasion

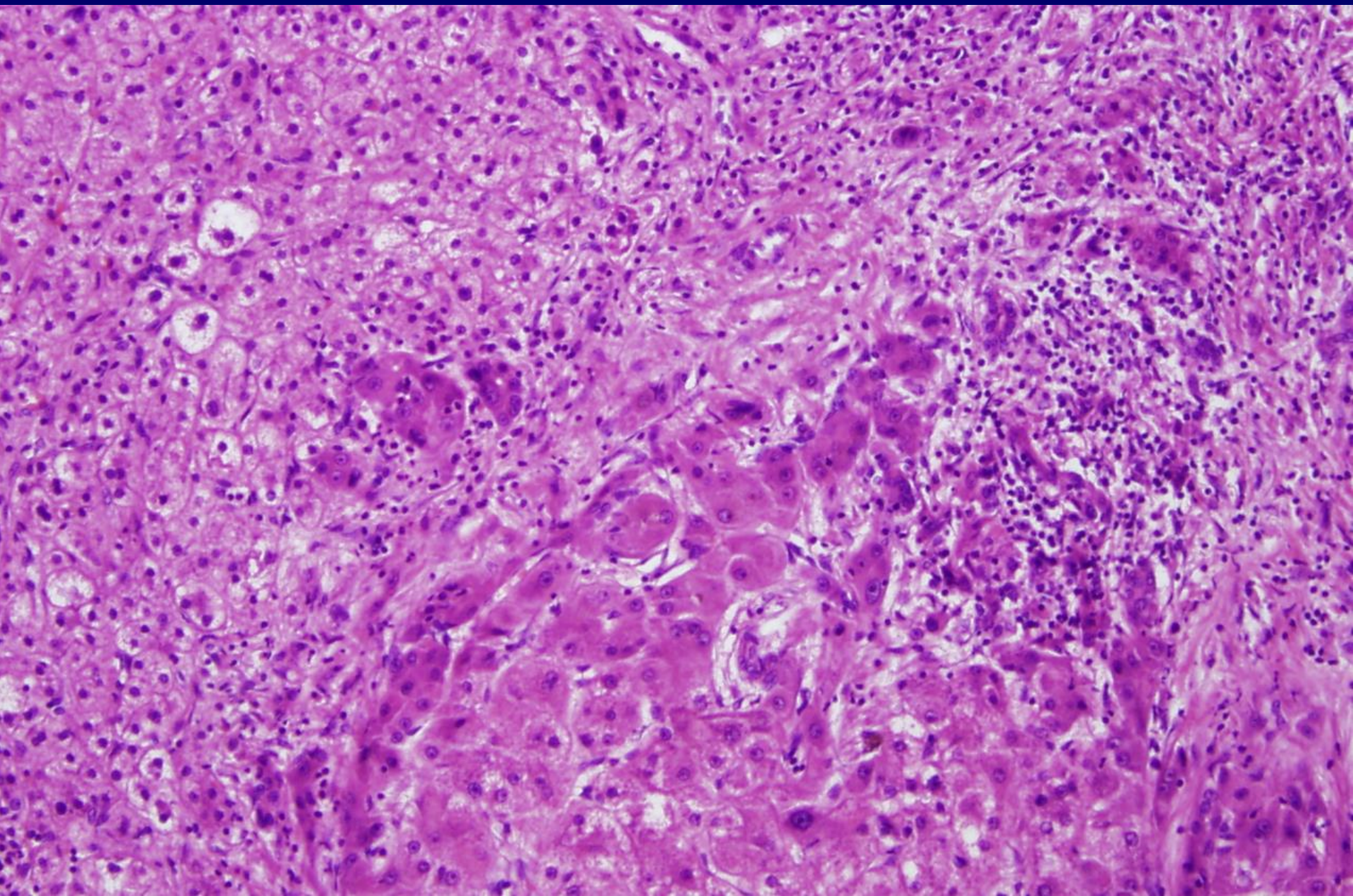

Combined immunostaining

HSP70, GS and GPC-3

Tamasso, Hepatol 07	All negative	Any one +	Any two +	All positive
HGDN	72%	28%	0	0
HCC	9%	91%	72%	44%
Tamasso, Hepatol 09	**All negative**	**Any one +**	**Any two +**	**All positive**
HGDN	78%	22%	0	0
HCC	8%	90%	50%	20%

Malignant spindle cell liver cell tumors	
Primary sarcoma	Angiosarcoma Other sarcomas
Metastatic sarcoma	GIST Other sarcomas
Other tumors	Metastatic melanoma Hepatic angiomyolipoma

LIVE
11:39 am PT

bama

HCC	Adenocarcinoma
Arginase-1 GPC-3 Hep Par 1	Glands Mucin CK19 CDX-2 CK20

Diagnosis

Metastatic hepatoid adenocarcinoma from the colon

Abundant fibrous stroma

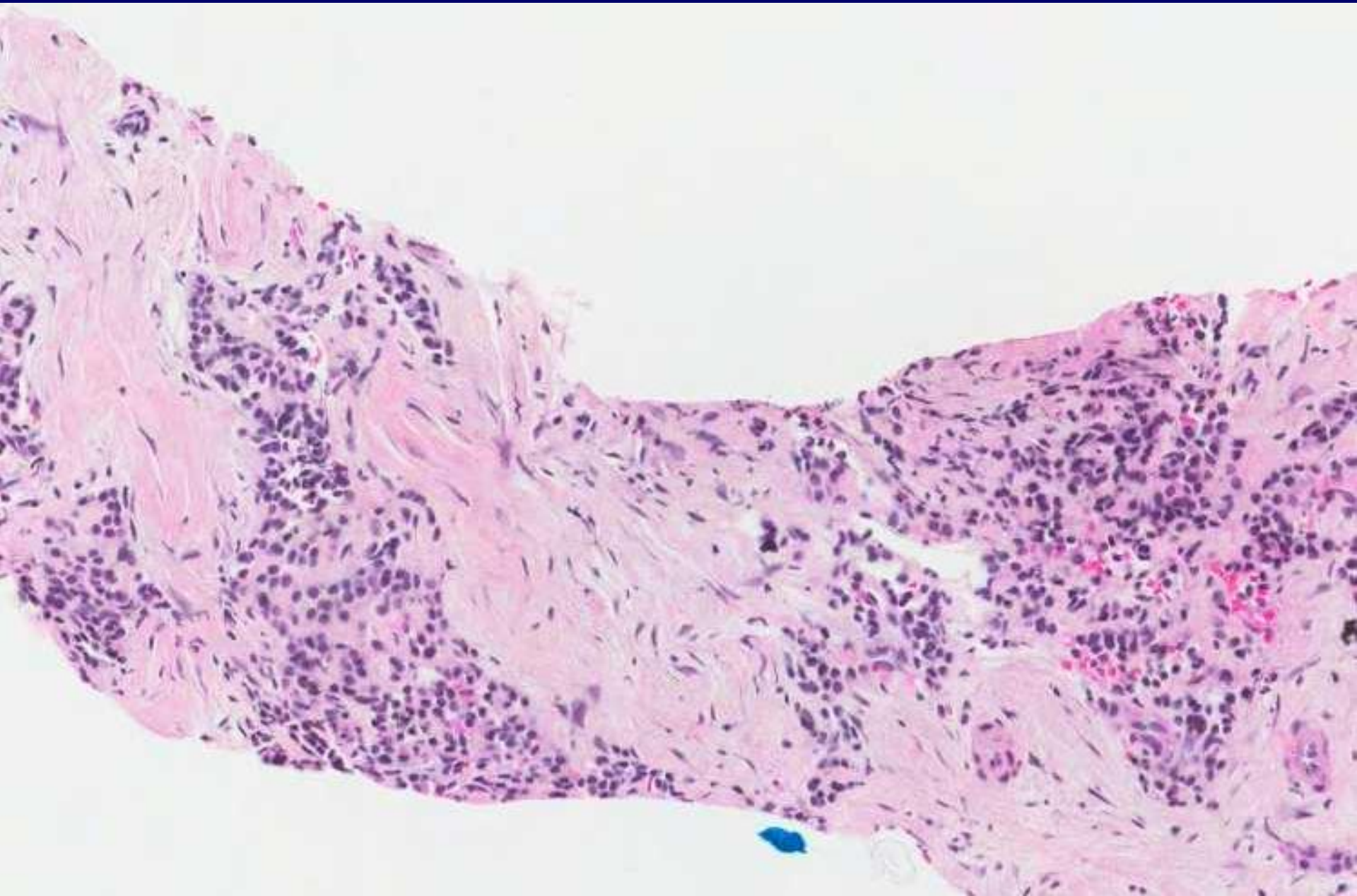

Vague pseudoacinar pattern

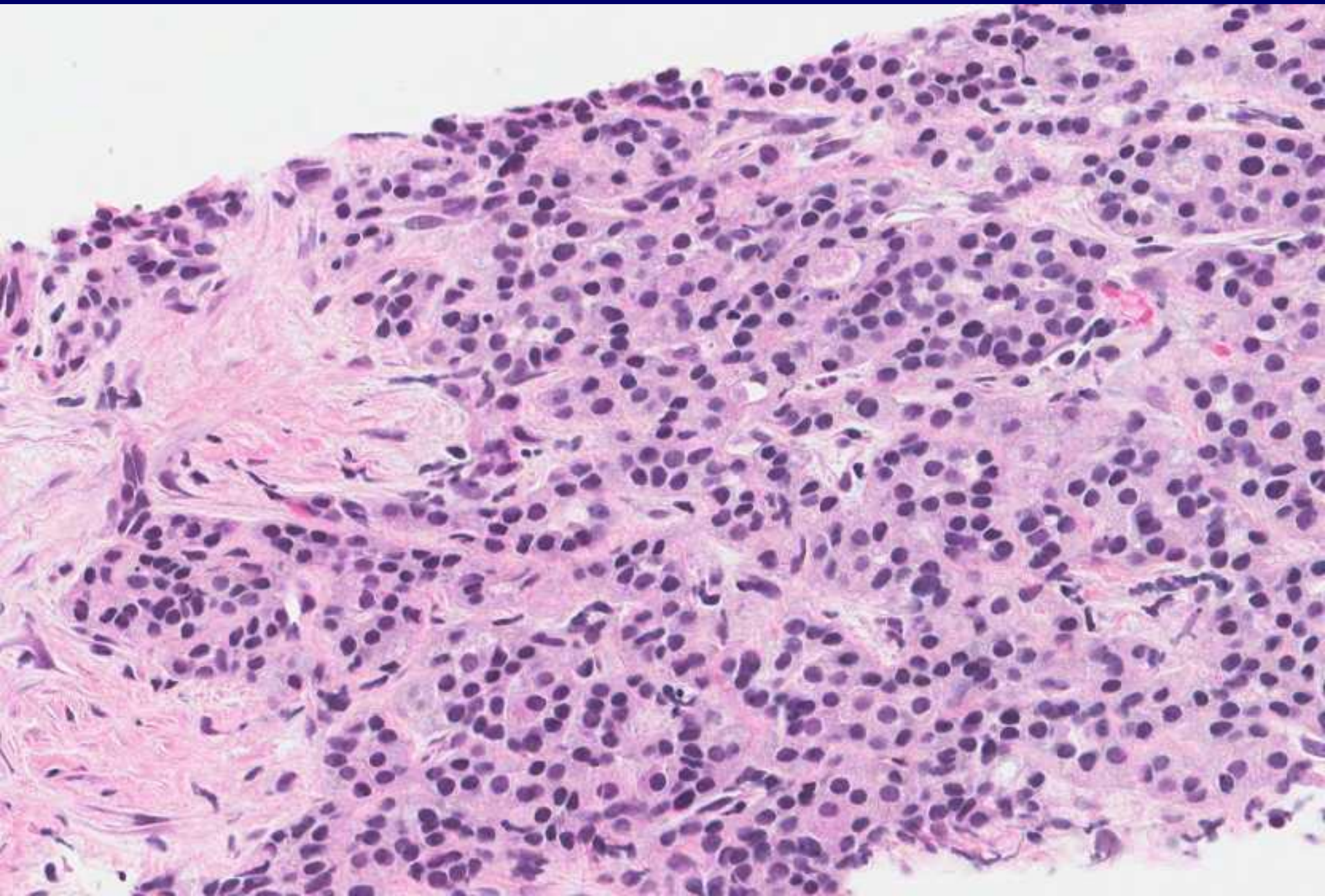

Synaptophysin: patchy staining

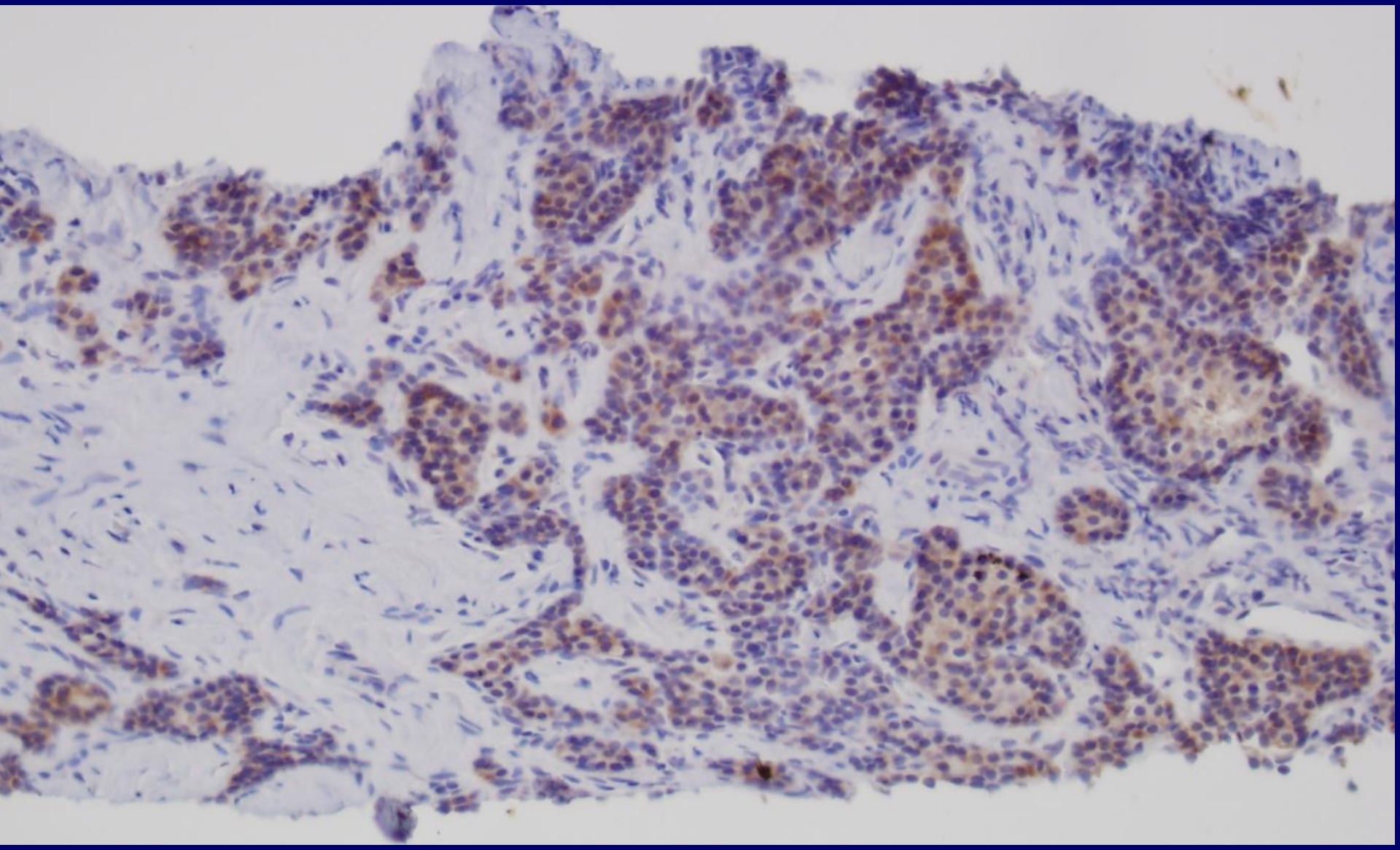

Biopsy diagnosis

Immunostain	Result
Hep Par 1, pCEA	Negative
MOC31	Positive
Synaptophysin, CD56	Patchy positive
Chromogranin	Negative

Liver, core needle biopsy:
Neuroendocrine tumor, grade 1

Resection

- 7 cm slightly firm pale red to gray-white mass
- Non-neoplastic liver: normal

Resection

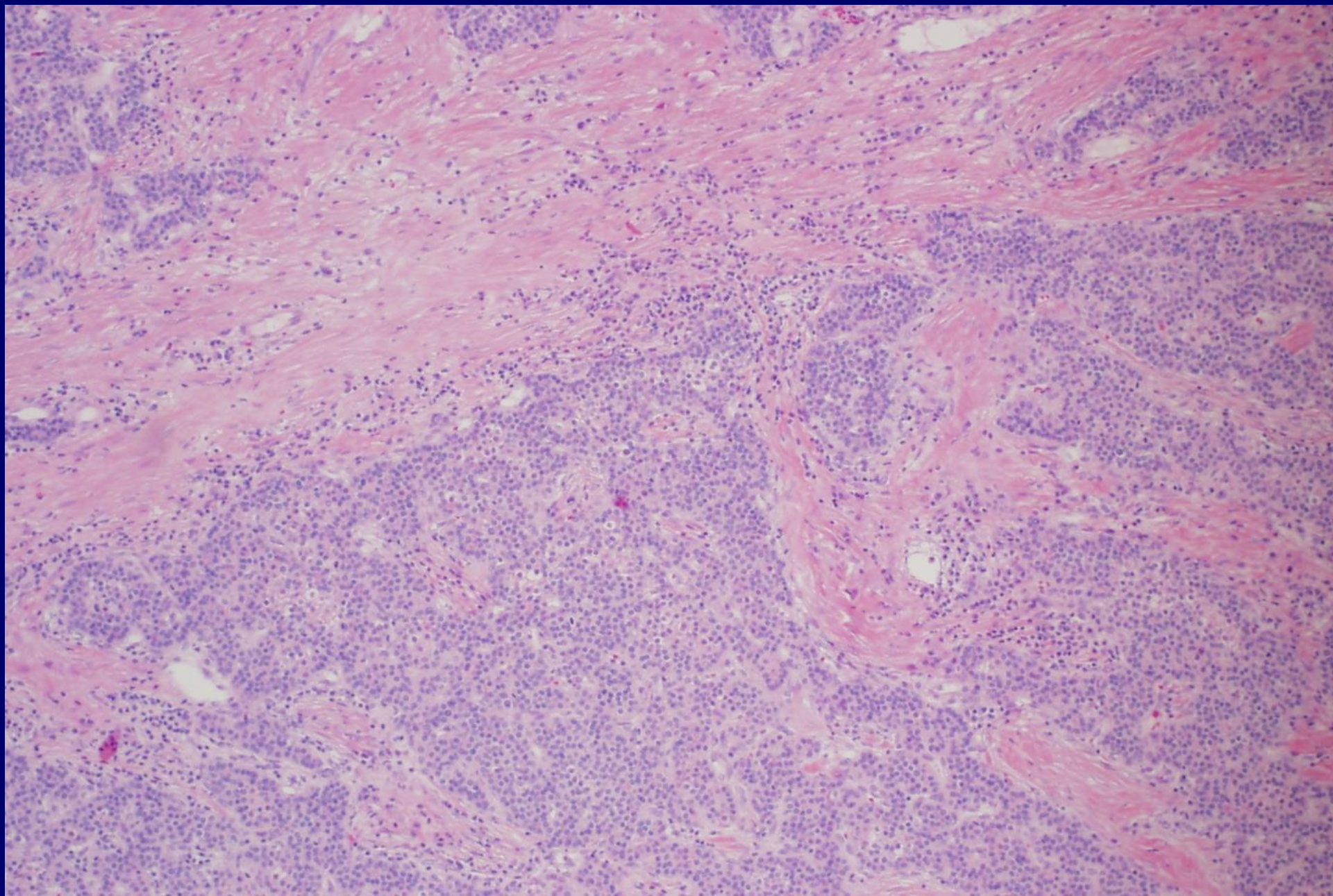

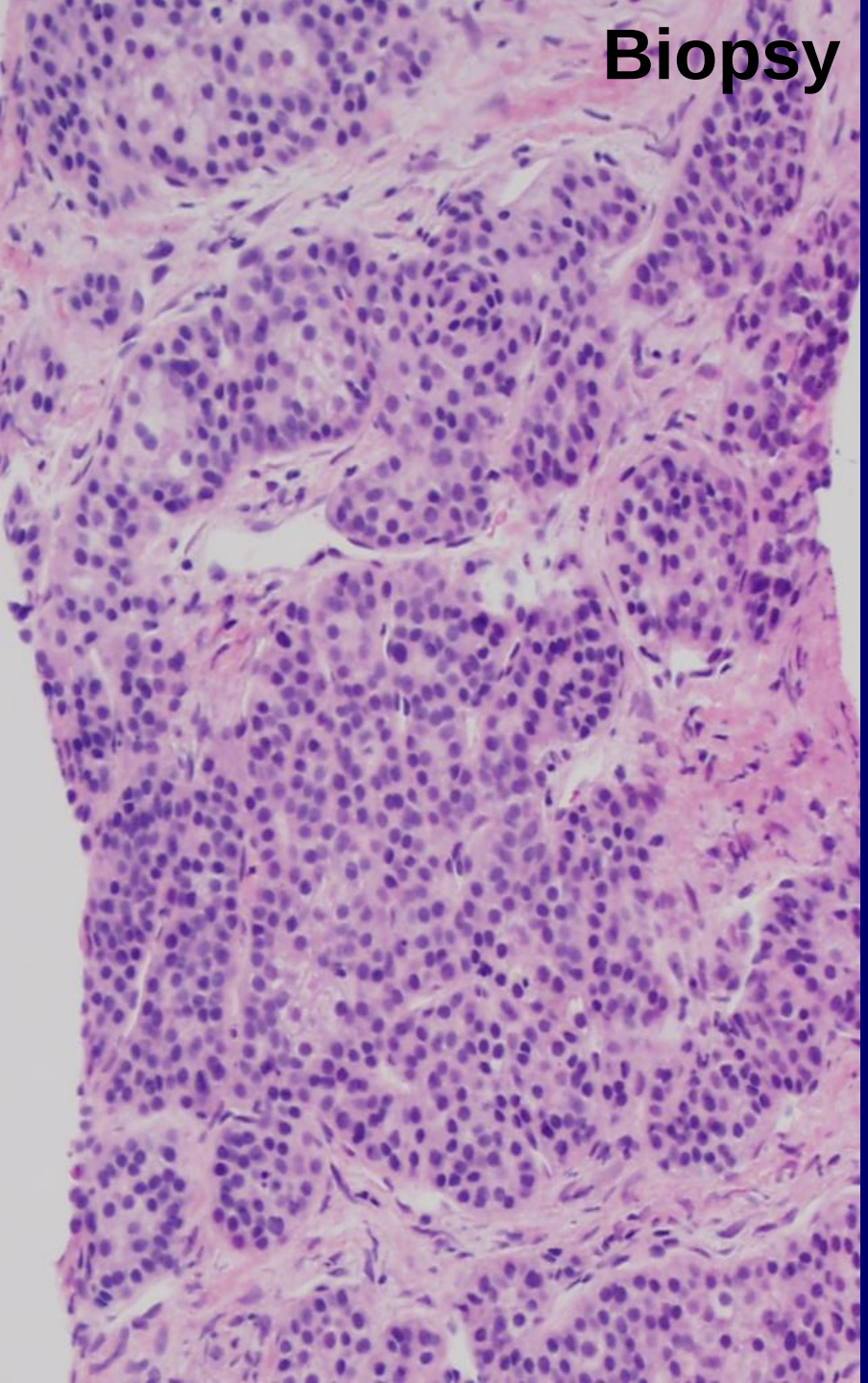
Biopsy

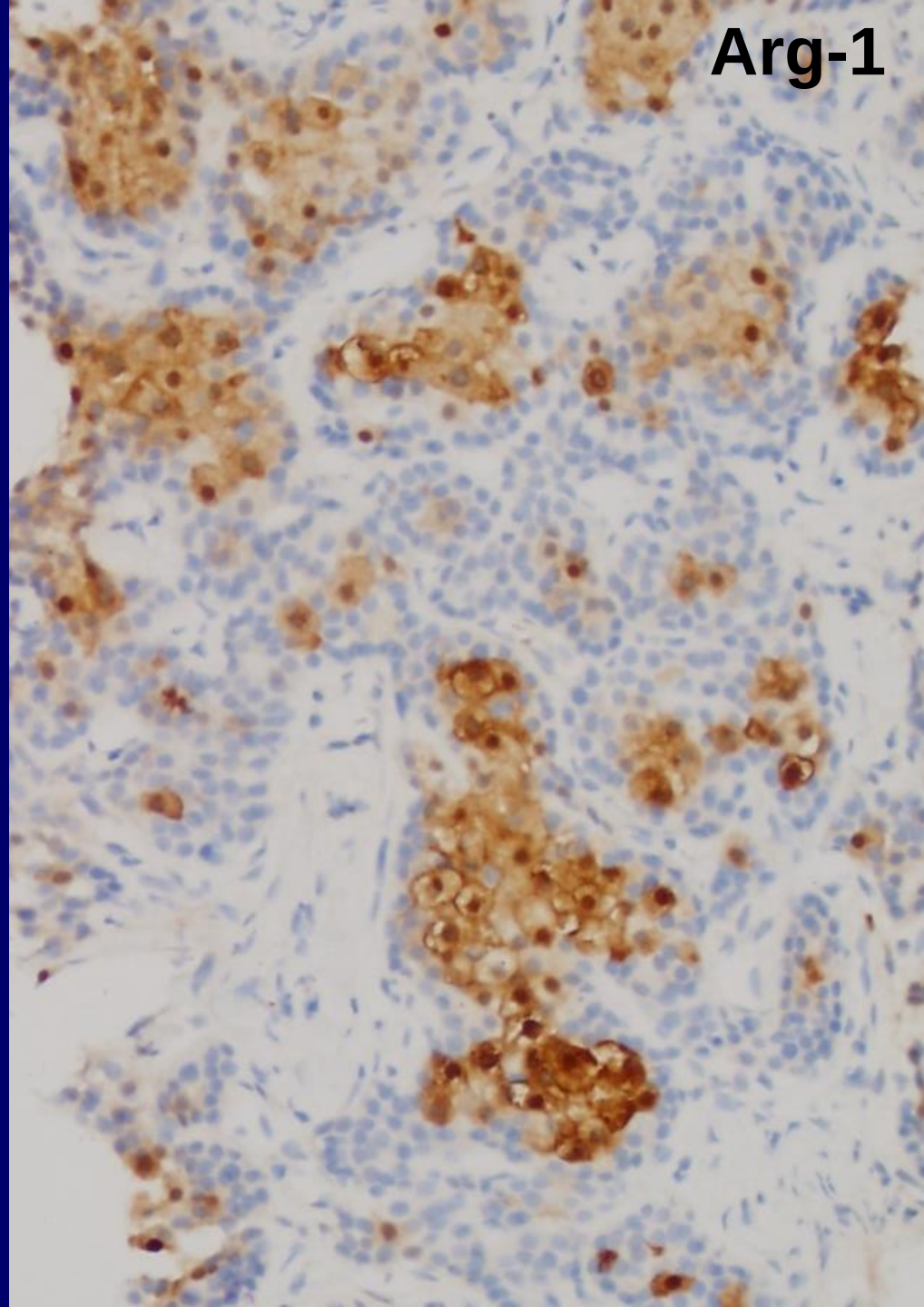
Arg-1

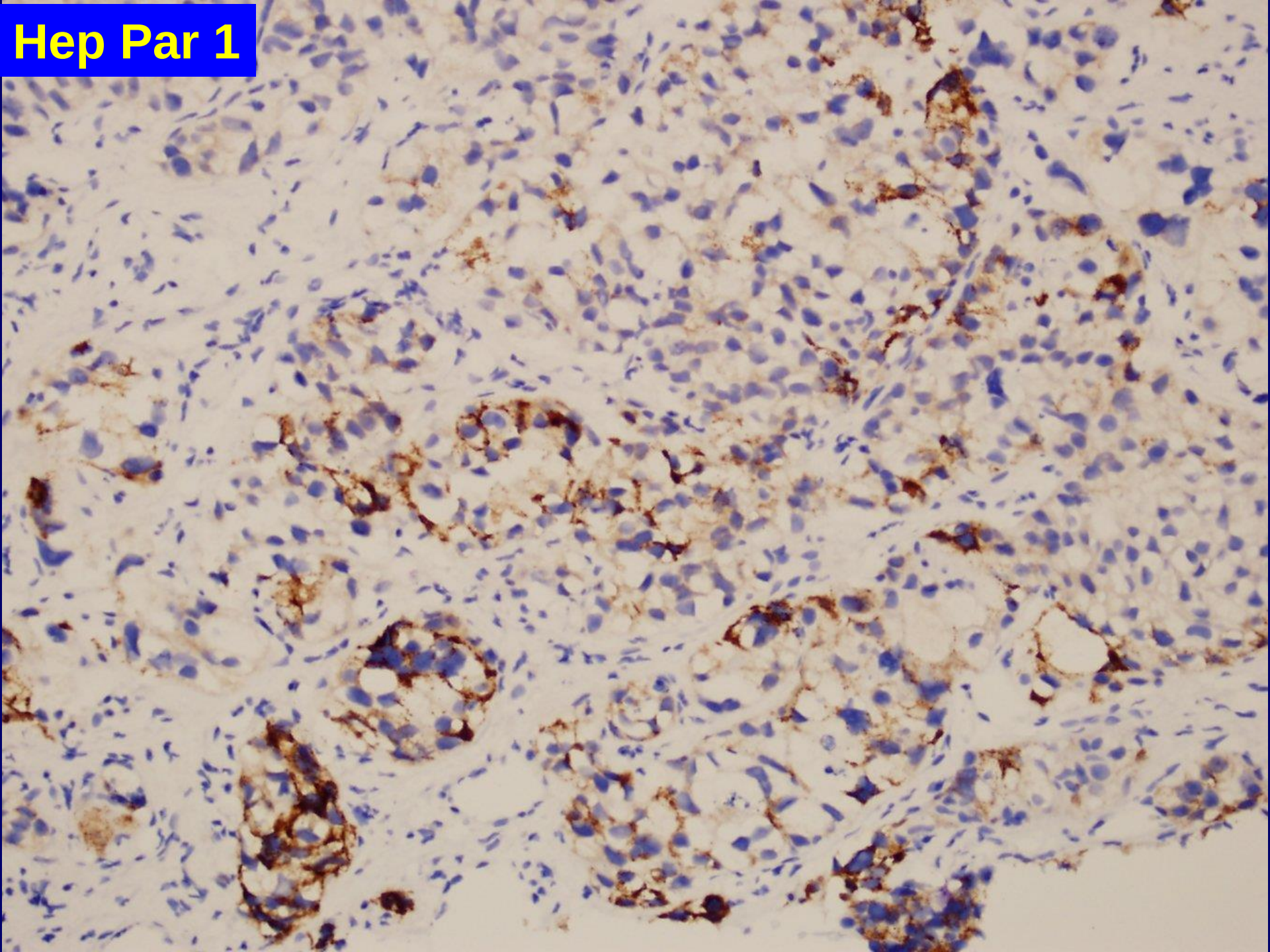
Hep Par 1

HCC	Adenocarcinoma
Arginase-1 GPC-3 Hep Par 1	Glands Mucin CK19