

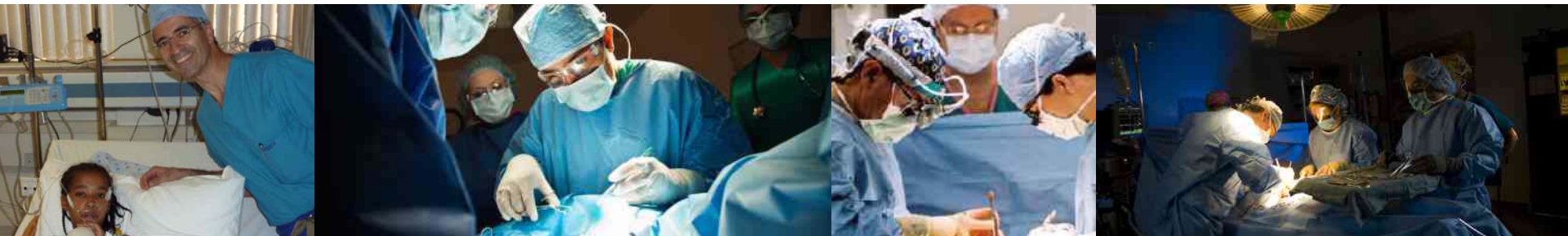

THE UNIVERSITY  
OF ARIZONA®

# Updates in Margin Status and Lymph Node Dissection

Leigh Neumayer, MD, MS, FACS

Professor and Chair  
University of Arizona



# Disclosures

- Co-patent holder for highly focused ultrasound device to detect cancer in margins
- Co-owner of Meet Virginia, LLC, a company formed to distribute (mostly for free) a book to patients about breast cancer and breast reconstruction
- Volunteer positions in many organizations



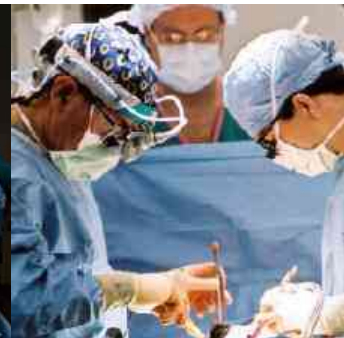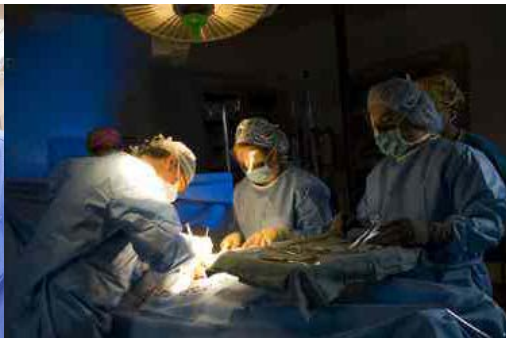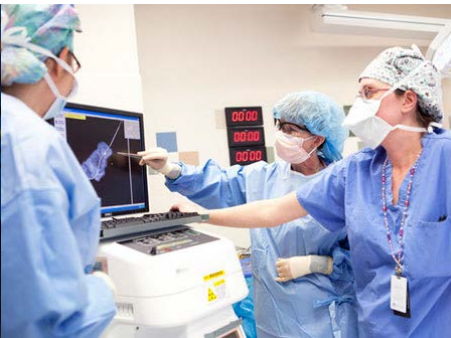# Objectives

- Understand recent guidelines and recommendations for margin clearance
- Understand current indications and contraindications for sentinel lymph node biopsy in the management of breast cancer



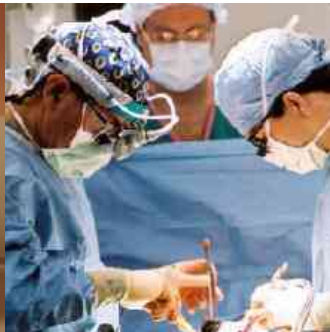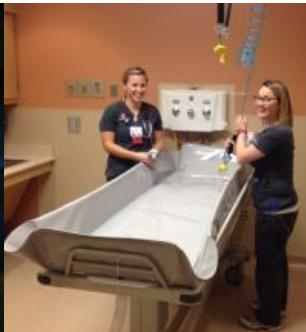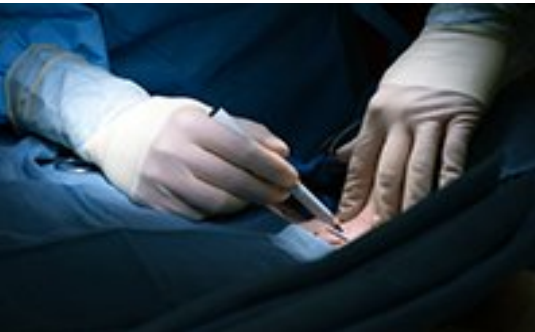# Question #1

- A 70 year old woman is diagnosed with a 1 centimeter invasive ductal carcinoma found on routine screening mammogram. She decides to undergo breast conservation with partial mastectomy. An “adequate” margin on the partial mastectomy specimen is
  - No tumor on ink
  - 1 millimeter
  - 2 millimeters
  - 5 millimeters
  - 1 centimeter



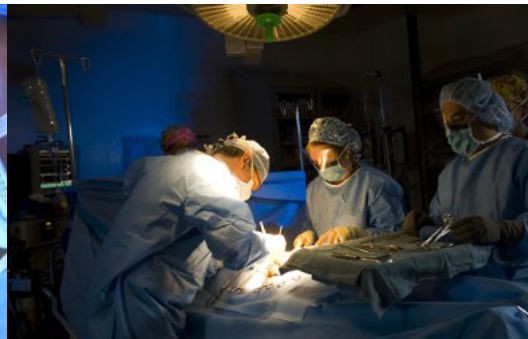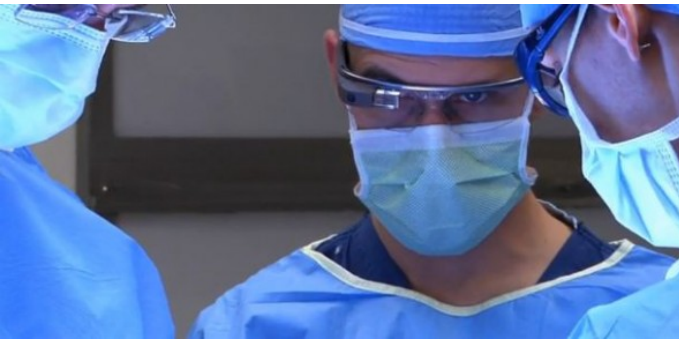# Question #2

- A 50 year old woman has high grade ductal carcinoma in situ found by core needle biopsy of microcalcifications. If she undergoes partial mastectomy as her surgical treatment, an “adequate” margin on the partial mastectomy specimen is
  - No tumor on ink
  - 1 millimeter
  - 2 millimeters
  - 5 millimeters
  - 1 centimeter



# Question #3

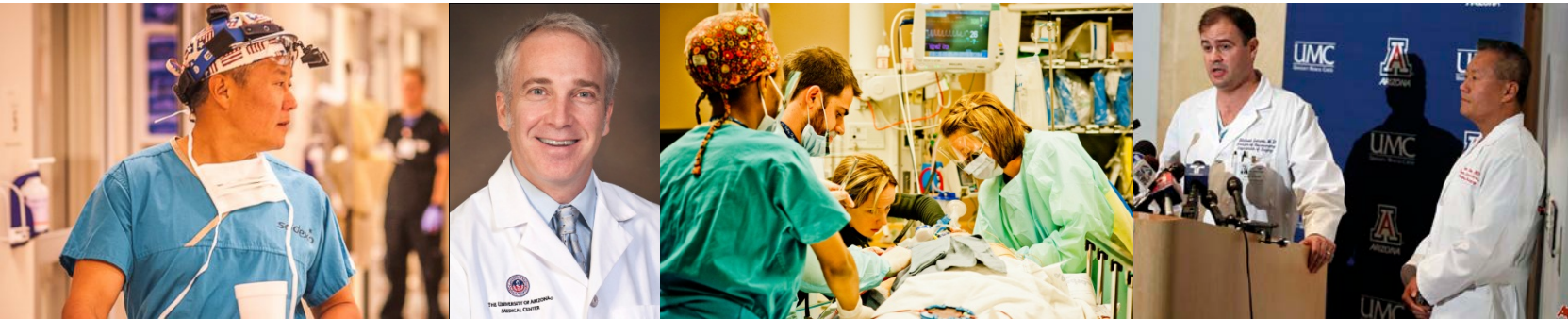- A 55 year old woman undergoes partial mastectomy for an area of atypical hyperplasia found on core needle biopsy of microcalcifications. Her pathology reveals atypical ductal hyperplasia and classic lobular carcinoma in situ with LCIS at the superior and medial margins of the specimen. This patient should have
  - No further surgical therapy of this area
  - Re-excision of the superior and medial margins
  - Repeat partial mastectomy re-excising all margins
  - Simple mastectomy
  - Modified radical mastectomy



# Margins: the Holy Grail

- Multiple randomized trials showing breast conserving therapy = mastectomy for treatment of stage I and II breast cancer
- Of these trials, most required only “grossly free” margins
  - One (NSABP B06) required microscopically clear
  - No tumor on ink

Ann Surg Onc 2014 21:704-716



# Margins: the Holy Grail

- Until last year, no consensus on what constitutes an “optimal” margin
- 1 in 4 women subjected to re-excision
- Large variation in practice amongst teams
- Soc Surg Onc and Am Soc Rad Onc (SSO/ASTRO) convened panel in 2013





# SSO/ASTRO Margins Panel

- What margin width minimizes risk of ipsilateral breast tumor recurrence?
- Are there specific circumstances that might impact the recommendation?
  - Patient characteristics
  - Tumor characteristics

Ann Surg Onc 2014 21:704-716



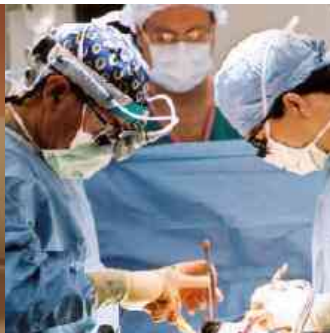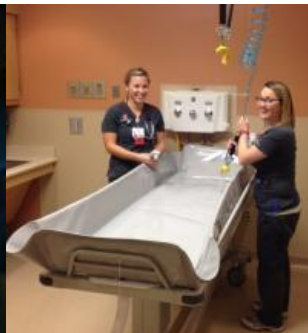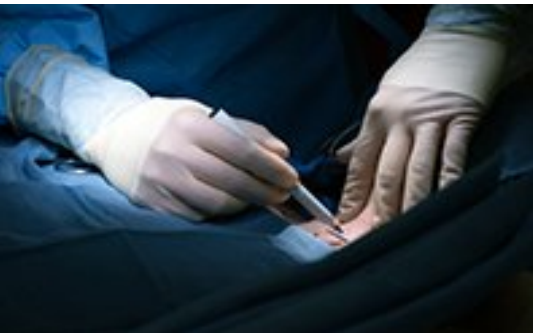# What is the increase risk of IBTR with positive margin?

- Positive margins (ink on invasive cancer or DCIS) are associated with at least 2 fold increase in IBTR
- Increase not mitigated by delivery of radiation boost, systemic therapy or favorable biology
- So CLEAR any positive margin



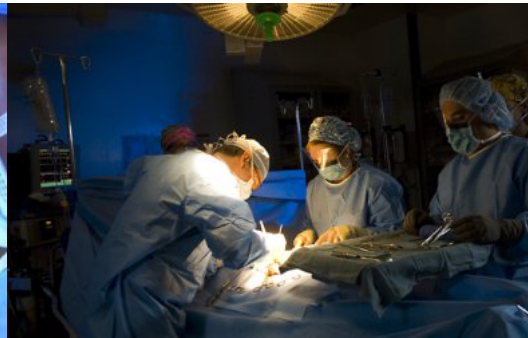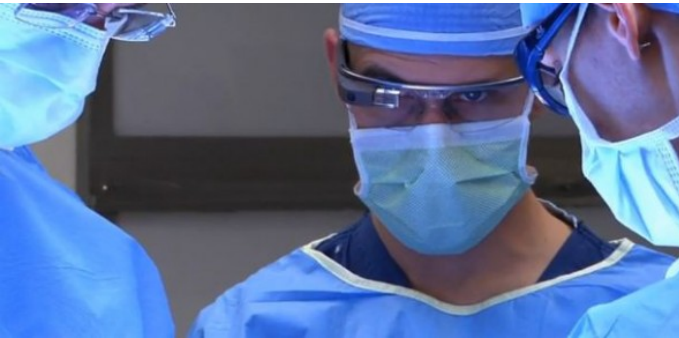# Do increasing margin widths decrease IBTR?

- Negative margins (no ink on tumor) optimize IBTR. Wider margins do NOT significantly lower risk
- Routine practice to obtain wider margin widths is NOT indicated



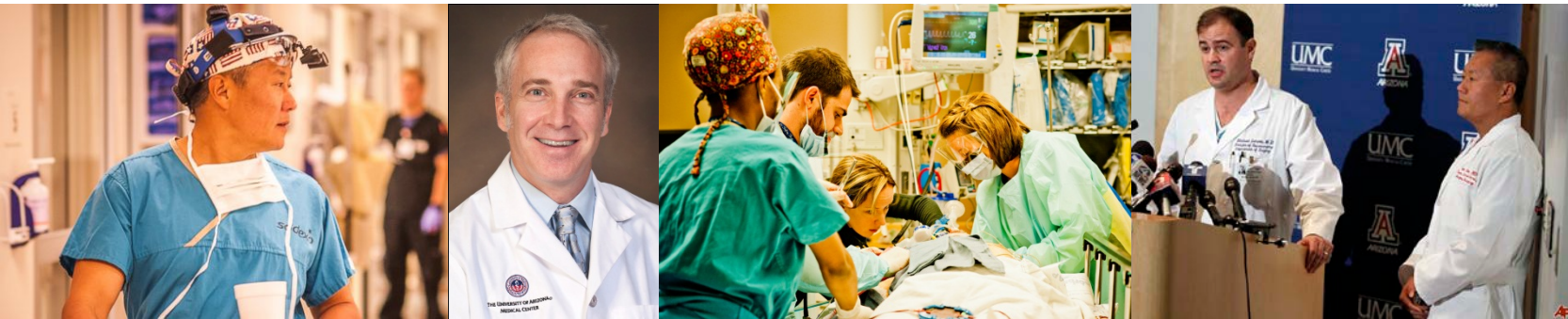# What about unfavorable biology?

- Multiple retrospective trials show no impact of wider margins on IBTR
- Not indicated to re-excise wider than no ink on tumor



# How about type of whole breast radiation?

- Choice of delivery (fractionation, boost dose) should NOT be dependent on margin width



# What about Lobular?

- Depends
  - Invasive lobular no tumor on ink
  - Classic LCIS at the margin is NOT indication for clearance/re-excision
  - Pleomorphic LCIS- significance unclear, most treat as DCIS (no ink on tumor)



# How about young patients?

- Young patients theoretically have longer time to recur
- Secondary data analysis from prospective randomized trials show young age is associated with increased IBTR however no evidence that increased margins impacts this



# What about EIC in the specimen

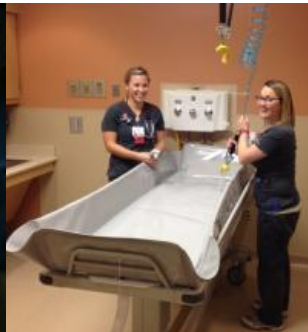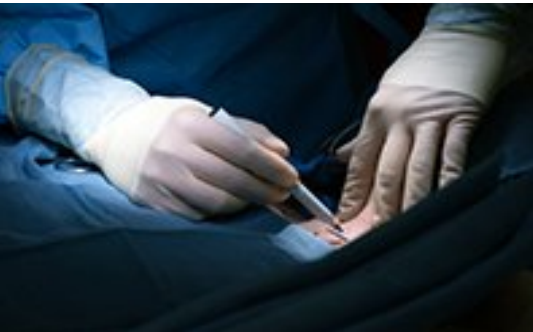- No evidence that EIC increases IBTR
- Meticulous study of mastectomy specimens
  - Demonstrated unicentric T1-2 tumors are associated with subclinical foci of invasive cancer and DCIS up to 4 cm away from index lesion





# Margins: the Holy Grail

- Margin assessment difficult
  - Flattening when removed due to loss of support
  - Compression for specimen mammography
  - Ink tracks into deeper portions
  - No standard method



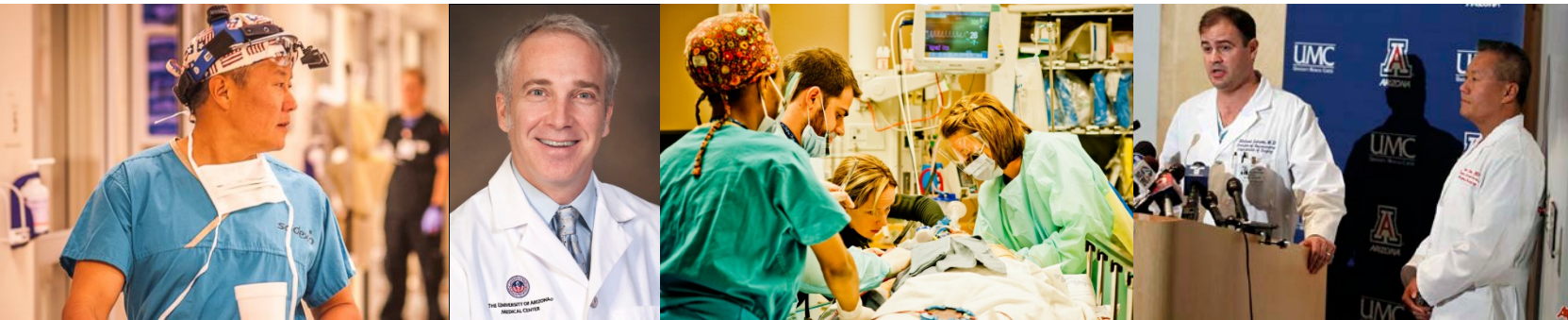# Final words on margins

- No ink on tumor
  - Invasive ductal AND lobular
  - DCIS
- Treatment of the breast cancer patient is a team sport
  - Communication amongst team and patient
  - Use evidence when available to guide practice



# Question #4

- Which of the following is a contraindication to sentinel lymph node biopsy?
  - Clinically negative axilla
  - Prior breast augmentation
  - Histologically positive axillary lymph node
  - Planned mastectomy
  - Pregnancy



# Question #5

- Lymphadenectomy in patients with breast cancer
  - Improves survival
  - Improves local recurrence rates
  - Replaces the need for chemotherapy
  - Is contraindicated
  - Provides staging information



# What have we known forever?

- Axillary lymphadenectomy has no impact on survival
- Axillary lymphadenectomy has little impact on regional (axillary) recurrence
- Surgical excision and radiation are equally effective in regional control



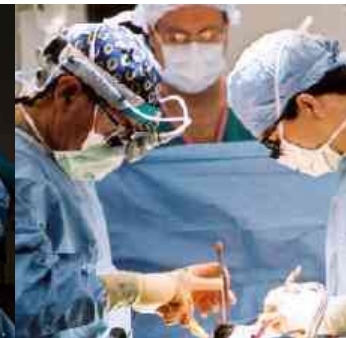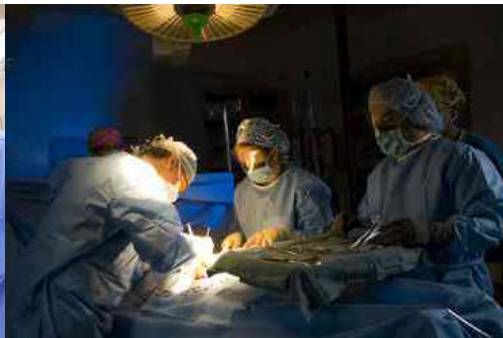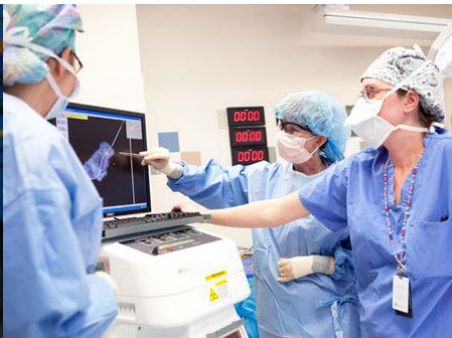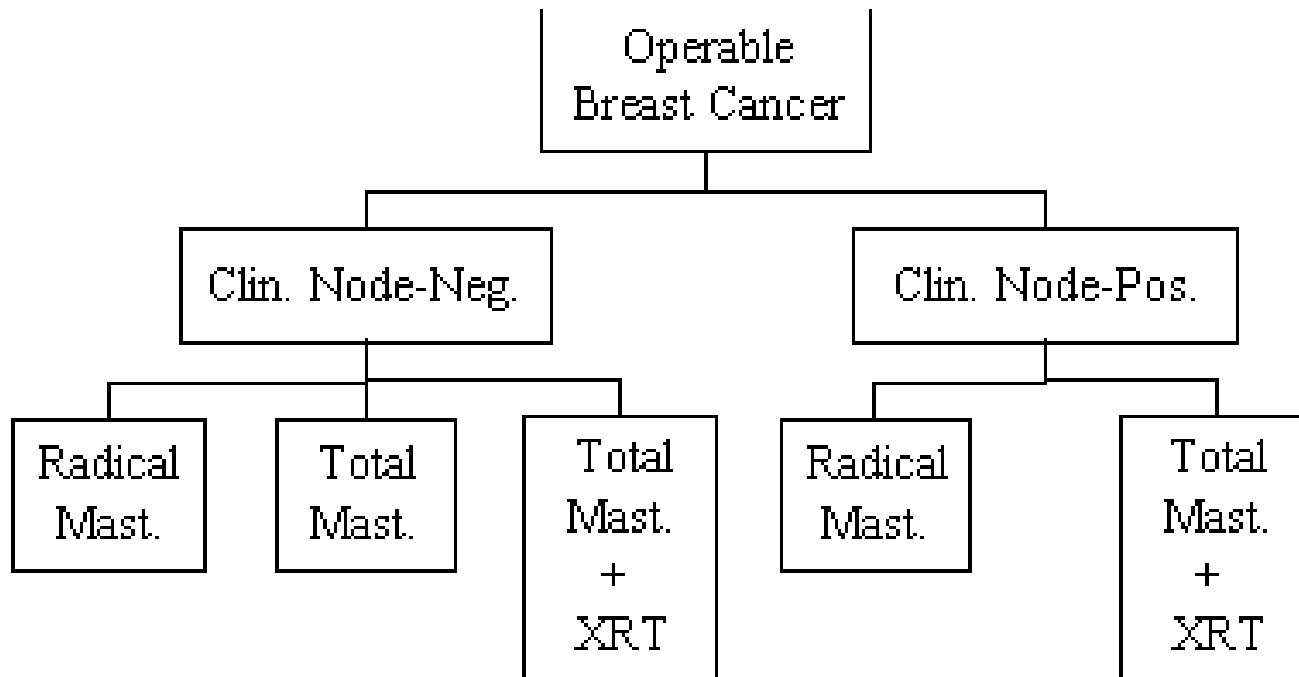
# Lymph node management

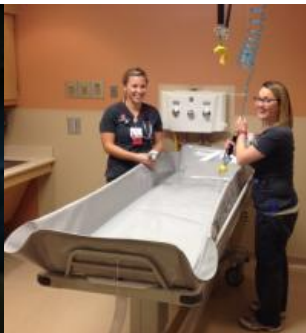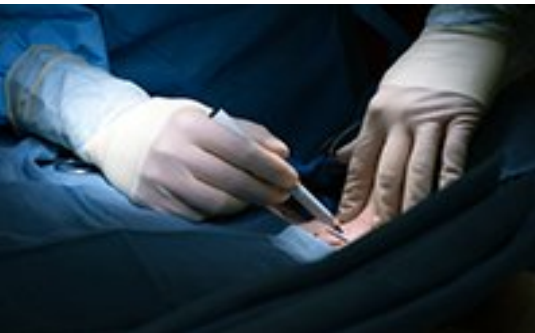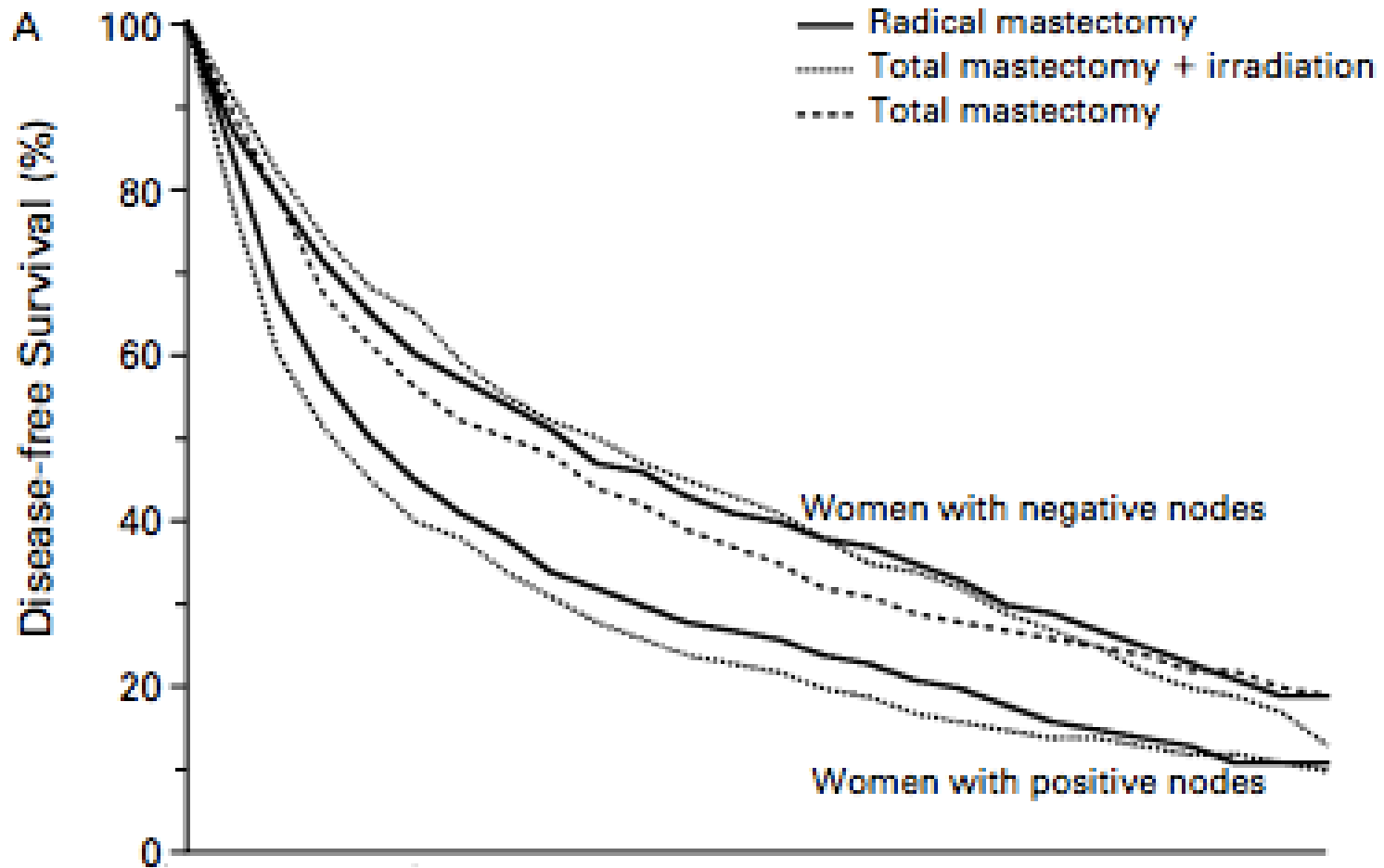
- NSABP B04
  - Enrollment from 1971 to 1974
  - 1765 women randomized
    - Based on clinically positive or negative nodes
  - 25 year follow up data published in 2002

NEJM 2002 347:567-75

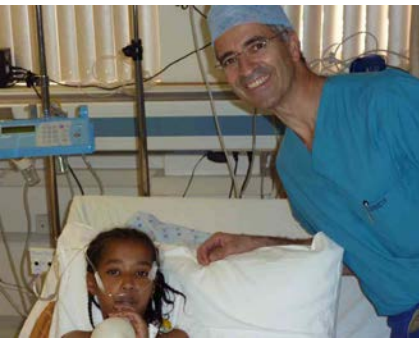
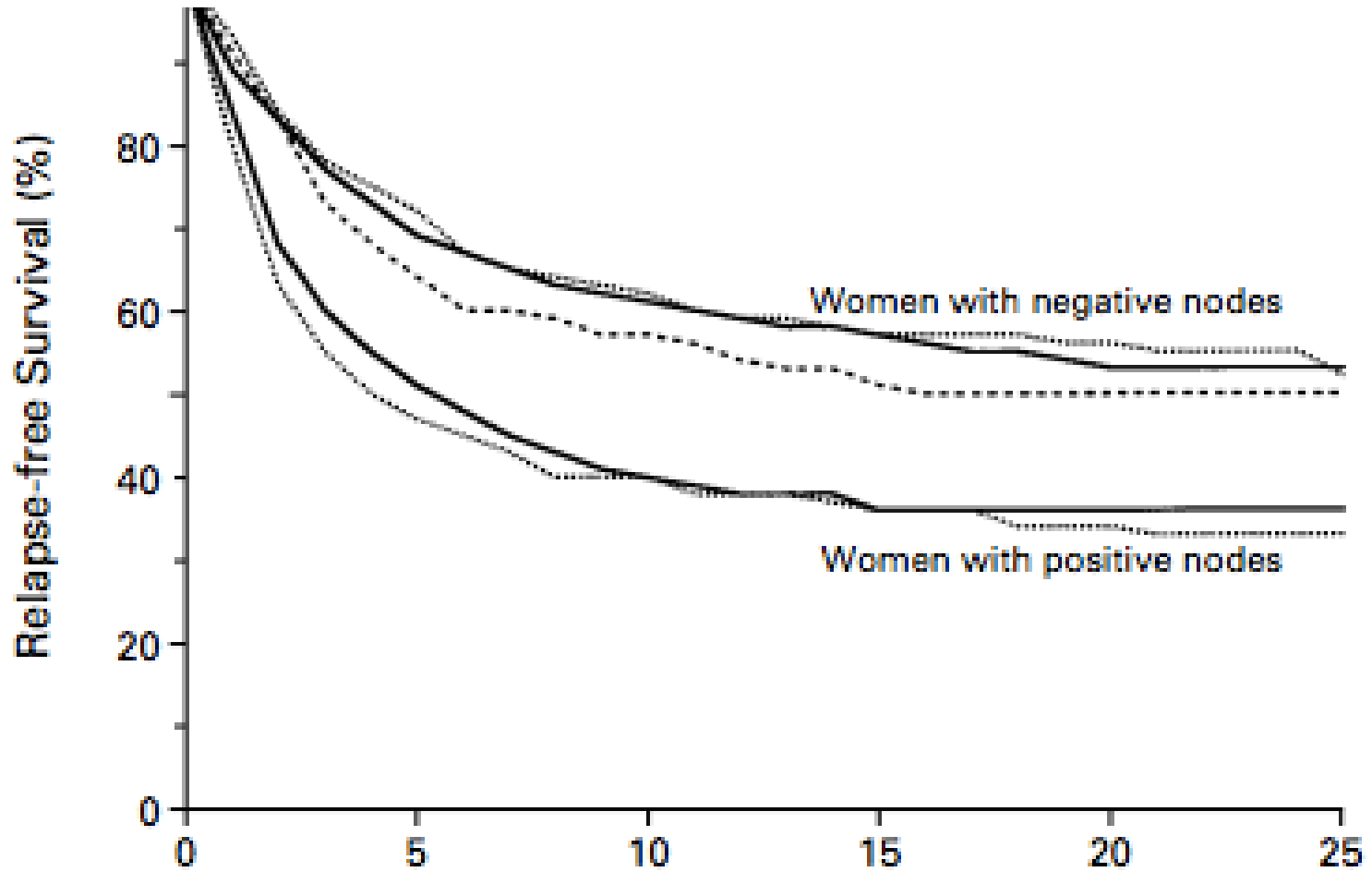


# NSABP B04









# NSABP B04 Conclusions

- No advantage to radical mastectomy
- No significant survival advantage to removing occult positive nodes
- Only about half of women with “untreated” nodes went on to recur regionally



# Indications

- Appropriate initial intervention with clinically negative nodes (ASCO Guideline)\*
- High grade DCIS requiring mastectomy (extensive or multicentric)
- Controversies
  - DCIS w/o mastectomy
  - After neoadjuvant
  - Clinically positive axilla
  - After prior breast augmentation

\*J Clin Oncol 2005;23:7703-20



# How many is enough?

- When does a SLN become an axillary dissection?
- Stop when nodes have  $\leq 10\%$  count of highest ex-vivo node count
- Removal of just the most radioactive node not accurate
- 97-99% accuracy with three nodes.

Am J Surg 2004;187:639-42, Breast J 2004;10:186-9



# Special considerations: DCIS

- Data to support SLN with extensive, multicentric (usually requiring mastectomy) high grade DCIS
- Some recommend SLN procedure prior to immediate reconstruction

Breast J 2005;11:338-43, Am J Surg 2005;190:563-6, Am J Surg 2005;190:595-7, Plast Reconstr Surg 2005;116:1278-86



# Special considerations: Neoadjuvant chemotherapy

- After neoadjuvant
  - SLN identified in 90% (range 72-100)
  - Sensitivity 88% (CI 85-90%)
- Before neoadjuvant in clinically negative axilla
  - 100% accuracy

Br J Surg 2005;Dec 2 epub, Am J Surg 2005;190:517-20



# Special considerations: Prior breast augmentation

- Seventy-six patients with augmentation prior to breast cancer diagnosis
- Average interval 14 years
- 100% success rate with SLN identification

Plast Reconstr Surg 2004;114:1737-42



# ASCO Guidelines SLN biopsy

March 2014

- Three recommendations based on RCT
  - Women without SLN metastases should NOT undergo ALND
  - Most women with 1-2 positive nodes undergoing BCT (with XRT) should NOT undergo ALND
  - Women with SLN mets undergoing mastectomy may be offered ALND

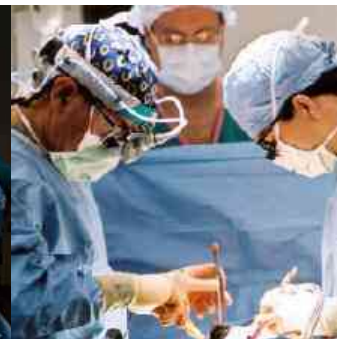
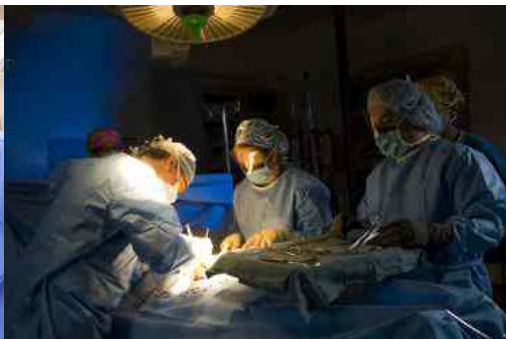
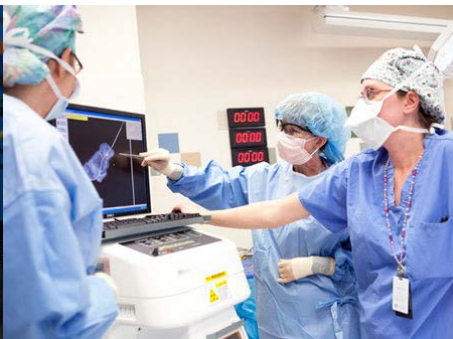

# ASCO Guidelines SLN biopsy

March 2014

- Updated two recommendations based on cohort studies or informal consensus
  - Widen indications for sentinel lymph node biopsy
    - Multicentric, DCIS undergoing mastectomy, prior breast surgery, neoadjuvant chemotherapy
  - Large tumors (T3-4), inflammatory breast cancer, DCIS undergoing lumpectomy, pregnant\* should NOT have SLN biopsy



# SLN biopsy in pregnancy

- Harm to fetus?
- Series of 81 patients, 25 underwent sln bx
- 100% success (methylene blue dye and Tc 99)
- No difference from alnd group in recurrence, survival or births

Ann Surg Onc 2014 21(8):2506-11



# Neoadjuvant chemotherapy/SLN

- ACoSOG Z1071
  - Histologic cN1 disease followed by neoadjuvant chemotherapy, objective determine FNR
  - SLN biopsy followed by ALND
  - 756 women enrolled 663 evaluable patients
  - FNR 12.6%
  - More accurate if radiolabeled and blue dye used

JAMA 2013 310(14):1455-61



# Neoadjuvant chemotherapy/SLN

- SENTINA trial
  - Clinically node negative underwent sln bx prior to chemotherapy
    - If positive, second sln bx after chemotherapy
  - Clinically node positive underwent neoadj chemo then sln bx followed by aInD



# Neoadjuvant chemotherapy/SLN

- SENTINA trial
  - Women with second sln procedure had low sln detection (60%) and high FNR (51%)
  - Women who converted from clinically node positive to clinically node negative with chemo, detection rate 80%, FNR 14%
  - FNR in second group decreased with increased # sln

Lancet Onc 2013 14(7):609-18



# Lymph node management

- The act of removing lymph nodes provides mostly prognostic information
- Even in our earliest trials (in fact even in Halsted's own data), we have seen no treatment or survival benefit to lymphadenectomy



# Lymph node management

- Indications and application of sentinel lymph node biopsy have expanded
- In clinically (and radiographically) negative axilla, sentinel lymph node almost always indicated
- In clinically positive axilla-biopsy it!



# Lymph node management

- In patients undergoing BCT, can omit ALND even with 1 or 2 positive sentinel nodes
- In patients undergoing neoadjuvant chemotherapy, the decision to forgo ALND should be made by the team





# Final thoughts

- Treatment of the breast cancer patient is a team sport
  - Communication amongst team and patient
  - Use evidence when available to guide practice
  - Every time we have studied less vs more, less is at least equivalent to more
  - It takes a village to keep up!





THE UNIVERSITY  
OF ARIZONA®

# Questions?

Thanks and enjoy the snow!

